



PATIENT

Nooka Steer

SPECIES

Canine

BREED

Husky X

SEX

FS

AGE

6

WEIGHT

25.3 kg

INTERPRETED BY

R. McKenzie Daniel,
DVM, DABVP
(Canine and Feline)

IMAGING PERFORMED BY

Dr. Belan

HOSPITAL NAME

Bowmont Animal
Hospital

REFERRING VET

Dr. Asemadahun

INVOICE

16337

DATE

3/10/23

PRESENTING CLINICAL SIGNS

Lethargic anorexic for last 10 days painful mid abdomen
Abnormal PE/Chem/CBC/UA Results: Non diagnostic

ULTRASONOGRAPHIC EXAMINATION OF THE ABDOMEN

Urinary System

The urinary bladder, trigone, cystourethral junction, and visible pelvic urethra to a depth of 3.0 cm exhibited normal thickness and tone. Anechoic urine was present in the lumen with no uroliths or sediment. The ureteral papillae were normal. The ureters were not visible which is normal. No evidence of inflammatory or neoplastic changes was noted.

The area of the aortic trifurcation was free of pathology.

No evidence of pathology was noted in the area of the uterine remnant.

Normal size and margination were present in the kidneys. A normal 1:3 cortex / medulla ratio was maintained. The medulla and cortices were uniform in texture with some increased echogenicity and mild loss of corticomedullary symmetry and definition expected for the age of the patient. No evidence of pelvic dilation was present. The left kidney measured 5.6 cm in length. The right kidney measured 6.0 cm in length.

Adrenal Glands

The bilateral adrenal glands exhibited subjective normal position exhibiting homogeneous parenchyma with a possible borderline flattened shape. The left adrenal gland measured 0.47 cm width at the caudal pole and 0.4 cm width at the cranial pole. The right adrenal gland measured 0.38 cm width at the caudal pole.

Spleen

The spleen exhibited possible borderline to mild enlargement with possible mild folding. Symmetrical capsule contour was noted in the spleen with subtle parenchyma heterogeneity including intermittent, discrete, nondisruptive nodules. An example of a splenic nodule measured 0.78 cm in diameter. The nodules did not distort the splenic capsule.

Liver/ Gallbladder

The liver was subjectively normal in size, structure, and contour. The liver parenchyma was mildly nonuniform and hypoechoic to the spleen with a moderate coarse echotexture and subjective mild parenchymal remodeling. The hepatic and portal vasculature were normal in appearance without signs of congestion. The gallbladder was non-distended in size containing primarily anechoic content with mild, nonorganized gallbladder debris primarily in the caudal lumen and area of the gallbladder neck. No evidence of gallbladder or peripheral gallbladder inflammatory criteria was noted. The cystic and common bile ducts were normal.



PATIENT

Nooka Steer

SPECIES

Canine

BREED

Husky X

SEX

FS

AGE

6

WEIGHT

25.3 kg

INTERPRETED BY

R. McKenzie Daniel,
DVM, DABVP
(Canine and Feline)

IMAGING PERFORMED BY

Dr. Belan

HOSPITAL NAME

Bowmont Animal
Hospital

REFERRING VET

Dr. Asemadahun

INVOICE

16337

DATE

3/10/23

Gastrointestinal

The stomach presented intact wall layering with a normal wall layer ratio. The lumen of the stomach was empty with no signs of ileus, obstruction, or foreign material.

The small intestine presented intact wall layering with 1:3 muscularis/mucosa ratio. The lumen of the small intestine was empty with no signs of ileus, obstruction, or foreign material. Mild, nonspecific, hyperechoic duodenal mucosal speckling was noted. No obstructive pattern was visualized.

Normal visible colon wall layers were present with apparent formed feces in lumen.

Pancreas

The pancreas was normal in size and contour with isoechoic to heterogeneous parenchyma compared to adjacent omentum. No signs of active inflammation or neoplasia.

Free Abdomen

Regional midabdominal mild hyperechoic to nonuniform omentum was noted. Within the hyperechoic omentum, thinly walled cystic structures were present containing anechoic fluid, which may indicate omental cyst or cystic mesenteric lymph nodes were present. Definitive cystic mesenteric lymph node measured 1.8 cm x 0.6 cm. An example of an omental cystic lesion measured 3.5 cm in diameter. No evidence of peritoneal effusion was visualized.

ULTRASONOGRAPHIC FINDINGS

Primary Findings

- Heterogeneous discretely nodular spleen - hyperplasia, hematopoiesis, splenitis, atypical myelolipomas, infiltrative neoplasia, all potentials
- Intact gastrointestinal wall layering with mild nonspecific duodenal mucosal speckling
- Midabdominal mild hyperechoic to nonuniform omentum with omental cystic structures and intermittent cystic mesenteric lymphadenopathy - regional midabdominal staeitis, omental cysts with potential chronic mesenteric lymphatic hyperplasia, lymphadenitis, potential for emerging omental or lymphatic abscessation possible, neoplasia considered less likely
- Heterogeneous pancreas - patient / age variant, remodeling owing to previous inflammation, potential for low-grade / chronic pancreatitis, no overt pancreatic neoplastic criteria

Secondary Findings

- Age-related renal changes
- Mild gallbladder debris (non-mucocele)

INTERPRETATION OF THE FINDINGS & FURTHER RECOMMENDATIONS

Although nonspecific, the midabdominal hyperechoic omentum with associated omental cysts and cystic mesenteric lymph nodes may indicate residual to possible chronic omental and lymphatic inflammation possibly secondary to previous pancreatitis or possible inflammatory enteropathy.



PATIENT

Nooka Steer

Assuming normal clotting status, splenic and hyperechoic omentum FNA cytology, as well as an accessible cyst or cystic lymph node cytology +/- C/S, if evidence of inflammatory cells, for further clarification are warranted.

SPECIES

Canine

A GI panel to include PLI/TLI/Cobalamin/Folate could be considered for further clarification of the pancreas, as well as assessment of occult intestinal disease as a contributing factor to the anorexia. Empirically, as-needed gastrointestinal support and empirical therapy for low-grade pancreatitis with potential sonographic reassessment to assess for progressive omental, pancreatic, or intestinal inflammatory changes pending clinical response to therapy may prove beneficial.

BREED

Husky X

SEX

FS

AGE

6

WEIGHT

25.3 kg

INTERPRETED BY

R. McKenzie Daniel,
DVM, DABVP
(Canine and Feline)

IMAGING PERFORMED BY

Dr. Belan

HOSPITAL NAME

Bowmont Animal
Hospital

REFERRING VET

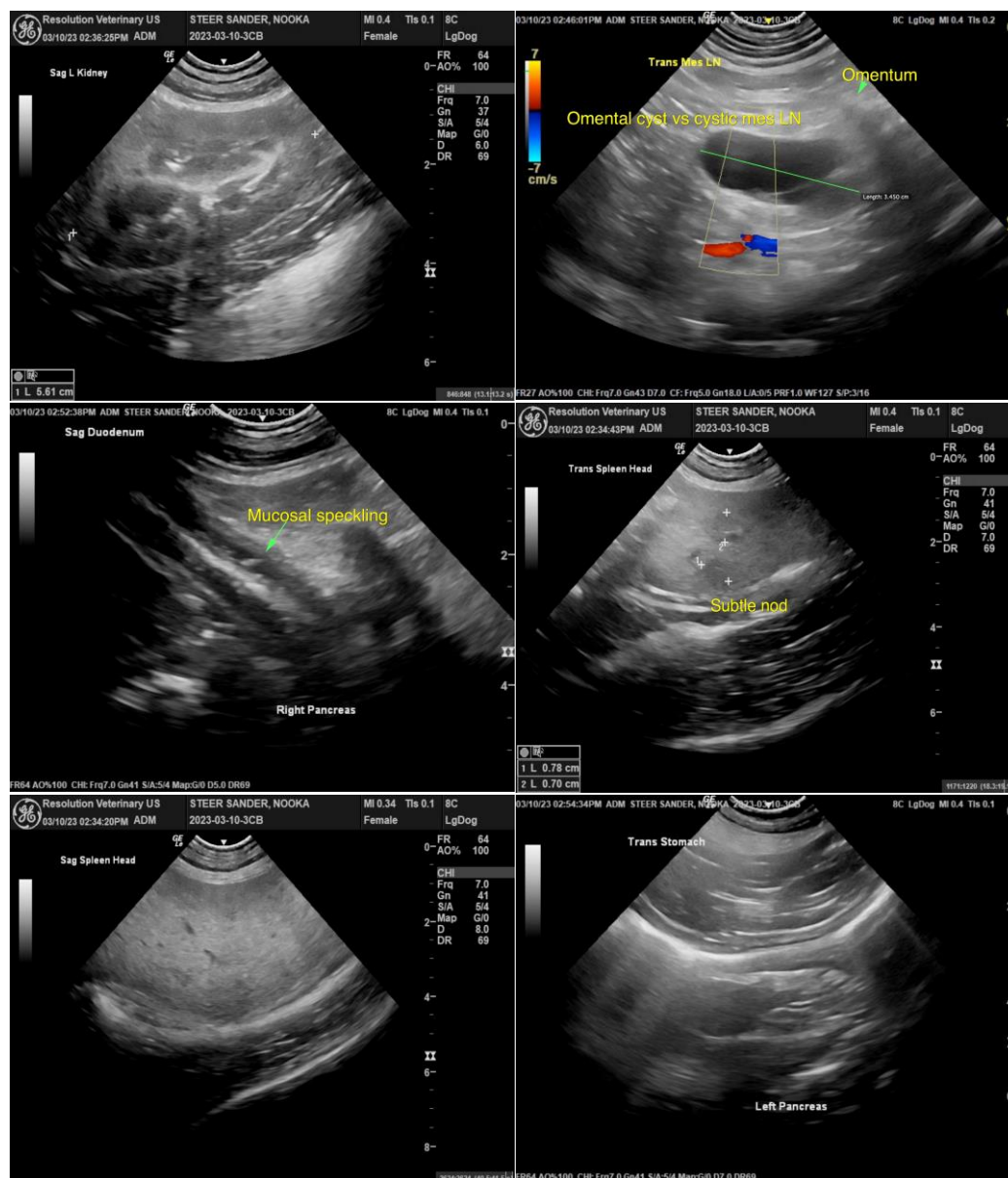
Dr. Asemadahun

INVOICE

16337

DATE

3/10/23





PATIENT

Nooka Steer

SPECIES

Canine

BREED

Husky X

SEX

FS

AGE

6

WEIGHT

25.3 kg

INTERPRETED BY

R. McKenzie Daniel,
DVM, DABVP
(Canine and Feline)

IMAGING PERFORMED BY

Dr. Belan

HOSPITAL NAME

Bowmont Animal
Hospital

REFERRING VET

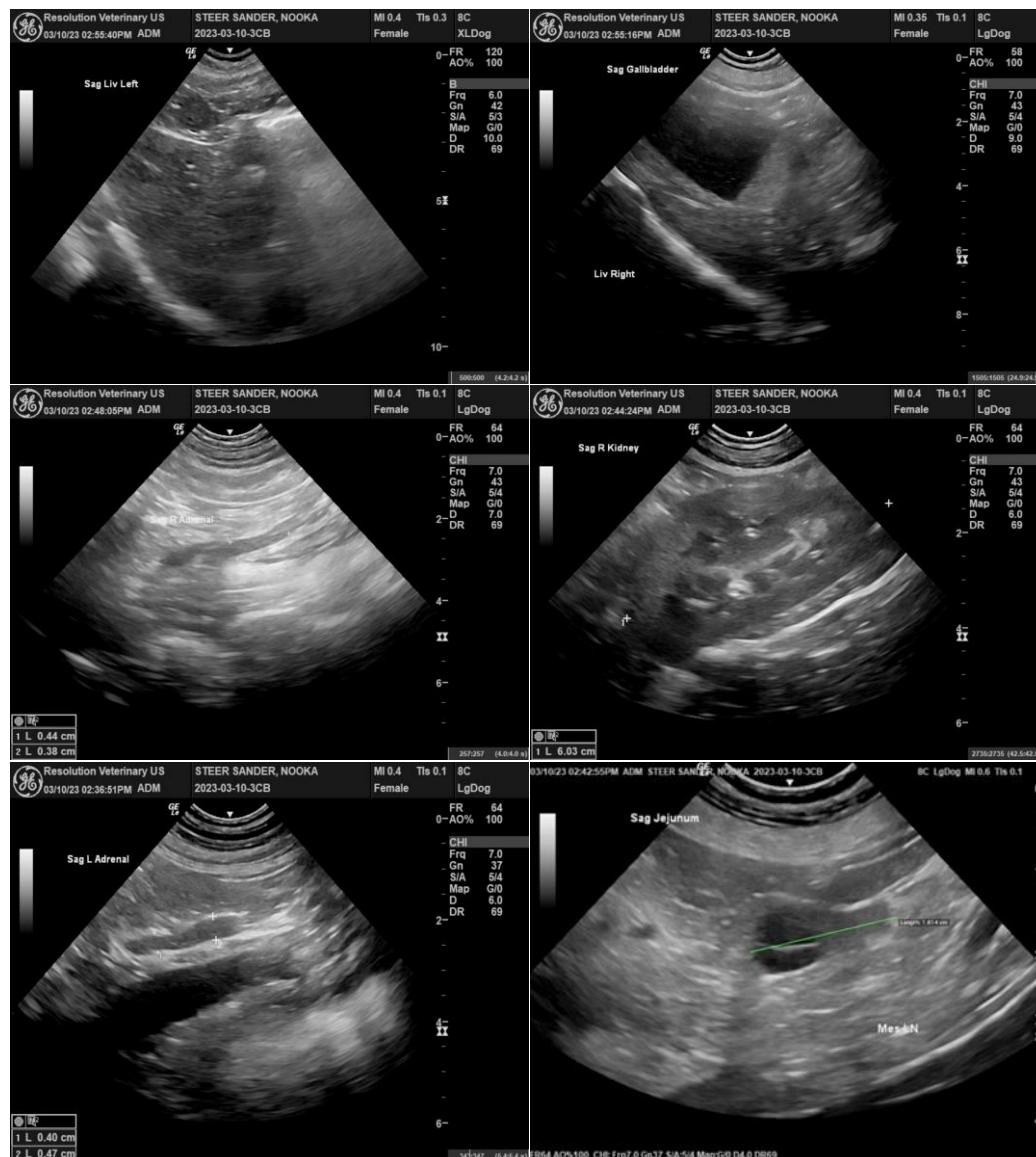
Dr. Asemadahun

INVOICE

16337

DATE

3/10/23



The information and recommendations provided are based on the images presented by the referring veterinarian/sonographer. No evaluation can be communicated regarding pathology that was not visible in the image/video clips provided.

Thank you for this referral. If the clinical or image interpretation does not parallel your findings or if I can be of any further assistance please contact me.

R. McKenzie Daniel, DVM, DABVP (Canine / Feline Practice)
info@SonoPath.com