



PATIENT

Rosie Steeber

SPECIES

Feline

BREED

DSH

SEX

Spayed female

AGE

9 years

WEIGHT

6 pounds

INTERPRETED BY

R. McKenzie Daniel,
DVM, DABVP
(Canine and Feline)

IMAGING PERFORMED BY

Tasha

HOSPITAL NAME

Dillsburg Veterinary
Center

REFERRING VET

Dr. Crow

INVOICE

10094ag

DATE

03/01/2022

PRESENTING CLINICAL SIGNS

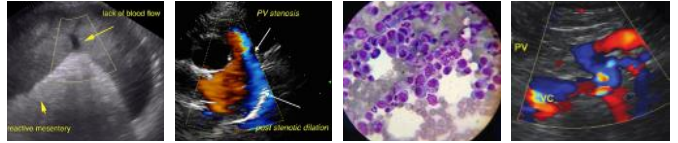
History: HX of murmur noted 2 years ago; No symptoms; 4.5 lb weight loss since last year, another 1.5 lb weight loss in past month. Recent decreased appetite, constipation, dehydration, muscle atrophy. BW WNL. Not currently on any meds.

ULTRASONOGRAPHIC EXAMINATION OF THE HEART AND ABDOMEN

FELINE CARDIAC PARAMETERS	BODY WEIGHT (kg)	HR (BPM)	IVSd (cm)	LVIDd (cm)	LVWd (cm)	FS (%)	EF (%)
NORMAL PARAMETER	-----	150-240	0.3-0.6	1.0-2.1	0.25-0.6	35-67	80-100
PATIENT		NM	0.55	1.30	0.52	43.9	78.6
FELINE CARDIAC PARAMETERS	LA/AO (Boon)	LA/AO HEART BASE (Sisson)	LA 2D 4-chamber long axis AS to FW (Sisson) (cm)	LVOT VEL. (m/s)	RVOT VEL. (m/s)	IVRT (m/)	
NORMAL PARAMETER	<1.5	0.88-1.79	0.7-1.7	<1.6	<1.3	40-60	
PATIENT	NM	1.26	1.2	NM	NM	NM	NM
Adapted from June Boon, Veterinary Echocardiography, 1998							
Sisson D et al. JVIM 1991; 5: 232, Jacobs et al. Am J Vet Res 1985; 46:1705							

Cardiac Presentation

The echocardiogram in this patient demonstrated normal left atrial size based on 3 separate LA measurements. The cranial and caudal mitral valve leaflets presented normal linear structure and kinetics. The left ventricle presented normal thicknesses with linear contour and was not dilated nor restricted. The myocardium presented normal echogenicity without subjective evidence of significant fibrotic or ischemic disease. Contractility of the ventricular walls was adequate and in normal range for this patient evidenced by the fractional shortening measurement and subjective evaluation of the different regions and angles of the myocardium. The left ventricular outflow tract demonstrated normal laminar flow and subjective structural integrity. The right atrium and auricle revealed normal size, structure and content. No evidence of masses was noted or chamber overload. Tricuspid valvular assessment demonstrated adequate linear morphology and kinetics. The right ventricle was of normal size (1/3 diameter of LV), chordae structure, myocardial echogenicity and thickness. Pulmonic tract assessment revealed normal valve structure, laminar flow, and diameter (approx. 1:1 pa/ao ratio). No visible pericardial or free pleura fluid was noted or extra cardiac pathology in the visible planes. The cranial mediastinum and pericardial regions were free of masses in the visible window.



PATIENT

Urinary System

Rosie Steeber

The urinary bladder, trigone, cystourethral junction, and visible pelvic urethra to a depth of 2 cm exhibited normal thickness and tone. Anechoic urine was present in the lumen with no uroliths or sediment. The ureteral papillae were normal. The ureters were not visible which is normal. No evidence of inflammatory or neoplastic changes were noted.

SPECIES

Feline

Normal size and margination was present in the kidneys. A normal 1:3 cortex / medulla ratio was maintained. The medulla and cortices were uniform in texture with some mildly increased echogenicity and mild loss of corticomedullary symmetry and definition expected for the age of the patient. Areas of medullary mineral primarily in the area of the pelvis with concurrent mild pyelectasia was present in both kidneys. The left kidney measured 3.2 cm in length. The right kidney measured 4.4 cm in length.

BREED

DSH

SEX

Spayed female

The area of the aortic trifurcation was free of pathology.

Adrenal Glands

No overt pathology in the area of the left or right adrenal gland although not definitively visualized.

AGE

9 years

Spleen

The spleen exhibited a finely textured and homogenous parenchyma which was hyperechoic to the liver and renal cortical parenchyma. The capsule was smooth and regular without apparent expansion. The splenic vasculature at the hilus was normal in volume with no evidence of congestion or thrombosis. Acute to chronic inflammatory, neoplastic, or benign parenchyma changes were not noted.

WEIGHT

6 pounds

Liver

INTERPRETED BY

R. McKenzie Daniel,
DVM, DABVP
(Canine and Feline)

The liver was subjectively normal in size, structure, and contour. The liver parenchyma was uniform and hypoechoic to the spleen with a mild coarse echotexture. The hepatic and portal vasculature were normal in appearance without signs of congestion. The gallbladder was non-distended in size with thin walls and primarily anechoic luminal content. The cystic and common bile ducts were normal.

IMAGING PERFORMED BY
Tasha

Gastrointestinal

The stomach presented intact wall layering with a normal wall layer ratio. The lumen of the stomach was empty with no signs of ileus, obstruction or foreign material. The gastric body wall measured 0.26 cm.

The small intestine presented intact wall layering with subjective propensity for mildly prominent segmental muscularis layer. The lumen of the small intestine was empty with no signs of ileus, obstruction or foreign material. No overt evidence of intestinal masses was observed.

HOSPITAL NAME

Dillsburg Veterinary
Center

Normal visible colon wall layers were present with apparent formed feces in lumen.

REFERRING VET

Dr. Crow

Pancreas

The parenchyma of the left limb, body and right limb of the pancreas presented isoechoic to the adjacent omental fat. A normal curvilinear capsule contour of the pancreas was present. The visible pancreatic duct was normal. No signs of active inflammation or neoplastic disease was evident.

INVOICE

10094ag

Free Abdomen

No omental masses, lymphadenopathy or peritoneal effusion.

DATE

03/01/2022



PATIENT

Rosie Steeber

SPECIES

Feline

BREED

DSH

SEX

Spayed female

AGE

9 years

WEIGHT

6 pounds

INTERPRETED BY

R. McKenzie Daniel,
DVM, DABVP
(Canine and Feline)

IMAGING PERFORMED BY

Tasha

HOSPITAL NAME

Dillsburg Veterinary
Center

REFERRING VET

Dr. Crow

INVOICE

10094ag

DATE

03/01/2022

ULTRASONOGRAPHIC FINDINGS

- Overtly normal cardiac structure and function.
- Suspect segmental to potentially generalized inflammatory enteropathy/IBD.

INTERPRETATION OF THE FINDINGS & FURTHER RECOMMENDATIONS

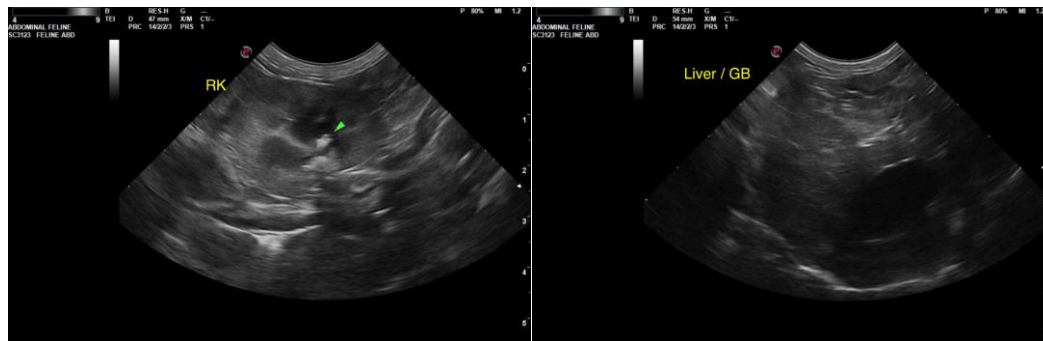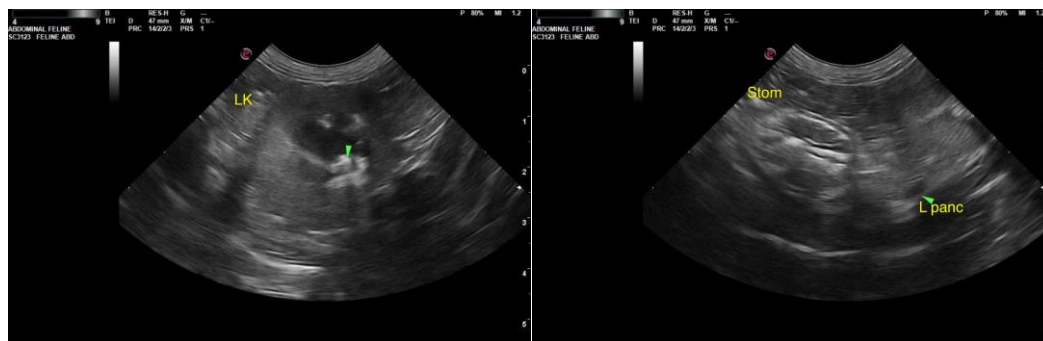No overt evidence of significant structural or functional cardiomyopathy. An obvious cause of the murmur was not definitively present in the study. Assuming no evidence of volume change such as dehydration or anemia, a physiologic flow murmur or small flow abnormality not visualized may be possible. The overall normal cardiac structure and function indicate that the risk secondary to the murmur is low. No indication for cardiac medications. Conservative monitoring of the murmur with a recheck echocardiogram if clinical signs arise or if murmur intensity increases is recommended.

Although not definitive the small intestine exhibited subtle mural changes which may suggest inflammatory enteropathy given the patient's weight loss and loss of muscle mass. However, given the lack of reported gastrointestinal signs such as diarrhea, vomiting etc. this finding is nonspecific.

Further assessment to include a GI panel including TLI/PLI/Cobalamin/Folate is recommended.

Three view chest radiographs suggested to rule out occult thoracic pathology as a contributing factor to the patient's weight loss.

Additional visceral pathology as an obvious cause of the weight loss was not definitively evident.





PATIENT

Rosie Steeber

SPECIES

Feline

BREED

DSH

SEX

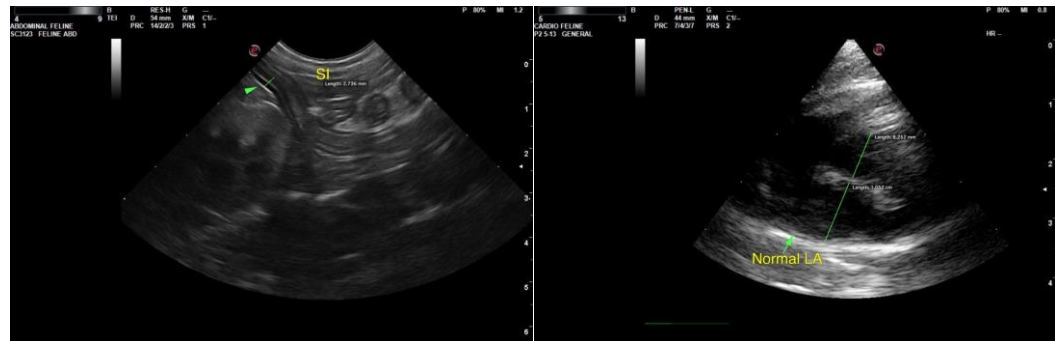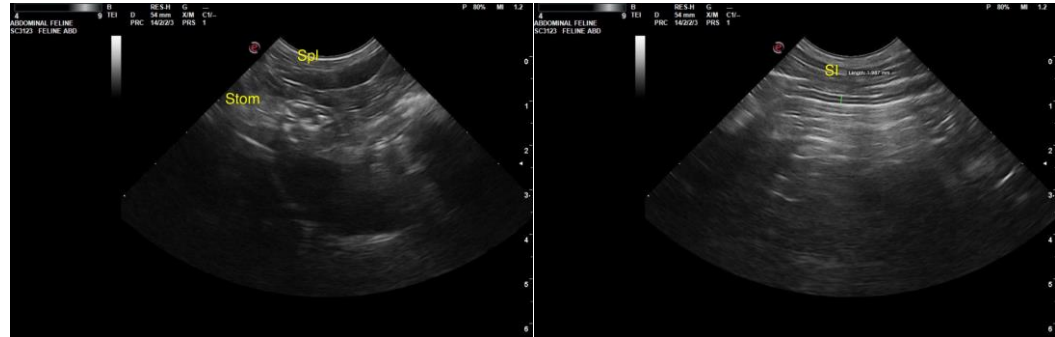Spayed female

AGE

9 years

WEIGHT

6 pounds



INTERPRETED BY

R. McKenzie Daniel,
DVM, DABVP
(Canine and Feline)

**IMAGING
PERFORMED BY**
Tasha

HOSPITAL NAME

Dillsburg Veterinary
Center

REFERRING VET

Dr. Crow

INVOICE

10094ag

DATE

03/01/2022

The information and recommendations provided are based on the images presented by the referring veterinarian/sonographer. No evaluation can be communicated regarding pathology that was not visible in the image/video clips provided.

Thank you for this referral. If the clinical or image interpretation does not parallel your findings or if I can be of any further assistance please contact me.

R. McKenzie Daniel, DVM, DABVP (Canine / Feline Practice)

info@SonoPath.com