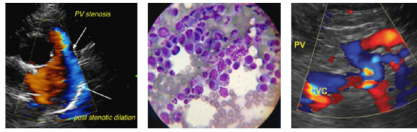



**IMAGING PERFORMED BY**

SVS Mobile Imaging CT 262-366-5970  
fredgromalak@gmail.com

**PATIENT**

Duncan Yandell

**SPECIES**

Canine

**BREED**

Labrador Retriever

**SEX**

Neutered Male

**AGE**

11 Years

**WEIGHT**

Neutered Male

**INTERPRETED BY**

R. McKenzie Daniel,  
DVM, DABVP  
(Canine and Feline)

**IMAGING PERFORMED BY**

Tom McNeill

**HOSPITAL NAME**

SVS Imaging CT

**REFERRING VET**

Madison Vet  
Specialists

**INVOICE**

35794

**DATE**

3/2/22

**PRESENTING CLINICAL SIGNS**

Acute onset of lethargy and inappetence for the past 18 hours. Hemoabdomen found.  
Abnormal PE/Chem/CBC/UA Results: PCV/TS abdominal fluid: 22%/4.8 PCV/TS peripheral fluid: 23%/6.0

**ULTRASONOGRAPHIC EXAMINATION OF THE ABDOMEN****Urinary System**

The urinary bladder exhibited normal thickness and tone. Anechoic urine was present in the lumen with no uroliths or sediment. The ureteral papillae were normal. The ureters were not visible which is normal. No evidence of inflammatory or neoplastic changes were noted. Potential mild lateral displacement of the urinary bladder secondary to the caudal abdominal to pelvic inlet mass. No overt pathology associated with the residual prostate.

Normal size and margination were present in the kidneys. A normal 1:3 cortex / medulla ratio and normal corticomedullary definition were maintained. The echogenicity of the cortex was similar to or slightly less than normal liver parenchyma while the medulla echogenicity was hypoechoic to the cortex with no evidence of pelvic dilation. The left kidney measured 7.4 cm. The right kidney measured 8.2 cm.

**Adrenal Glands**

The adrenal glands were uniform in size and contour with a uniformly hypoechoic parenchyma. The left adrenal gland measured 0.51 cm at the cranial pole and 0.77 cm at the caudal pole. The right adrenal gland measured 0.84 cm at the caudal pole.

**Spleen**

The discernable visualized spleen exhibited subtle asymmetrical lateral and medial capsule contour. Overall, normal subjective size with generalized parenchyma heterogeneity.

**Liver**

The liver was subjectively normal in size, structure, and contour. The liver parenchyma was mildly nonuniform and hypoechoic to the spleen with a moderate coarse echotexture and subjective mild to benign parenchymal remodeling. The hepatic and portal vasculature were normal in appearance without signs of congestion. The gallbladder was non-distended in size with thin walls and primarily anechoic luminal content. The cystic and common bile ducts were normal.

**Gastrointestinal**

The stomach presented intact wall layering with a normal wall layer ratio. The lumen of the stomach was empty with no signs of ileus, obstruction or foreign material.

The small intestine presented intact wall layering with 1:3 muscularis/mucosa ratio. The lumen of the small intestine was empty with no signs of ileus, obstruction or foreign material.

Normal visible colon wall layers were present with apparent formed feces in lumen.

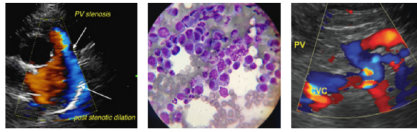

**Pancreas**

The parenchyma of the left limb, body and right limb of the pancreas presented isoechoic to the adjacent omental fat. A normal curvilinear capsule contour of the pancreas was present. The visible pancreatic duct was normal. No signs of active inflammation or neoplastic disease was evident.

**Free Abdomen**

**IMAGING PERFORMED BY**

SVS Mobile Imaging CT 262-366-5970  
fredgromalak@gmail.com



**PATIENT**

Duncan Yandell

A large, expansive, non-homogeneous to cavitated mass occupied the caudal abdomen to pelvic inlet. The mass measured approximately 15-16 cm in diameter.

**SPECIES**

Canine

Concurrent, unspecified, non-homogeneous mass was present in the mid to cranial abdomen medial to the spleen with potential for direct effacement to the caudal spleen, measuring approximately 8.0 cm in diameter. Associated reactive mesentery noted around both the caudal abdominal/pelvic inlet mass as well as the undifferentiated mid to cranial abdominal mass.

**BREED**

Labrador Retriever

A solitary medial iliac lymph node was present, measuring 0.51 cm in width. The lymph node was essentially isoechoic to adjacent omentum without evidence of peripheral inflammation and maintaining a normal width: length ratio (<0.5). The lymph node was not consistent with inflammatory or neoplastic criteria.

**SEX**

Neutered Male

Intermittent mildly prominent yet isoechoic mesenteric lymph nodes present, exhibiting normal width to length ratio of <0.5. Example measured 0.68 cm. Mesenteric lymph nodes were also not consistent with inflammatory or neoplastic criteria.

**AGE**

11 Years

Moderate volume peritoneal free fluid present, exhibiting mild cellular component.

**WEIGHT**

Neutered Male

**ULTRASONOGRAPHIC FINDINGS**

- Large, non-homogeneous to cavitated caudal abdominal/pelvic inlet mass
- Concurrent undifferentiated non-homogeneous mass in the mid to cranial abdomen medial to the spleen
- Moderate volume peritoneal free fluid
- Regional to generalized reactive mesentery and intermittent subjectively reactive to benign mesenteric/medial iliac lymphadenopathy
- Hepatic parenchymal remodeling – subjectively benign, overt hepatic neoplasia/metastasis not noted.

**INTERPRETED BY**

R. McKenzie Daniel,  
DVM, DABVP  
(Canine and Feline)

**INTERPRETATION OF THE FINDINGS & FURTHER RECOMMENDATIONS**

Although sampling is required for further clarification, the caudal abdominal/pelvic inlet mass as well as the undifferentiated mass in the mid to cranial abdomen is consistent with neoplastic criteria with multicentric undifferentiated sarcoma considered most probable. Other neoplastic etiologies may be possible with non-neoplastic etiologies considered unlikely. Potential for regional omental seeding around the masses is of concern along with previously diagnosed hemoabdomen, often seen with sarcoma. Given this presentation, surgical options are most likely precluded, and unfortunately an unfavorable prognosis is likely indicated. Further assessment may include abdominal CT. 3-view chest radiographs and ideally sonographic assessment of the heart for further staging recommended.

**IMAGING PERFORMED BY**

Tom McNeill

**HOSPITAL NAME**

SVS Imaging CT

**REFERRING VET**

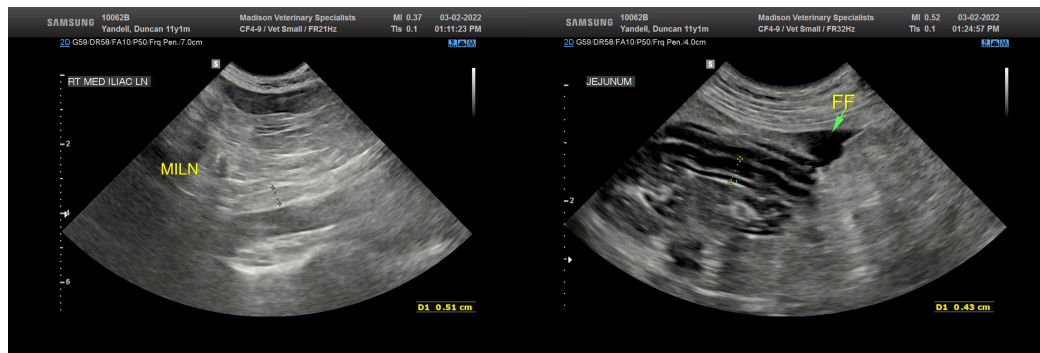
Madison Vet Specialists

**INVOICE**

35794

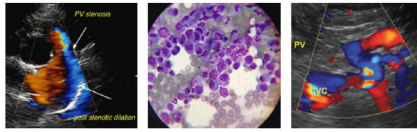

**DATE**

3/2/22



IMAGING PERFORMED BY

SVS Mobile Imaging CT 262-366-5970  
fredgromalak@gmail.com



Clinical Sonography & Telectology

EDUCATIONAL TELECONSULTATION SERVICES™

1-800-838-4268 info@sonopath.com SonoPath.com

PATIENT

Duncan Yandell

SPECIES

Canine

BREED

Labrador Retriever

SEX

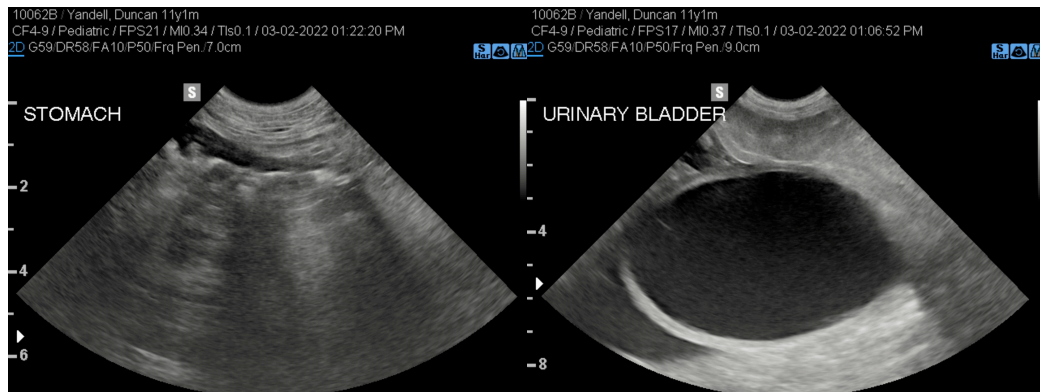
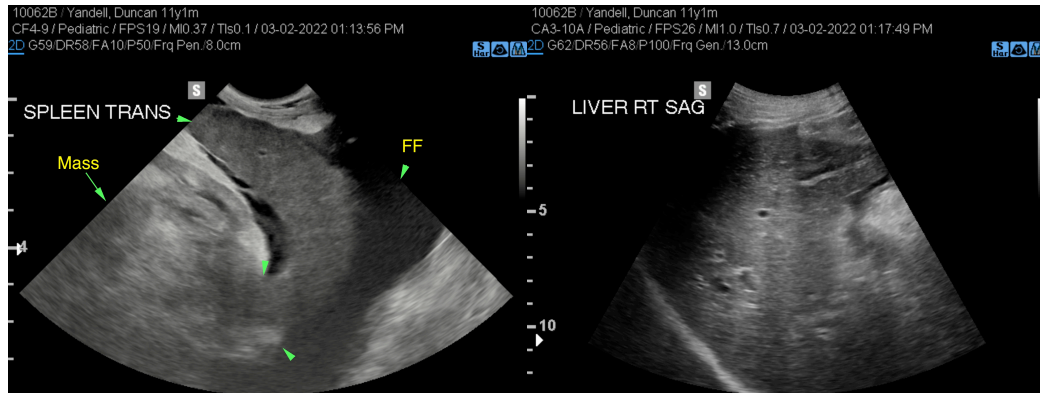
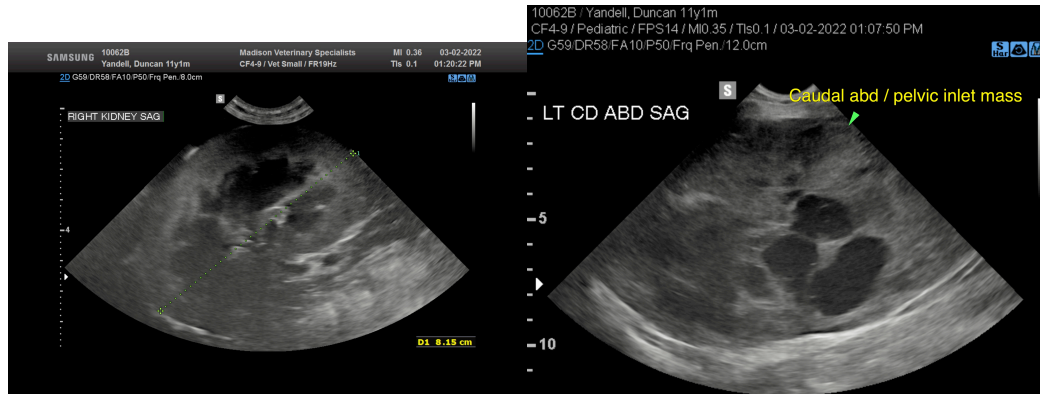
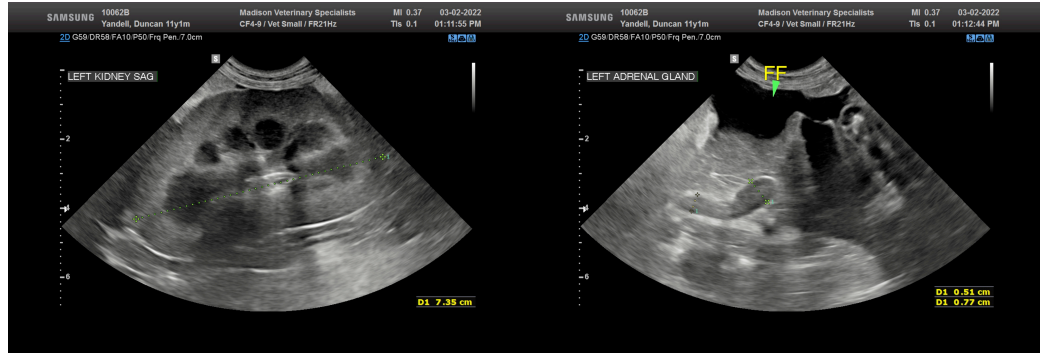
Neutered Male

AGE

11 Years

WEIGHT

Neutered Male



INTERPRETED BY

R. McKenzie Daniel,  
DVM, DABVP  
(Canine and Feline)

IMAGING PERFORMED BY

Tom McNeill

HOSPITAL NAME

SVS Imaging CT

REFERRING VET

Madison Vet  
Specialists

INVOICE

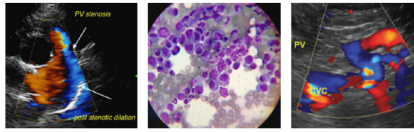

35794

DATE

3/2/22

**IMAGING PERFORMED BY**

SVS Mobile Imaging CT 262 - 366 - 5970  
fredgromalak@gmail.com



EDUCATIONAL TELECONSULTATION SERVICES™  
1-800-838-4268 info@sonopath.com SonoPath.com

**PATIENT**

Duncan Yandell

**SPECIES**

Canine

**BREED**

Labrador Retriever

**SEX**

Neutered Male

**AGE**

11 Years

**WEIGHT**

Neutered Male

**INTERPRETED BY**

R. McKenzie Daniel,  
DVM, DABVP  
(Canine and Feline)

**IMAGING PERFORMED BY**

Tom McNeill

**HOSPITAL NAME**

SVS Imaging CT

**REFERRING VET**

Madison Vet  
Specialists

**INVOICE**

35794

**DATE**

3/2/22

The information and recommendations provided are based on the images presented by the referring veterinarian/sonographer. No evaluation can be communicated regarding pathology that was not visible in the image/video clips provided.

Thank you for this referral. If the clinical or image interpretation does not parallel your findings or if I can be of any further assistance please contact me.

**R. McKenzie Daniel, DVM, DABVP (Canine / Feline Practice)**

info@SonoPath.com