



PATIENT

Copper Ballard

SPECIES

Feline

BREED

DSH

SEX

MN

AGE

8yr

WEIGHT

15.5lb

INTERPRETED BY

R. McKenzie Daniel,
DVM, DABVP
(Canine and Feline)

IMAGING PERFORMED BY

Dr. Cecelia Dean

HOSPITAL NAME

Wellesley Animal
Hospital

REFERRING VET

Dr. Cecelia Dean

INVOICE

23843

DATE

02/09/2026

PRESENTING CLINICAL SIGNS

- Presents for pre-anesthetic echo prior to anesthesia for a COHAT.
- New heart murmur ausculted on most recent exam
- ProBNP WNL
- Medications: Laxatone, lysine

Abnormal PE/Chem/CBC/UA Results: PE: BCS 7/9; 3/6 parasternal murmur; moderate gingivitis
CBC/Chem/T4/HWT: WNL ProBNP: 49 (WNL)

PRE-ANESTHETIC ECHOCARDIOGRAM

10 cardiac efficiency clips from SDEP protocol provided. All four chambers revealed normal volumes and contractility.

No evidence of volume or pressure overload. No pericardial or pleural effusion noted. No gross abnormalities that would preclude anesthesia.

The current hemodynamic effects of the reported murmur appear low.

INTERPRETATION OF THE FINDINGS & FURTHER RECOMMENDATIONS

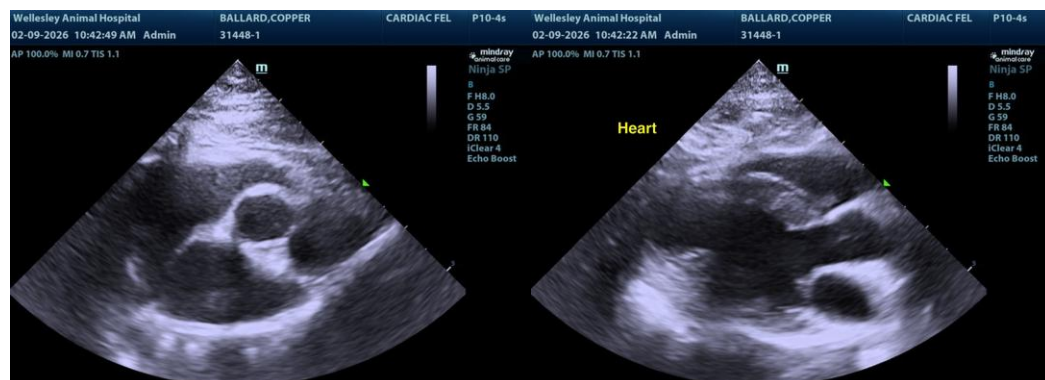
Normal pre-anesthetic echocardiogram.

Anesthetic risk is considered normal to mild. No gross abnormalities noted on

SDEP Screening Echo to contraindicate anesthesia. Minimal to no left atrial enlargement noted on images presented.

a. However, judicious fluid administration is advised with careful RR/RE monitoring to screen for fluid overload.

b. Monitoring of blood pressure, SpO₂, CO₂, and auscultation of heart and lungs during anesthesia should be done during every procedure.





PATIENT

Copper Ballard

The information and recommendations provided are based on the images presented by the referring veterinarian/sonographer. No evaluation can be communicated regarding pathology that was not visible in the image/video clips provided.

SPECIES

Feline

Thank you for this referral. If the clinical or image interpretation does not parallel your findings or if I can be of any further assistance, please contact me.

BREED

DSH

R. McKenzie Daniel, DVM, DABVP (Canine/Feline Practice)

info@sonopath.com

SEX

MN

AGE

8yr

WEIGHT

15.5lb

INTERPRETED BY

R. McKenzie Daniel,
DVM, DABVP
(Canine and Feline)

IMAGING PERFORMED BY

Dr. Cecelia Dean

HOSPITAL NAME

Wellesley Animal
Hospital

REFERRING VET

Dr. Cecelia Dean

INVOICE

23843

DATE

02/09/2026