



## PATIENT

Coco Gardner

## SPECIES

Canine

## BREED

Cavalier King Charles Spaniel

## SEX

FS

## AGE

11 years 10 months

## WEIGHT

20.2 lbs.

## INTERPRETED BY

R. McKenzie Daniel,  
DVM, DABVP  
(Canine and Feline)

## IMAGING PERFORMED BY

Shari Reffi, CVT

## HOSPITAL NAME

Shohola VH

## REFERRING VET

Dr. Gramazio

## INVOICE

16088

## DATE

2/9/23

## PRESENTING CLINICAL SIGNS

Grade III/VI heart murmur. VHS 11.56. No current meds.

## ULTRASONOGRAPHIC EXAMINATION OF THE HEART

CANINE CARDIAC PARAMETERS	MR VMAX (m/s)	TR VMAX (m/s)	LA/AO (Boon method)	LA/AO (Heart Base; Swe)	FS (%)	EF (%)	EPSS (cm)
NORMAL PARAMETER	4.5-5.5	<2.7	1.3	<1.3	28-40	40-100	<0.6
PATIENT	3.0	2.3	1.1	1.2	41.4	73.5	0.23
CANINE CARDIAC PARAMETERS	HR (BPM)	AV VMAX (m/s)	PV MAX (m/s)	BODY WEIGHT (kg)	LA 2D short axis Base view (cm)	LVIDd Avg; 2D and m- mode short axis (cm)	LVIDs Avg; 2D and m-mode short axis (cm)
NORMAL PARAMETER	50-100	0.7-1.7	0.7-1.6				
PATIENT	127	1.0	0.9		3.5	3.3	

## Cardiac Presentation

The echocardiogram in this patient demonstrated normal **left atrial** size based on 3 different LA measurement methods. Chamber volumes and echogenicity were normal. The cranial and caudal **mitral** valve leaflets presented moderate thickening consistent with endocardiosis. No evidence of valvular prolapse. Doppler indicated measurable eccentric insufficiency. The **left ventricle** presented normal thicknesses with linear contour and was not dilated nor restricted. The **myocardium** presented normal echogenicity without subjective evidence of significant fibrotic or ischemic disease. **Contractility** of the ventricular walls was adequate and in normal range for this patient evidenced by the fractional shortening measurement and subjective evaluation of the different regions of the myocardium. The **left ventricular outflow** tract demonstrated normal laminar flow and subjective structural integrity. The **right atrium** and auricle revealed normal size, structure and content. No evidence of masses was noted or chamber overload. **Tricuspid** valvular assessment revealed concurrent mild thickening with mild TR on Doppler. The **right ventricle** was of normal size (1/3 diameter of LV), chordae structure, myocardial echogenicity and thickness. **Pulmonic** tract assessment revealed normal valve structure, laminar flow, and diameter (approx.1:1 pa/ao ratio). No visible **pericardial** or free pleura fluid was noted. No echographically detectable evidence of infiltrative disease was visible. The cranial **mediastinum and pericardial regions** were free of masses in the visible window.



## PATIENT

Coco Gardner

## SPECIES

Canine

## BREED

Cavalier King Charles Spaniel

## SEX

FS

## AGE

11 years 10 months

## WEIGHT

20.2 lbs.

## INTERPRETED BY

R. McKenzie Daniel,  
DVM, DABVP  
(Canine and Feline)

## IMAGING PERFORMED BY

Shari Reffi, CVT

## HOSPITAL NAME

Shohola VH

## REFERRING VET

Dr. Gramazio

## INVOICE

16088

## DATE

2/9/23

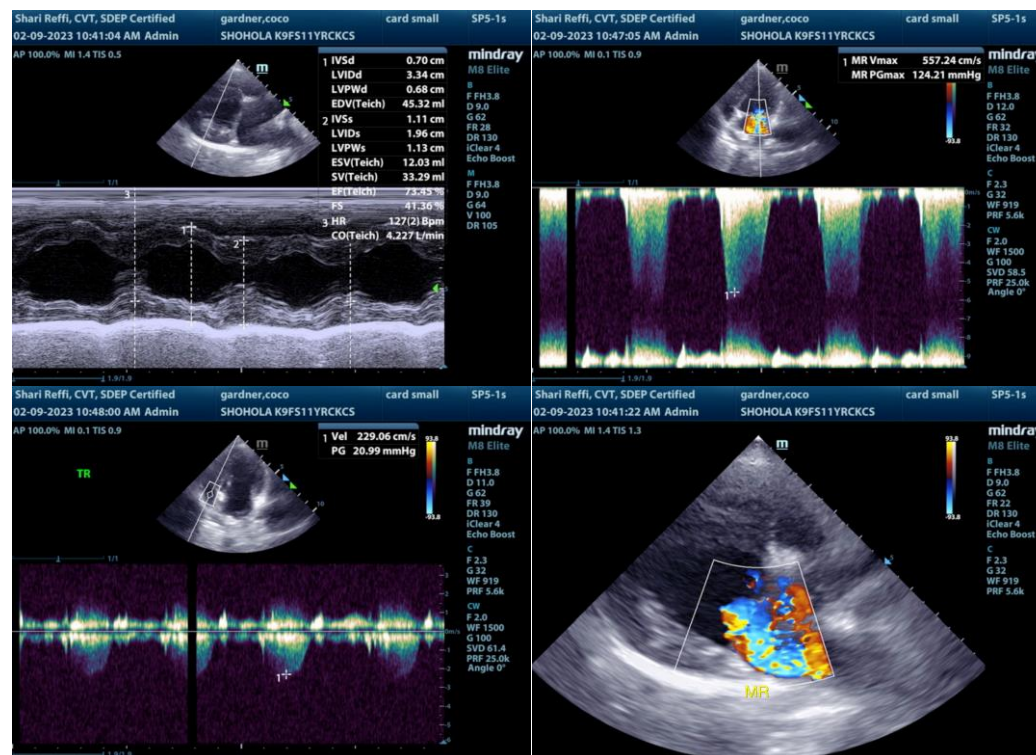
## ULTRASONOGRAPHIC FINDINGS

- Chronic mitral valve disease (ACVIM B1)
- Mild TR - No evidence of clinical pulmonary hypertension

## INTERPRETATION OF THE FINDINGS & FURTHER RECOMMENDATIONS

The lack of left atrium enlargement at this stage indicates that the current and future risk of complication secondary to MR is low.

No indication for cardiac medications at this stage, yet the prognosis is variable, and serial sonographic monitoring is recommended. Recheck echocardiogram is recommended in 6-8 months, sooner if clinical signs arise.





**PATIENT**

Coco Gardner

**SPECIES**

Canine

**BREED**

Cavalier King Charles Spaniel

**SEX**

FS

**AGE**

11 years 10 months

**WEIGHT**

20.2 lbs.

**INTERPRETED BY**

R. McKenzie Daniel,  
DVM, DABVP  
(Canine and Feline)

**IMAGING PERFORMED BY**

Shari Reffi, CVT

**HOSPITAL NAME**

Shohola VH

**REFERRING VET**

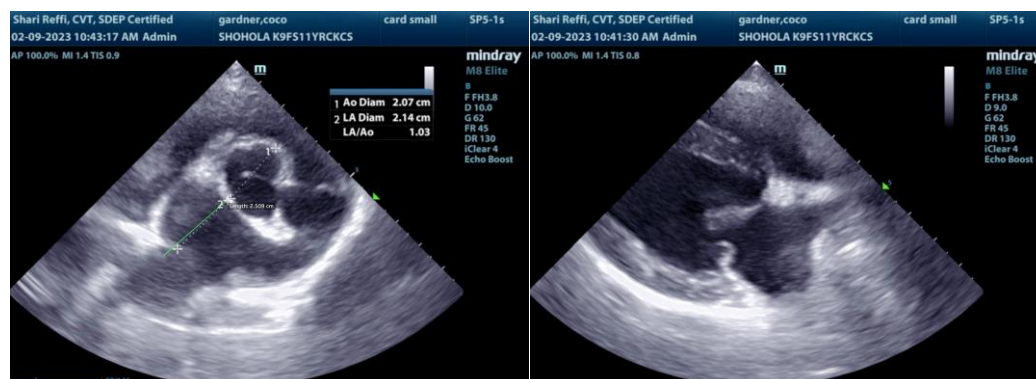
Dr. Gramazio

**INVOICE**

16088

**DATE**

2/9/23



The information and recommendations provided are based on the images presented by the referring veterinarian/sonographer. No evaluation can be communicated regarding pathology that was not visible in the image/video clips provided.

Thank you for this referral. If the clinical or image interpretation does not parallel your findings or if I can be of any further assistance please contact me.

**R. McKenzie Daniel, DVM, DABVP (Canine / Feline Practice)**  
info@SonoPath.com