**PATIENT**

Pica Joseph

SPECIES

Canine

BREED

Pug

SEX

FS

AGE

13 years

WEIGHT

9 lbs.

INTERPRETED BYR. McKenzie Daniel,
DVM, DABVP (Canine
and Feline)**IMAGING
PERFORMED BY**

Sarah Pender, CVT

HOSPITAL NAME

SVS Imaging KC

REFERRING VET

Dr. Taylor

INVOICE

13289

DATE

2/9/22

PRESENTING CLINICAL SIGNS

Senior pet, chronic weight loss, elevated liver values. Has recently been to another hospital for these issues and quality of life. Very thin, incontinent - has 4-6 BM per day. Wants to eat, but seems like it runs right through her.

ULTRASONOGRAPHIC EXAMINATION OF THE ABDOMEN**Urinary System**

The urinary bladder was normal in size and tone containing anechoic urine. The urinary bladder walls were primarily normal in appearance with subjective mild variable thickening in the area of the dorsal cystourethral junction and trigone. The dorsal cystourethral junction wall measured 0.52 cm width. No calculi were noted. The proximal urethra was ill-visualized with subjective normal tone to a depth of 2.0 cm.

The area of the aortic trifurcation was free of pathology.

Normal size and margination were present in the kidneys. A normal 1:3 cortex / medulla ratio was maintained. The medulla and cortices were uniform in texture with some increased echogenicity and mild loss of corticomodullary symmetry and definition expected for the age of the patient. Mild pyelectasia was present. The left kidney measured 3.7 cm in length. The right kidney measured 3.5 cm in length.

Adrenal Glands

The left adrenal gland was uniform in size and contour with a uniformly hypoechoic parenchyma. The left adrenal gland measured 0.33 cm width at the caudal pole and 0.29 cm width at the cranial pole. The right adrenal gland was uniform in size and contour with a uniformly hypoechoic parenchyma. The right adrenal gland measured 0.35 cm width at the caudal pole.

Spleen

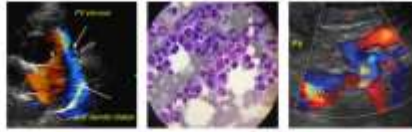The spleen exhibited a finely textured and homogenous parenchyma which was hyperechoic to the liver and renal cortical parenchyma. The capsule was smooth and regular without apparent expansion. The splenic vasculature at the hilus was normal in volume with no evidence of congestion or thrombosis. Acute to chronic inflammatory, neoplastic, or benign parenchyma changes were not noted.

Liver/ Gallbladder

The liver presented enlarged in size. The parenchyma of the liver was subjectively normal in echogenicity compared to the spleen and renal cortices. The liver parenchyma was uniform with a mildly coarse echotexture. The capsule of the liver was symmetrically rounded to mildly swollen in margination. The hepatic and portal vasculature were normal in appearance without signs of congestion. Mild, nondependent yet nonorganized gallbladder debris was present. The cystic and common bile ducts were normal.

Gastrointestinal

The visualized gastric walls were sonographically normal. The lumen of the stomach contained moderate, variably echogenic ingesta with concurrent mild retained fluid.

**PATIENT**

Pica Joseph

The small intestine presented intact wall layering and primarily maintained a 1:3 muscularis/mucosa ratio with segmental to generalized mucosa speckling along with segmental areas of mild distention with retained non-shadowing chyme.

SPECIES

Canine

Normal visible colon wall layers were present. The colon exhibited generalized distention with semi-formed to soft feces.

Pancreas**BREED**

Pug

The pancreas was normal in size and contour with heterogeneous to mildly echogenic parenchyma compared to adjacent omentum. No signs of active inflammation or neoplasia.

Free Abdomen**SEX**

FS

No overt or significant lymphadenopathy was present. Small pockets of scant peritoneal free fluid were present. Subjective mild generalized reactive mesentery was noted.

ULTRASONOGRAPHIC FINDINGS**AGE**

13 years

Primary Findings

- Bilateral chronic renal changes with mild pyelectasia
- Subjective mildly thickened dorsal trigone / cystourethral junction
- Hepatomegaly - subjectively benign
- Mild gallbladder debris (non-mucocele)
- Moderate, retained, variably echogenic gastric ingesta
- Mild segmental to generalized small bowel mucosal speckling and segmental retained chyme
- Pancreatic remodeling - possible low-grade to chronic pancreatitis

WEIGHT

9 lbs.

INTERPRETED BY

R. McKenzie Daniel,
DVM, DABVP (Canine
and Feline)

INTERPRETATION OF THE FINDINGS & FURTHER RECOMMENDATIONS**IMAGING PERFORMED BY**

Sarah Pender, CVT

The subjective mild dorsal trigone to cystourethral junction thickening is nonspecific and may indicate a patient variant or mild regional cystitis, while the possibility of emerging neoplasia cannot be excluded. Screening BRAF Assay and sonographic monitoring of this area for evidence of progression are recommended.

HOSPITAL NAME

SVS Imaging KC

The presence of moderate gastric ingesta and retained small bowel chyme may indicate recent meal ingestion. However, if documented NPO, some degree of metabolic gastric stasis or inefficient small bowel peristalsis may be possible. Underlying gastrointestinal disease or malassimilation / maldigestion disorder, given the patient's clinical history, may be present. Further assessment may include a GI panel to include PLI/TLI/Cobalamin/Folate.

REFERRING VET

Dr. Taylor

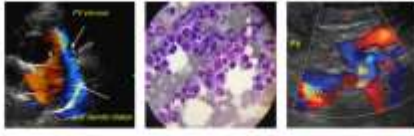INVOICE

13289

Correlation with full lab work to include albumin levels is suggested if not done. Hepatosupportive medications including Denamarin and Ursodiol may prove beneficial.

DATE

2/9/22



PATIENT

Pica Joseph

SPECIES

Canine

BREED

Pug

SEX

FS

AGE

13 years

WEIGHT

9 lbs.

INTERPRETED BY

R. McKenzie Daniel,
DVM, DABVP (Canine
and Feline)

**IMAGING
PERFORMED BY**

Sarah Pender, CVT

HOSPITAL NAME

SVS Imaging KC

REFERRING VET

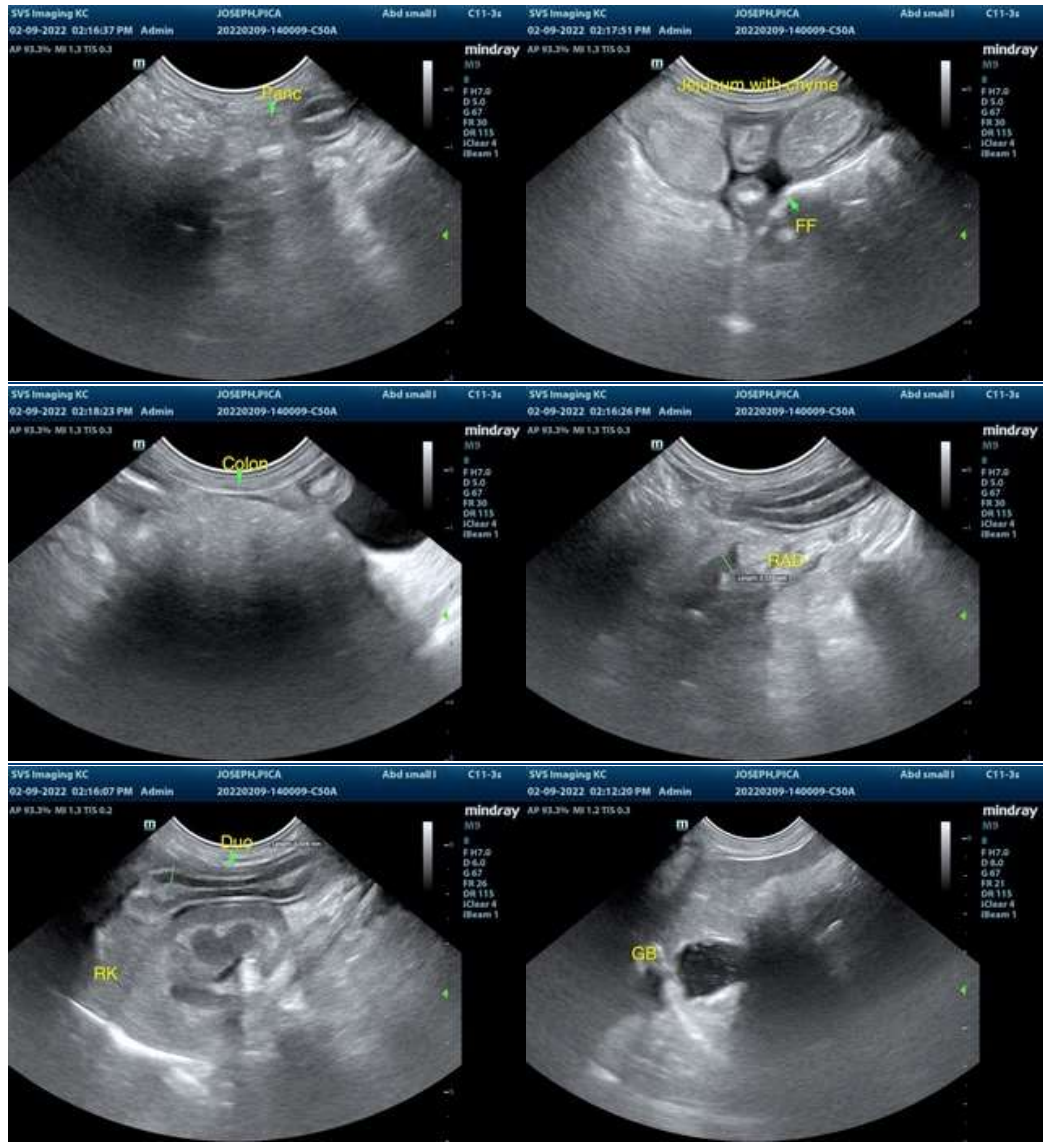
Dr. Taylor

INVOICE

13289

DATE

2/9/22





PATIENT

Pica Joseph

SPECIES

Canine

BREED

Pug

SEX

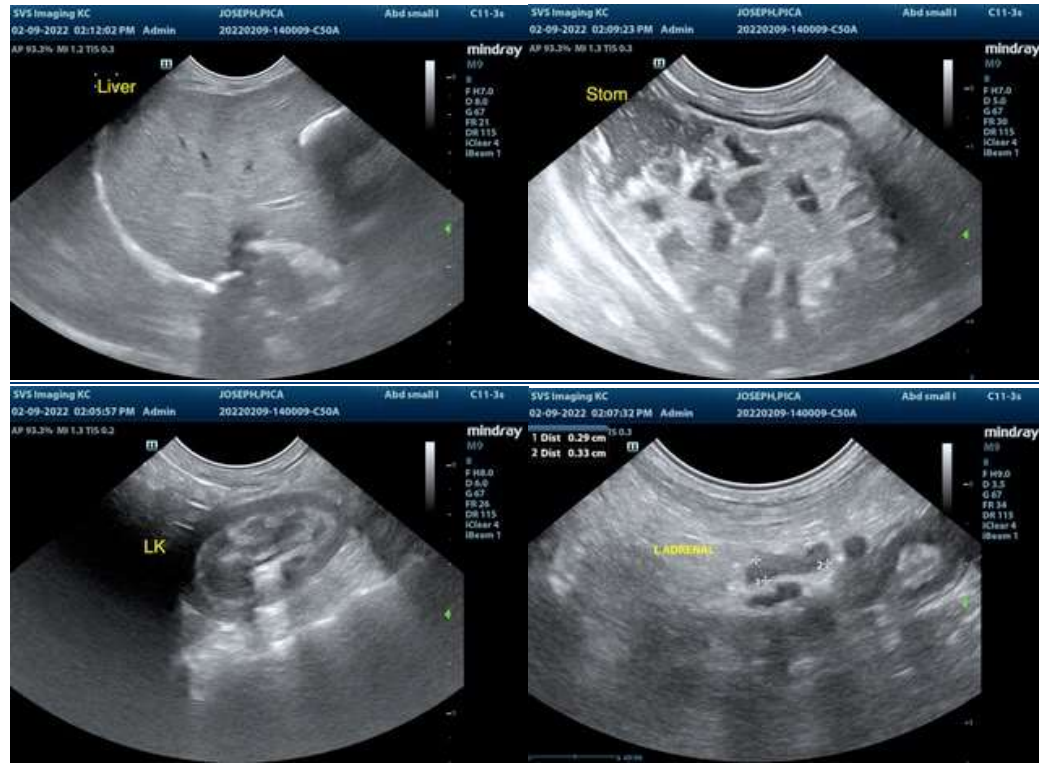FS

AGE

13 years

WEIGHT

9 lbs.



INTERPRETED BY

R. McKenzie Daniel, DVM, DABVP (Canine and Feline)

IMAGING PERFORMED BY

Sarah Pender, CVT

HOSPITAL NAME

SVS Imaging KC

REFERRING VET

Dr. Taylor

INVOICE

13289

DATE

2/9/22

The information and recommendations provided are based on the images presented by the referring veterinarian/sonographer. No evaluation can be communicated regarding pathology that was not visible in the image/video clips provided.

Thank you for this referral. If the clinical or image interpretation does not parallel your findings or if I can be of any further assistance please contact me.

R. McKenzie Daniel, DVM, DABVP (Canine / Feline Practice)
info@SonoPath.com