IMAGING PERFORMED BY

SVS IMAGING

SonoPath
Clinical Sonography & Telecytology
EDUCATIONAL TELECONSULTATION SERVICES™
1-800-838-4288 info@sonopath.com SonoPath.com

PATIENT

Genno Hahn

SPECIES

Canine

BREED

Jack Russell Terrier Mix

SEX

MN

AGE

12 years

WEIGHT

21 lbs

INTERPRETED BY

R. McKenzie Daniel, DVM, DABVP (Canine and Feline)

IMAGING PERFORMED BY

Sarah Pender, CVT

HOSPITAL NAME

SVS Imaging QC

REFERRING VET

Dr. Barbara Shields

INVOICE

13284

DATE

2/9/22

PRESENTING CLINICAL SIGNS

Asymptomatic
Abnormal PE/Chem/CBC/UA Results: Pre-anesthetic bloodwork for dental revealed azotemia, elevated liver enzymes, elevated pancreatic enzymes. Dental cancelled pending U/S report.

ULTRASONOGRAPHIC EXAMINATION OF THE ABDOMEN

Urinary System

The urinary bladder, trigone, cystourethral junction, and visible pelvic urethra to a depth of 3.0 cm exhibited normal thickness and tone. Anechoic urine was present in the lumen with no uroliths or sediment. The ureteral papillae were normal. The ureters were not visible which is normal. No evidence of inflammatory or neoplastic changes was noted.

The area of the aortic trifurcation was free of pathology.

Normal renal size with asymmetrical margination were present in both kidneys. The renal cortex presented uniformly increased in echogenicity with uniform echotexture. The renal cortex appeared to be hypertrophied resulting in an altered cortex: medulla ratio. Mild loss of corticomedullary distinction was also present. Both kidneys exhibited multiple small cortical cysts along with areas of cortical infarctions, mild pyelectasia, and mild pinpoint to focal medullary mineral. The renal medullary volume was subjectively reduced. The left kidney measured 4.9 cm in length. The right kidney measured 5.0 cm in length.

Adrenal Glands

The bilateral adrenal glands were prominent in size with nonhomogeneous to mixed echogenic parenchyma. The left adrenal gland measured 2.6 cm length x 1.1 cm width at the caudal pole. The right adrenal gland measured 2.6 cm length x 0.86 cm width at the caudal pole. Potential for very early vascular invasion associated with the right adrenal gland and potentially associated with the left adrenal gland is possible although not definitive.

Spleen

The spleen exhibited a finely textured and homogenous parenchyma which was hyperechoic to the liver and renal cortical parenchyma. The capsule was smooth and regular without apparent expansion. The splenic vasculature at the hilus was normal in volume with no evidence of congestion or thrombosis. Acute to chronic inflammatory, neoplastic, or benign parenchyma changes were not noted.

Liver/ Gallbladder

The liver exhibited generalized enlargement with mild primarily uniform increased parenchyma echogenicity. The parenchyma of the liver was subjectively increased in echogenicity compared to the spleen and renal cortices. The echotexture of the liver parenchyma was uniform with a mild coarse echotexture. The capsule of the liver was symmetrical in margination. The hepatic and portal vasculature were normal in appearance without signs of congestion. No hepatic masses or nodules were noted. Moderate, mildly inspissated yet subjectively mobile, nonmineralized gallbladder debris was present. The gallbladder was otherwise normal. The cystic and common bile ducts were normal.

IMAGING PERFORMED BY

SVS IMAGING

SonoPath
Clinical Sonography & Telecytology
EDUCATIONAL TELECONSULTATION SERVICES™
1-800-838-4288 info@sonopath.com SonoPath.com

PATIENT

Genno Hahn

SPECIES

Canine

BREED

Jack Russell Terrier Mix

SEX

MN

AGE

12 years

WEIGHT

21 lbs

INTERPRETED BY

R. McKenzie Daniel, DVM, DABVP (Canine and Feline)

IMAGING PERFORMED BY

Sarah Pender, CVT

HOSPITAL NAME

SVS Imaging QC

REFERRING VET

Dr. Barbara Shields

INVOICE

13284

DATE

2/9/22

Gastrointestinal

The stomach presented intact wall layering with a normal wall layer ratio. The lumen of the stomach was empty with no signs of ileus, obstruction, or foreign material.

The small intestine presented intact wall layering with 1:3 muscularis/mucosa ratio. The lumen of the small intestine was empty with no signs of ileus, obstruction, or foreign material.

Normal visible colon wall layers were present with apparent formed feces in lumen.

Pancreas

The pancreas was mildly prominent In size exhibiting symmetrical contour with heterogeneous to mildly hypoechoic parenchyma compared to adjacent omentum.

Free Abdomen

No overt lymphadenopathy or peritoneal effusion was present.

ULTRASONOGRAPHIC FINDINGS

- Moderate chronic renal changes exhibiting pinpoint to focal medullary mineral, cortical infarctions / cortical cysts, and mildly pyelectasia
- Bilateral mild adrenomegaly exhibiting nonhomogeneous to mixed echogenic parenchyma, possible early adrenal vascular invasion
- Hepatomegaly exhibiting mild primarily uniform parenchyma hyperechogenicity - subjectively benign- vacuolar hepatopathy, hepatitis / cholangiohepatitis, lipidosis, or other hepatopathy possible, potential for hepatic neoplasia cannot be excluded yet is thought less likely
- Moderate gallbladder debris - potential very early gallbladder mucocele
- Heterogeneous to mildly hypoechoic pancreas - nonspecific, patient / age-related variant, potential for mild chronic to chronic active pancreatitis

INTERPRETATION OF THE FINDINGS & FURTHER RECOMMENDATIONS

The pyelectasia in both kidneys may be owing to chronic renal changes, potential pelvic scarring possibly owing to previous calculi passage, IV fluid therapy (if applicable). Urine C/S and protein: creatinine ratio on sterile urine sample is recommended.

General considerations for the bilateral adrenal glands may include functional vs. nonfunctional adenoma, hyperplasia with parenchymal remodeling, while the potential yet not obvious vascular invasion associated with the right and possibly the left adrenal glands may indicate a higher potential for neoplastic criteria such as adenocarcinoma, pheochromocytoma, or other. Full adrenal workup including LDDST could be considered if clinical signs suggestive of adrenal hyperfunction are present. Assessment and monitoring of systemic blood pressure for evidence of hypertension is recommended. Ideally, CT assessment of the bilateral adrenal glands for further clarification is recommended if possible.

Correlation of the appearance of the pancreas with a Spec cPL could be considered.
Hepatosupportive medications including Denamarin and Ursodiol may prove beneficial.

IMAGING PERFORMED BY

SVS IMAGING

SonoPath
Clinical Sonography & Telecytology
EDUCATIONAL TELECONSULTATION SERVICES™
1-800-838-4288 info@sonopath.com SonoPath.com

PATIENT

Genno Hahn

SPECIES

Canine

BREED

Jack Russell Terrier Mix

SEX

MN

AGE

12 years

WEIGHT

21 lbs

INTERPRETED BY

R. McKenzie Daniel, DVM, DABVP (Canine and Feline)

IMAGING PERFORMED BY

Sarah Pender, CVT

HOSPITAL NAME

SVS Imaging QC

REFERRING VET

Dr. Barbara Shields

INVOICE

13284

DATE

2/9/22

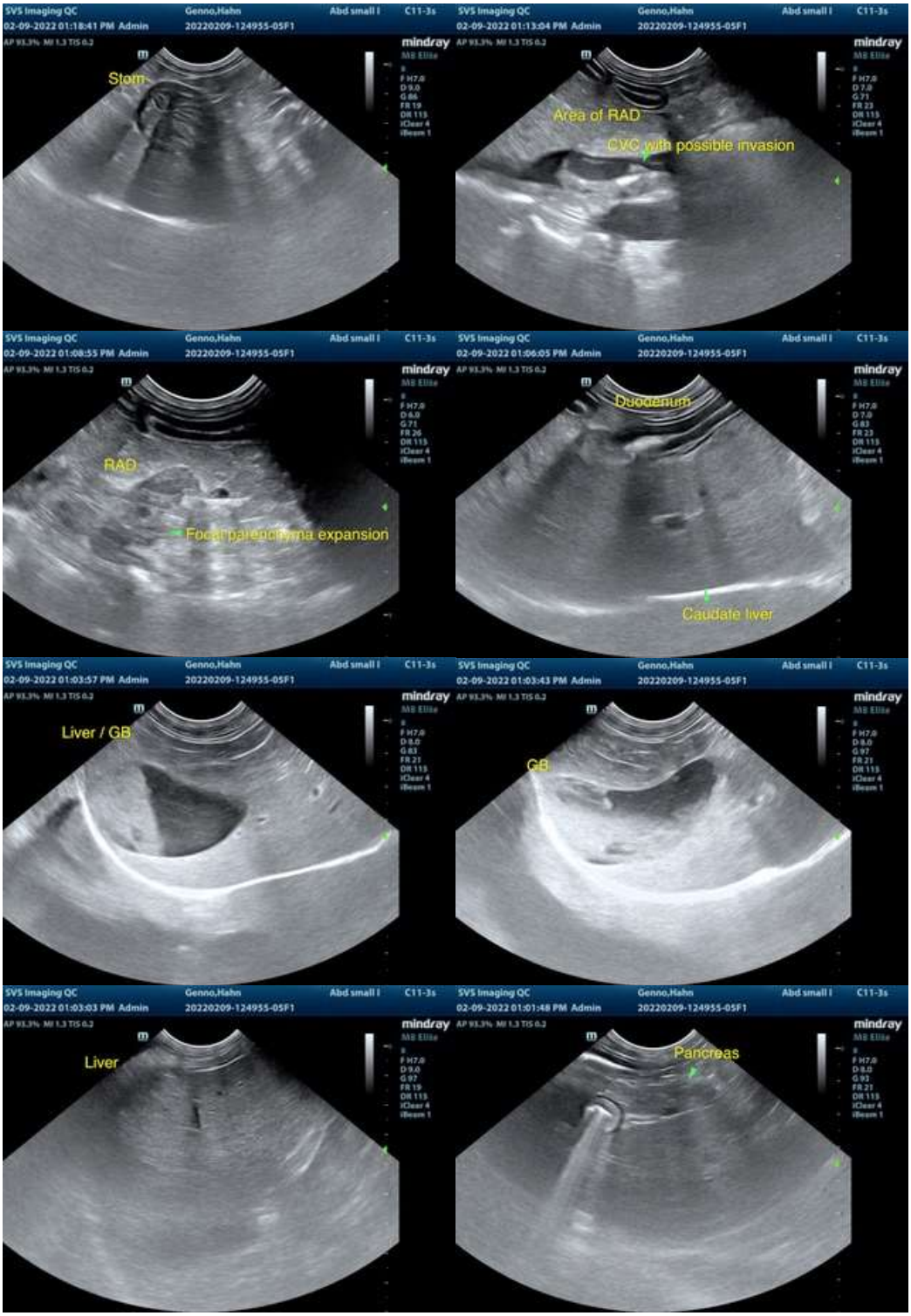

IMAGING PERFORMED BY

SVS IMAGING

SonoPath
Clinical Sonography & Telecytology
EDUCATIONAL TELECONSULTATION SERVICES™
1-800-838-4268 info@sonopath.com SonoPath.com

PATIENT

Genno Hahn

SPECIES

Canine

BREED

Jack Russell Terrier Mix

SEX

MN

AGE

12 years

WEIGHT

21 lbs

INTERPRETED BY

R. McKenzie Daniel, DVM, DABVP (Canine and Feline)

IMAGING PERFORMED BY

Sarah Pender, CVT

HOSPITAL NAME

SVS Imaging QC

REFERRING VET

Dr. Barbara Shields

INVOICE

13284

DATE

2/9/22

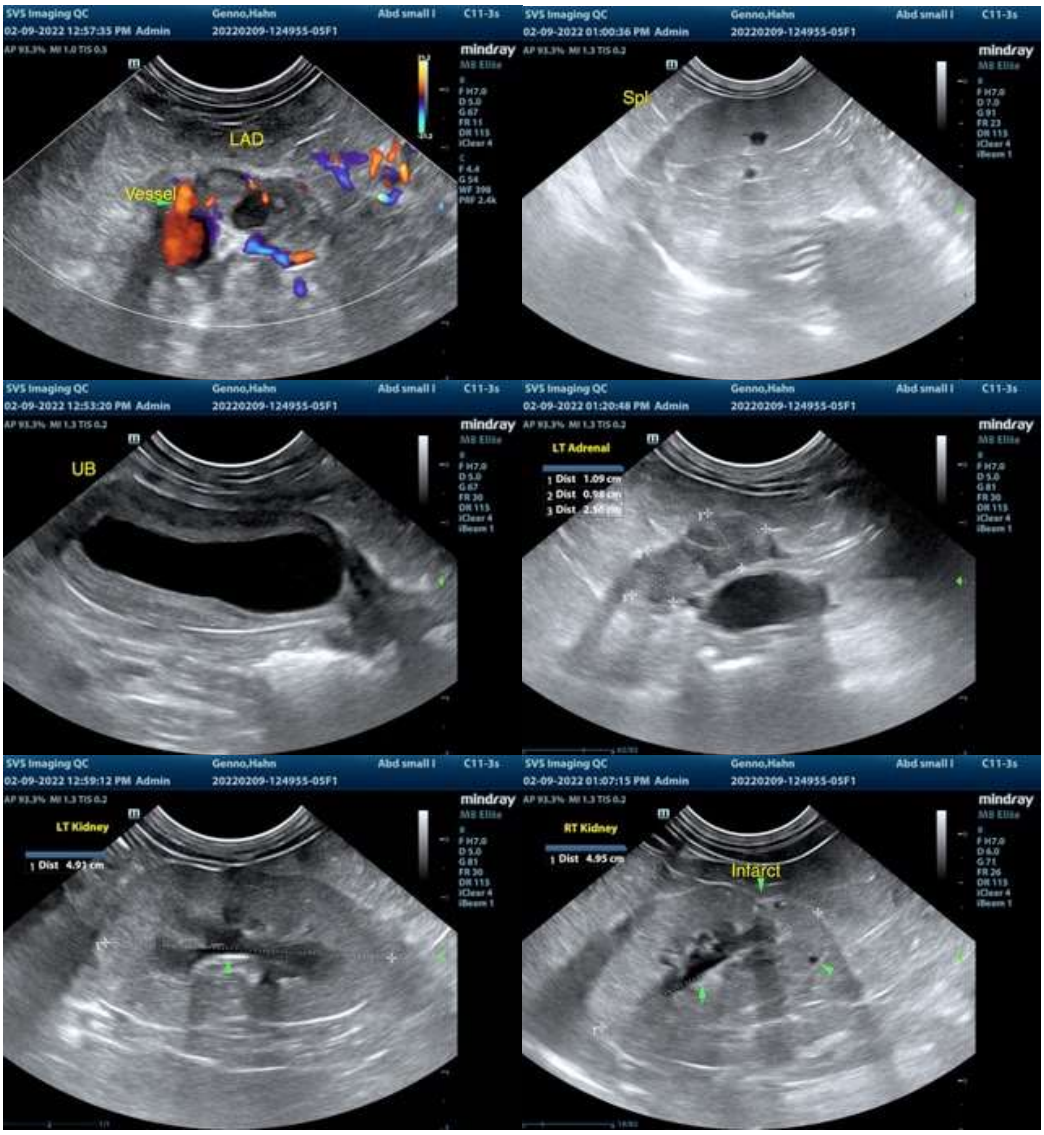

The information and recommendations provided are based on the images presented by the referring veterinarian/sonographer. No evaluation can be communicated regarding pathology that was not visible in the image/video clips provided.

Thank you for this referral. If the clinical or image interpretation does not parallel your findings or if I can be of any further assistance please contact me.

R. McKenzie Daniel, DVM, DABVP (Canine / Feline Practice)
info@SonoPath.com