



PATIENT PRESENTING CLINICAL SIGNS

Mason Ettinger History: Decreased appetite on routine exam, 2/6 heart murmur, concern for abdominal bleed
ALP 627, HCT 21, Platelets 79, WBC 19.1

SPECIES ULTRASONOGRAPHIC EXAMINATION OF THE ABDOMEN

Canine **Urinary System**

BREED The urinary bladder, trigone, cystourethral junction, and visible pelvic urethra to a depth of 4.0 cm exhibited normal thickness and tone. Anechoic urine was present in the lumen with no uroliths or sediment. The ureteral papillae were normal. The ureters were not visible which is normal. No evidence of inflammatory or neoplastic changes was noted.

SEX No overt pathology was noted in the area of the residual prostate. The residual prostate measured 1.0 cm in diameter.

AGE The area of the aortic trifurcation was free of pathology.

11 years Normal size and margination were present in the kidneys. A normal 1:3 cortex / medulla ratio and normal corticomedullary definition were maintained. The echogenicity of the cortex was similar to or slightly less than normal liver parenchyma while the medulla echogenicity was hypoechoic to the cortex with no evidence of pelvic dilation. The left kidney measured 4.9 cm in length. The right kidney measured 5.0 cm in length.

WEIGHT 23 Pounds

Adrenal Glands

The left adrenal gland was uniform in size and contour with a uniformly hypoechoic parenchyma. The left adrenal gland measured 0.45 cm width at the caudal pole and 0.43 cm width at the cranial pole. The right adrenal gland was uniform in size and contour with a uniformly hypoechoic parenchyma. The right adrenal gland measured 0.33 cm width at the caudal pole and 0.51 cm width at the cranial pole.

INTERPRETED BY

R. McKenzie Daniel,
DVM, DABVP
(Canine and Feline)

IMAGING PERFORMED BY

Rebekah Jakum, CVT
ARDMS/RVT

HOSPITAL NAME

Blue Ridge VC

REFERRING VET

Dr. Filchner

Spleen

The spleen exhibited primarily finely textured parenchyma which was hyperechoic to the liver and renal cortical parenchyma. Mild generalized parenchyma heterogeneity was present without evidence of nodular changes. The capsule was smooth and regular without apparent expansion. The splenic vasculature at the hilus was normal in volume with no evidence of congestion or thrombosis. The parenchymal heterogeneity is likely consistent with benign changes such as extramedullary hematopoiesis or age-related remodeling with minor potential for inflammatory or neoplastic disease. No splenic masses or nodules were noted.

Liver/ Gallbladder

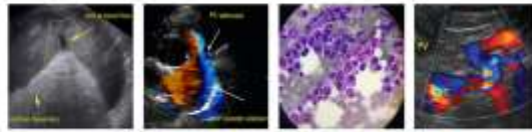
The liver exhibited generalized enlargement primarily owing to multiple, expansive, nonhomogeneous to cavitated masses. A mass present in the caudoventral mid liver measured approximately 5.0-6.0 cm in diameter with a larger, expansive mass present in the right lateral liver measuring approximately 8.0-9.0 cm in diameter. Moderate, nondependent yet nonorganized gallbladder debris was present. The cystic and common bile ducts were normal.

INVOICE

13258

DATE

2.8.2022



PATIENT

Mason Ettinger

Gastrointestinal

The stomach presented intact wall layering with a normal wall layer ratio. The lumen of the stomach was empty with no signs of ileus, obstruction, or foreign material. The gastric body wall with measured 0.25 cm.

SPECIES

Canine

The small intestine presented intact wall layering with 1:3 muscularis/mucosa ratio. The lumen of the small intestine was empty with no signs of ileus, obstruction, or foreign material. The duodenum wall width measured 0.49 cm.

BREED

Westie

Normal visible colon wall layers were present with apparent formed feces in lumen.

SEX

Pancreas

Neutered Male

The parenchyma of the left limb, body, and right limb of the pancreas presented isoechoic to the adjacent omental fat. A normal curvilinear capsule contour of the pancreas was present. The visible pancreatic duct was normal. No signs of active inflammation or neoplastic disease were evident.

AGE

11 years

Free Abdomen

No overt evidence of peritoneal effusion suggestive of hepatic mass rupture or intraabdominal hemorrhage was present. Mild evidence of perihepatic reactive mesentery primarily around the hepatic masses was present.

WEIGHT

23 Pounds

ULTRASONOGRAPHIC FINDINGS

INTERPRETED BY

Primary Findings

R. McKenzie Daniel,
 DVM, DABVP
 (Canine and Feline)

- Nonhomogeneous to cavitated hepatic masses
- Mild gallbladder debris (non-mucocele)
- Sonographically unremarkable gastrointestinal tract
- Mild age-related spleen - no overt neoplastic splenic criteria

IMAGING PERFORMED BY

Rebekah Jakum, CVT
 ARDMS/RVT

HOSPITAL NAME

Blue Ridge VC

INTERPRETATION OF THE FINDINGS & FURTHER RECOMMENDATIONS

Although sampling is required for further clarification, the hepatic masses are consistent with neoplastic criteria. Assuming normal clotting status, ultrasound guided FNA of a hepatic mass could be considered for screening cytology with potential for oncology consultation.

REFERRING VET

Dr. Filchner

The large mass in the right lateral liver subjectively does not appear to be amendable to complete surgical resection, given its potential involvement of more than one liver lobe and location adjacent to the porta hepatis.

INVOICE

13258

As-needed gastrointestinal support is recommended. Three view chest radiographs may be considered for further staging.

DATE

2.8.2022



PATIENT

Mason Ettinger

SPECIES

Canine

BREED

Westie

SEX

Neutered Male

AGE

11 years

WEIGHT

23 Pounds

INTERPRETED BY

R. McKenzie Daniel,
DVM, DABVP
(Canine and Feline)

IMAGING PERFORMED BY

Rebekah Jakum, CVT
ARDMS/RVT

HOSPITAL NAME

Blue Ridge VC

REFERRING VET

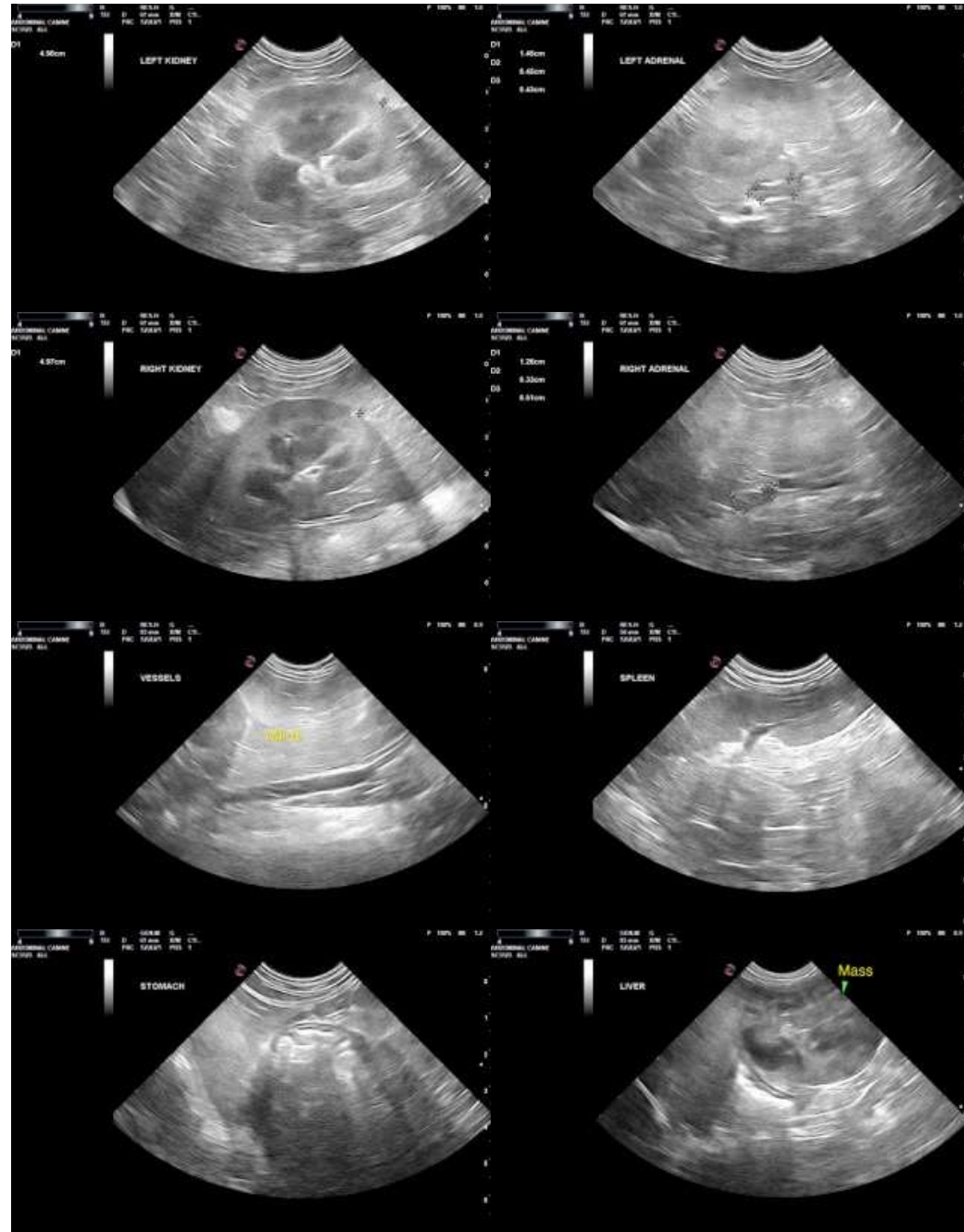
Dr. Filchner

INVOICE

13258

DATE

2.8.2022





PATIENT

Mason Ettinger

SPECIES

Canine

BREED

Westie

SEX

Neutered Male

AGE

11 years

WEIGHT

23 Pounds

INTERPRETED BY

R. McKenzie Daniel,
DVM, DABVP
(Canine and Feline)

**IMAGING
PERFORMED BY**

Rebekah Jakum, CVT
ARDMS/RVT

HOSPITAL NAME

Blue Ridge VC

REFERRING VET

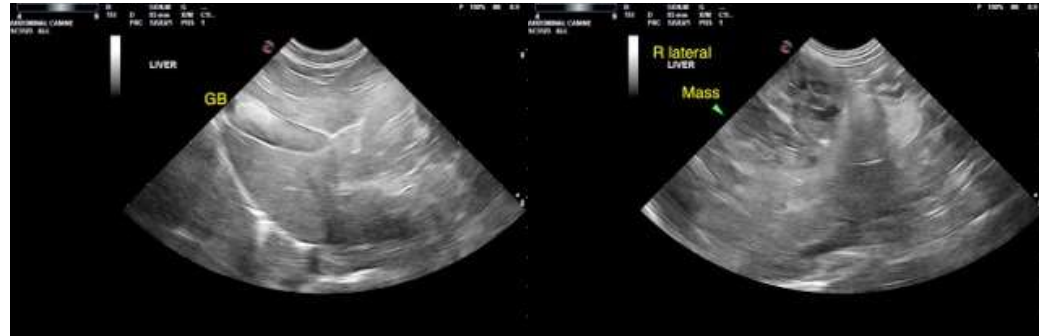Dr. Filchner

INVOICE

13258

DATE

2.8.2022



The information and recommendations provided are based on the images presented by the referring veterinarian. No evaluation can be communicated regarding pathology that was not visible in the image/video clips provided.

Thank you for this referral. If the clinical or image interpretation does not parallel your findings or if I can be of any further assistance please contact me.

R. McKenzie Daniel, DVM, DABVP (Canine/Feline Practice)
mac.daniel@sonopath.com