

PATIENT

Champ Clark

SPECIES

Canine

BREED

Great Pyrenees/Border Collie

SEX

MN

AGE

6 years

WEIGHT

81 lbs.

INTERPRETED BY

R. McKenzie Daniel,
DVM, DABVP
(Canine and Feline)

IMAGING PERFORMED BY

Jenna Walsh, CVT

HOSPITAL NAME

Albany AH

REFERRING VET

Dr. Spangler

INVOICE

13275

DATE

2/8/22

PRESENTING CLINICAL SIGNS

Great Pyrenees/Border Collie

History: Anorexia Lethargy NSF on PE Current Medications buprenorphine, cerenia

Abnormal PE/Chem/CBC/UA Results: Azotemia - creatinine 4.7, BUN 55 USG 1.012

ULTRASONOGRAPHIC EXAMINATION OF THE ABDOMEN

Urinary System

The urinary bladder, trigone, cystourethral junction, and visible pelvic urethra to a depth of 3.0 cm exhibited normal thickness and tone. Anechoic urine was present in the lumen with no uroliths or sediment. The ureteral papillae were normal. The ureters were not visible which is normal. No evidence of inflammatory or neoplastic changes was noted.

The residual prostate was free of pathology.

The area of the aortic trifurcation was free of pathology.

Normal to possible subnormal renal size with asymmetrical contour were present in both kidneys. Marked, nonuniform echogenic cortical hypertrophy was present. Severe loss of medullary volume was noted. Severe loss of corticomedullary border demarcation was also present. Both kidneys exhibited mild pyelectasia along with thinly walled cortical cysts containing anechoic fluid. The left kidney measured 6.5 cm in length. The right kidney measured 6.7 cm in length.

Adrenal Glands

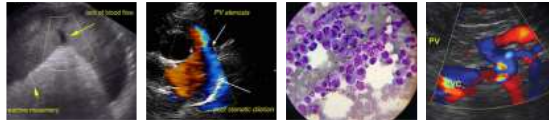
The left adrenal gland was uniform in size and contour with a uniformly hypoechoic parenchyma. The left adrenal gland measured 2.75 cm length x 0.62 cm width at the caudal pole. The right adrenal gland was uniform in size and contour with a uniformly hypoechoic parenchyma. The right adrenal gland measured 2.5 cm length x 0.88 cm width at the caudal pole.

Spleen

The spleen exhibited a finely textured and homogenous parenchyma which was hyperechoic to the liver and renal cortical parenchyma. The capsule was smooth and regular without apparent expansion. The splenic vasculature at the hilus was normal in volume with no evidence of congestion or thrombosis. Acute to chronic inflammatory, neoplastic, or benign parenchyma changes were not noted.

Liver/ Gallbladder

The liver was subjectively normal in size, structure, and contour. The liver parenchyma was uniform and hypoechoic to the spleen with a mild coarse echotexture. The hepatic and portal vasculature were normal in appearance without signs of congestion. The gallbladder was non-distended in size with mild gallbladder debris. The cystic and common bile ducts were normal.



PATIENT

Gastrointestinal

Champ Clark

The stomach presented mild wall thickening secondary to mild echogenic mucosa hypertrophy. Intact wall layering was maintained and distinct. Mild gastric distension with primarily anechoic fluid was present.

SPECIES

Canine

The small intestine presented intact wall layering with 1:3 muscularis/mucosa ratio. The lumen of the small intestine was empty with no signs of ileus, obstruction, or foreign material.

BREED

Great Pyrenees/Border Collie

Normal visible colon wall layers were present with apparent formed feces in lumen.

SEX

MN

Pancreas

The parenchyma of the left limb, body, and right limb of the pancreas presented isoechoic to the adjacent omental fat. A normal curvilinear capsule contour of the pancreas was present. The visible pancreatic duct was normal. No signs of active inflammation or neoplastic disease were evident.

AGE

6 years

Free Abdomen

No overt lymphadenopathy or peritoneal effusion was present.

WEIGHT

81 lbs.

ULTRASONOGRAPHIC FINDINGS

Primary Findings

- Bilateral marked chronic nephropathy exhibiting nonhomogeneous hyperechoic cortical hypertrophy, significant reduced medullary volume, and bilateral mild pyelectasia
- Mild gastroenteritis

INTERPRETED BY

R. McKenzie Daniel,
DVM, DABVP
(Canine and Feline)

INTERPRETATION OF THE FINDINGS & FURTHER RECOMMENDATIONS

The appearance of the bilateral kidneys is consistent with chronic progressive to severe nephropathy as opposed to acute kidney injury or acute renal insult. Considerations may include the potential for renal dysplasia, given the relatively young age of the patient, nonspecific chronic to progressive nephritis such as glomerulonephritis, interstitial nephritis, or other. Renal biopsy would be required for a definitive diagnosis yet may further compromise renal function. Further renal staging to include urine C/S and protein: creatinine ratio on sterile urine sample may be considered. Neoplastic renal criteria is considered an unlikely differential diagnosis.

IMAGING PERFORMED BY

Jenna Walsh, CVT

HOSPITAL NAME

Albany AH

REFERRING VET

Dr. Spangler

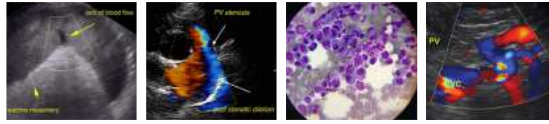
Without evidence of additional abdominal visceral pathology, the clinical signs in this patient are suspected to be owing to renal disease. Hospitalization with IV fluid therapy, with monitoring of urine output, body weight, and renal response with as-needed gastrointestinal support is recommended. A guarded prognosis is warranted.

INVOICE

13275

DATE

2/8/22



PATIENT

Champ Clark

SPECIES

Canine

BREED

Great Pyrenees/Border Collie

SEX

MN

AGE

6 years

WEIGHT

81 lbs.

INTERPRETED BY

R. McKenzie Daniel,
DVM, DABVP
(Canine and Feline)

IMAGING PERFORMED BY

Jenna Walsh, CVT

HOSPITAL NAME

Albany AH

REFERRING VET

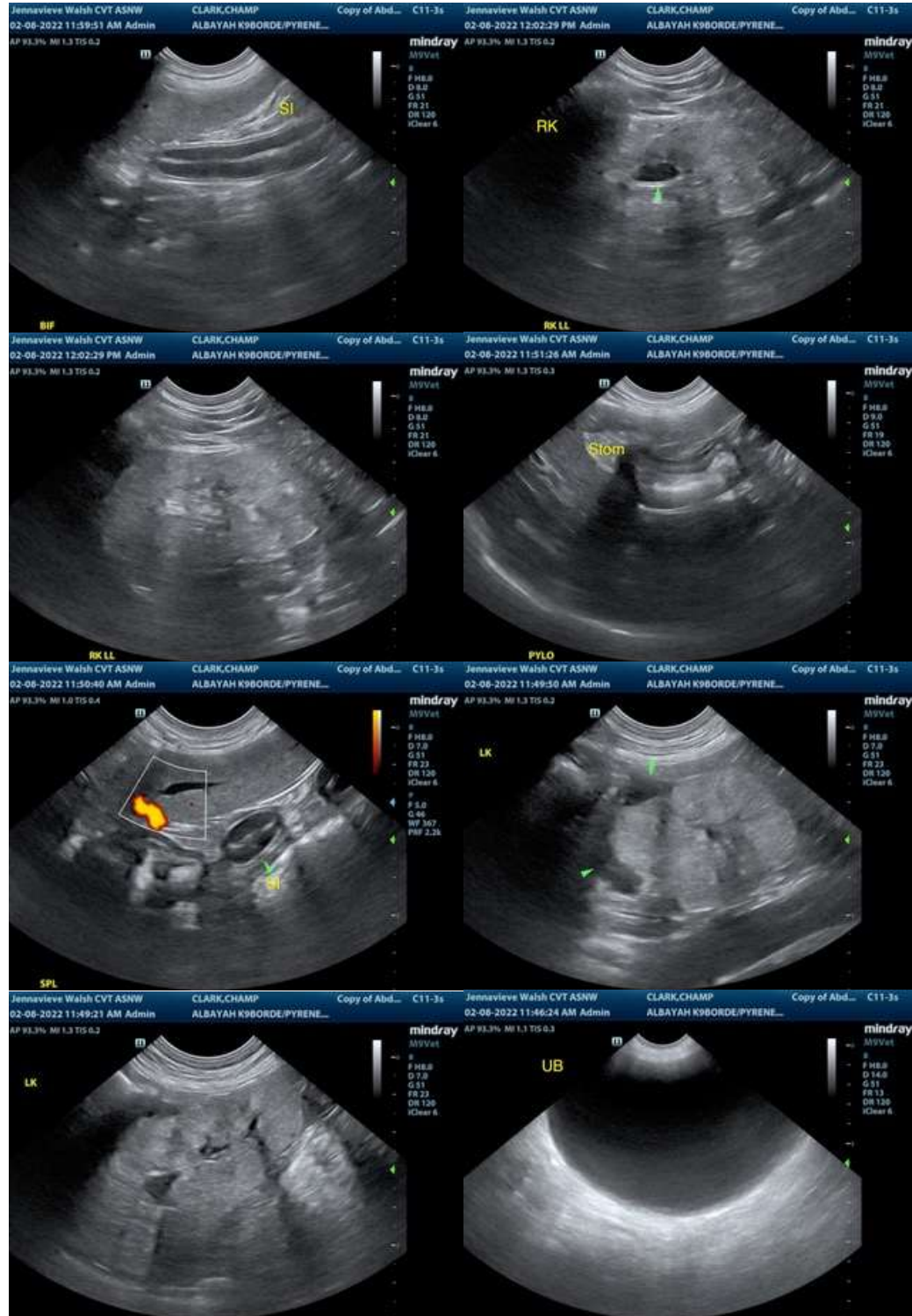
Dr. Spangler

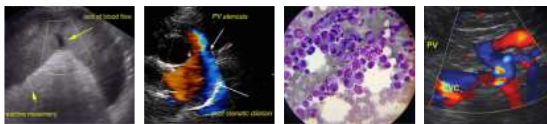
INVOICE

13275

DATE

2/8/22





PATIENT

Champ Clark

SPECIES

Canine

BREED

Great Pyrenees/Border Collie

SEX

MN

AGE

6 years

WEIGHT

81 lbs.

INTERPRETED BY

R. McKenzie Daniel,
DVM, DABVP
(Canine and Feline)

IMAGING PERFORMED BY

Jenna Walsh, CVT

HOSPITAL NAME

Albany AH

REFERRING VET

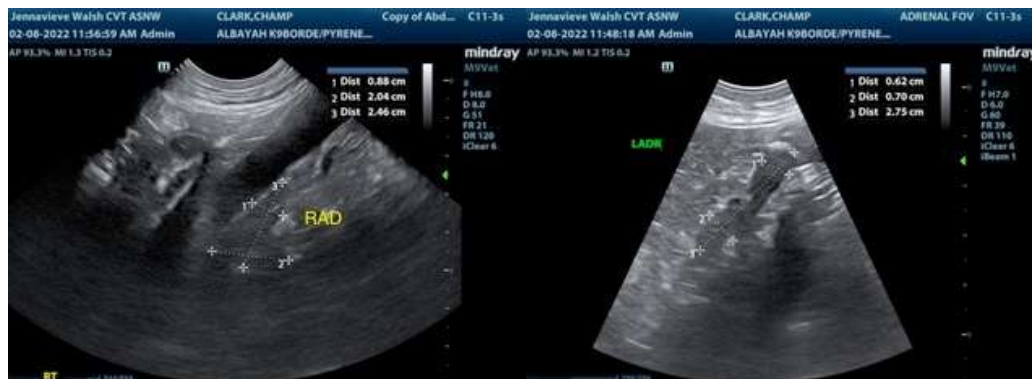Dr. Spangler

INVOICE

13275

DATE

2/8/22



The information and recommendations provided are based on the images presented by the referring veterinarian/sonographer. No evaluation can be communicated regarding pathology that was not visible in the image/video clips provided.

Thank you for this referral. If the clinical or image interpretation does not parallel your findings or if I can be of any further assistance please contact me.

R. McKenzie Daniel, DVM, DABVP (Canine / Feline Practice)
info@SonoPath.com