

**PATIENT**

Luci Shaw

**SPECIES**

Feline

**BREED**

DSH

**SEX**

FS

**AGE**

8yr

**WEIGHT**

7.6kg

**INTERPRETED BY**R. McKenzie Daniel,  
DVM, DABVP  
(Canine and Feline)**IMAGING PERFORMED BY**

Tom McNeill

**HOSPITAL NAME**

SVS Imaging CT

**REFERRING VET**Madison Veterinary  
Specialists Dr. Patton**INVOICE**

12924ag

**DATE**

02/07/2023

**PRESENTING CLINICAL SIGNS**

Luci presented to the MVS Emergency Service on Feb 07, 2023, at 11am, for evaluation of transfer for possible foreign body. About 1 week ago, Luci began having diarrhea and refusing to eat kibble. The next day, she continued to refuse food and produced a string-like stool. Since then her appetite has almost returned to normal, but she continued to have diarrhea. Luci was evaluated by her pcDVM on Monday. They took an x-ray and believed she had a foreign body. They instructed Luci's owner to feed her a large amount of food, in hopes that she could pass it on her own. She represented to her pcDVM again today, since she is still having diarrhea. They took another x-ray, which showed no changes from Monday. They recommended further evaluation at an emergency clinic. She has a history of anal gland issues and a sensitive stomach. Luci is an indoor only cat.

Abnormal PE/Chem/CBC/UA Results: BG - 196 mg/dl BUN - 15 mg/dl EOS - 2,400 (170-1,570)  
Baso - 600 (100-260)

**ULTRASONOGRAPHIC EXAMINATION OF THE ABDOMEN****Urinary System**

The urinary bladder, trigone, cystourethral junction, and visible pelvic urethra to a depth of 2 cm exhibited normal thickness and tone. Anechoic urine was present in the lumen with very minor particulate sediment. The sediment may indicate cellular debris / protein, crystalline debris, lipid, or mucus and is likely incidental. The ureteral papillae were normal. The ureters were not visible which is normal. No evidence of inflammatory or neoplastic changes were noted.

Normal size and margination were present in the kidneys. A normal 1:3 cortex / medulla ratio and normal corticomedullary definition were maintained. The echogenicity of the cortex was similar to or slightly less than normal liver parenchyma while the medulla echogenicity was hypoechoic to the cortex with no evidence of pelvic dilation. The left kidney measured 3.9 cm in length. The right kidney measured 4.1 cm in length.

The area of the aortic trifurcation was free of pathology.

**Adrenal Glands**

The left adrenal gland was uniform in size and contour with a uniformly hypoechoic parenchyma. The left adrenal gland measured 0.28 cm width. The right adrenal gland was uniform in size and contour with a uniformly hypoechoic parenchyma. The right adrenal gland measured 0.43 cm width.

**Spleen**

The spleen exhibited a finely textured and homogenous parenchyma which was hyperechoic to the liver and renal cortical parenchyma. The capsule was smooth and regular without apparent expansion. The splenic vasculature at the hilus was normal in volume with no evidence of congestion or thrombosis. Acute to chronic inflammatory, neoplastic, or benign parenchyma changes were not noted. The spleen measured 0.78 cm in width at the level of the hilus.

**Liver/Gallbladder**

The liver was subjectively normal in size, structure, and contour. The liver parenchyma was uniform and hypoechoic to the spleen with a mild coarse echotexture. The hepatic and portal vasculature were normal in appearance without signs of congestion. The gallbladder was non-distended in size with thin walls and primarily anechoic luminal content. The cystic and common bile ducts were normal.

**Gastrointestinal**

**PATIENT**

Luci Shaw

The stomach presented intact wall layering with mild prominent to hyperechoic gastric submucosa. The lumen of the stomach was empty with no signs of ileus, obstruction or foreign material. The ventral gastric body wall measured 0.27 cm in width.

**SPECIES**

Feline

The duodenum exhibited intact wall layering measuring 0.24 cm in wall width containing minor chyme. The jejunum and ileum to the level of the ileocolic junction exhibited intact mildly prominent to thickened muscularis layer. The jejunum wall measured 0.33 cm in width. The ileocolic wall measured 0.30 cm in width. small intestine presented intact wall layering with 1:3 muscularis/mucosa ratio. No evidence of loss of wall layering or masses.

**BREED**

DSH

Normal visible colon wall layers were present with apparent formed feces in lumen and mild gas distension.

***Pancreas*****SEX**

FS

The parenchyma of the left limb, body and right limb of the pancreas presented isoechoic to the adjacent omental fat. A normal curvilinear capsule contour of the pancreas was present. The visible pancreatic duct was normal. No signs of active inflammation or neoplastic disease was evident.

**AGE**

8yr

***Free Abdomen***

A very scant pocket of peritoneal free fluid was present in the left lateral abdomen, likely incidental.

**WEIGHT**

7.6kg

Intermittent discrete mildly prominent to enlarged mesenteric lymph nodes were present. The lymph nodes were essentially isoechoic to adjacent omentum without evidence of peripheral inflammation and maintaining a normal width: length ratio (<0.5). An example of a lymph node measured 2.3 cm x 0.41 cm. This finding is considered incidental and is not consistent with inflammatory or neoplastic criteria.

**ULTRASONOGRAPHIC FINDINGS****INTERPRETED BY**

R. McKenzie Daniel,  
DVM, DABVP  
(Canine and Feline)

- Empty stomach-no evidence of retained gastric ingesta or foreign material
- IBD intestinal pattern with prominent jejunoileal muscularis-no evidence of intestinal obstructive pattern or definitive foreign material
- Sonographically normal pancreas
- Intermittent minor benign mesenteric lymph nodes
- Scant pocket of peritoneal free fluid-suspect incidental

**IMAGING PERFORMED BY**

Tom McNeill

**INTERPRETATION OF THE FINDINGS & FURTHER RECOMMENDATIONS****HOSPITAL NAME**

SVS Imaging CT

The intestinal presentation is consistent with infiltrative enteropathy i.e., IBD or eosinophilic enteritis. Minor potential for early neoplastic enteropathy with round cells possible yet thought less likely. No indication for immediate surgical intervention. Full thickness intestinal biopsies would be required for a definitive diagnosis. A GI panel to include PLI/TLI/Cobalamin/Folate is recommended.

**REFERRING VET**

Madison Veterinary  
Specialists Dr. Patton

Empirically IBD protocol to include a limited antigen or hydrolyzed diet trial with potential long term dietary therapy, cobalamin supplementation, high colony count probiotic (Proviale or Visbiome), +/- prednisolone trial at lowest effective dose and as needed gastrointestinal support with assessment of clinical response may prove beneficial. Sonographic monitoring of the small intestine and mesenteric lymph nodes for evidence of progressive changes is ideal.

**INVOICE**

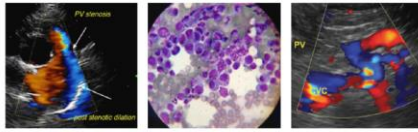
12924ag

**DATE**

02/07/2023

IMAGING PERFORMED BY

SVS Mobile Imaging CT 262-366-5970  
fredgromalak@gmail.com



Clinical Sonography & Telecytology

EDUCATIONAL TELECONSULTATION SERVICES™

1-800-838-4268 info@sonopath.com SonoPath.com

PATIENT

Luci Shaw

SPECIES

Feline

BREED

DSH

SEX

FS

AGE

8yr

WEIGHT

7.6kg

INTERPRETED BY

R. McKenzie Daniel,  
DVM, DABVP  
(Canine and Feline)

IMAGING PERFORMED BY

Tom McNeill

HOSPITAL NAME

SVS Imaging CT

REFERRING VET

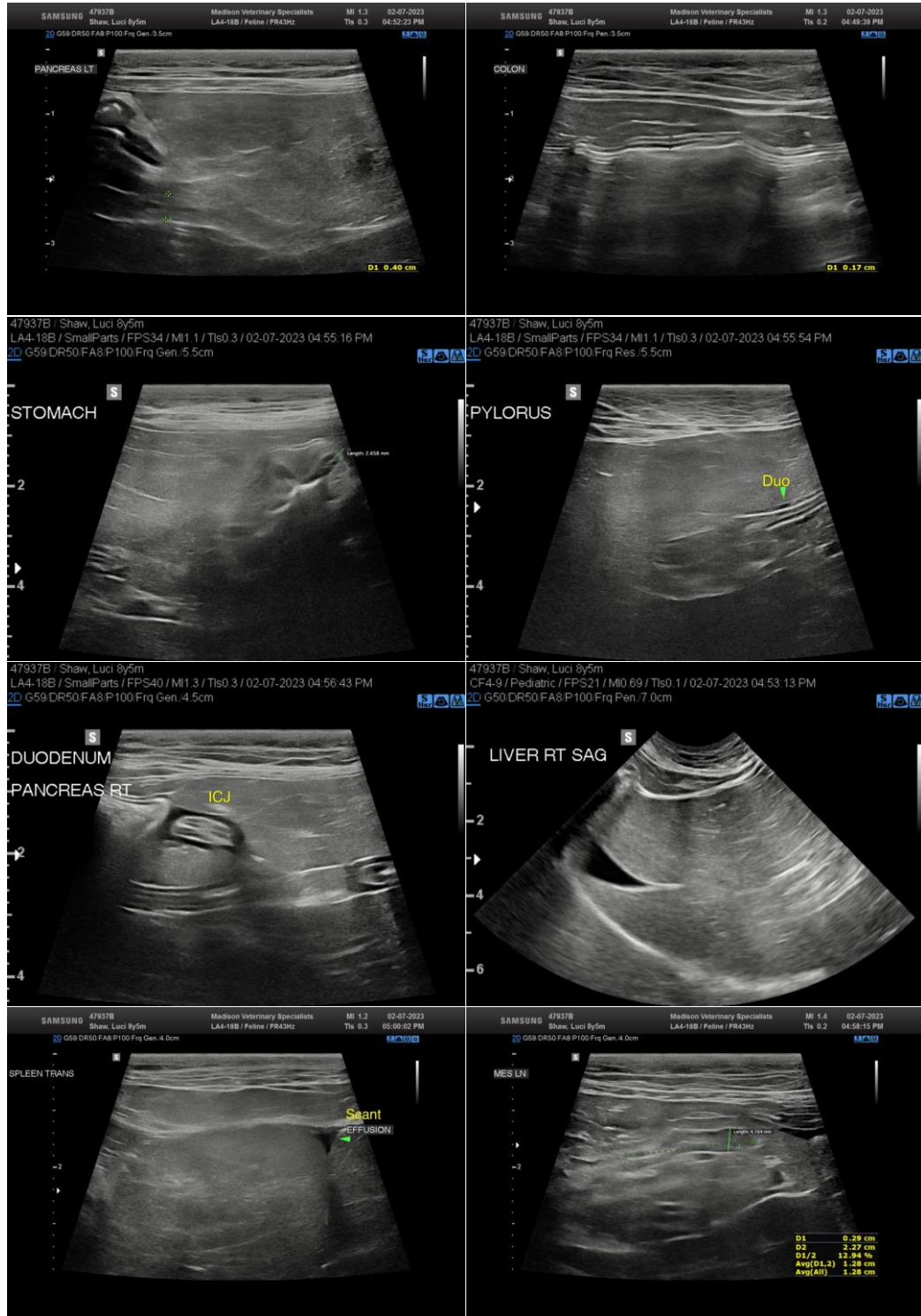
Madison Veterinary  
Specialists Dr. Patton

INVOICE

12924ag

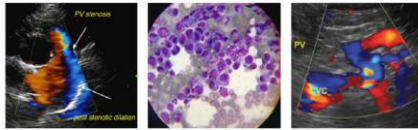
DATE

02/07/2023



**IMAGING PERFORMED BY**

SVS Mobile Imaging CT 262-366-5970  
fredgromalak@gmail.com



**Clinical Sonography & Telectology**

EDUCATIONAL TELECONSULTATION SERVICES™

1-800-838-4268 info@sonopath.com SonoPath.com

**PATIENT**

Luci Shaw

**SPECIES**

Feline

**BREED**

DSH

**SEX**

FS

**AGE**

8yr

**WEIGHT**

7.6kg

**INTERPRETED BY**

R. McKenzie Daniel,  
DVM, DABVP  
(Canine and Feline)

**IMAGING PERFORMED BY**

Tom McNeill

**HOSPITAL NAME**

SVS Imaging CT

**REFERRING VET**

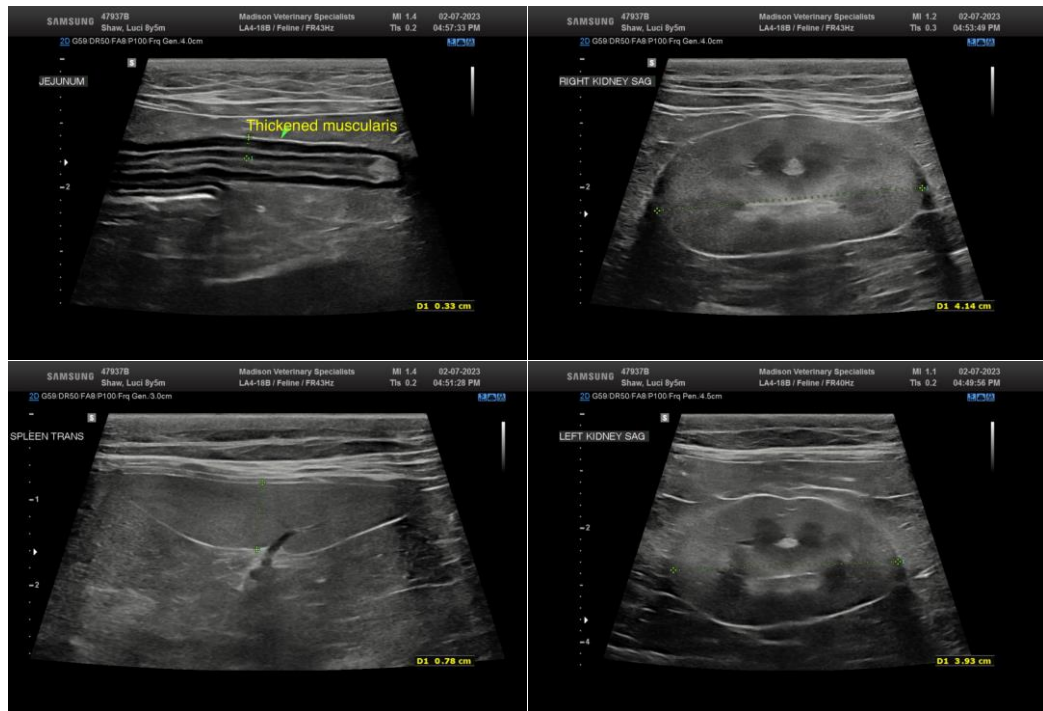
Madison Veterinary  
Specialists Dr. Patton

**INVOICE**

12924ag

**DATE**

02/07/2023



The information and recommendations provided are based on the images presented by the referring veterinarian/sonographer. No evaluation can be communicated regarding pathology that was not visible in the image/video clips provided.

Thank you for this referral. If the clinical or image interpretation does not parallel your findings or if I can be of any further assistance please contact me.

R. McKenzie Daniel, DVM, DABVP (Canine / Feline Practice)

info@SonoPath.com