

PATIENT PRESENTING CLINICAL SIGNS

Max Pop History: 1 year duration increased BUN/Creatinine, recent further increase. Last Feb negative urine culture. Neg 4dx Lepto antibody test. Unrelated grade 1-2 heart murmur, previously diagnosed with subaortic stenosis. 40mg Telmisartan every 24 hours(have slowly increased to this dose)

SPECIES

Canine

BREED

Entlebucher

Abnormal PE/Chem/CBC/UA Results: RBCs, Hematocrit, Hemoglobin low. SDMA elevation 47(0-14), Creatinine 335(44-159), Urea 27.1(2.5-9.6), mild elevation in ALT, ALP, GGT, Total Bilirubin. Amylase elevated at 1589(500-1500), T4 low normal. Urine creatinine 9216, urine protein 362, urine protein/creatinine ratio 3.5. U/A - pH 6, protein 3+, blood 2+, Sp gravity 1.021. Repeat urine culture collected today.

SEX

Neutered Male

AGE

6.5 Years

ULTRASONOGRAPHIC EXAMINATION OF THE ABDOMEN

Urinary System

The urinary bladder, trigone, cystourethral junction, and visible pelvic urethra to a depth of 3.0 cm exhibited normal thickness and tone. Anechoic urine was present in the lumen with no uroliths or sediment. The ureteral papillae were normal. The ureters were not visible which is normal. No evidence of inflammatory or neoplastic changes were noted.

The area of the residual prostate appeared normal and free of pathology.

WEIGHT

23.3 kg

The area of the aortic trifurcation was free of pathology.

Both kidneys were normal in size and overall margination. Mild loss of corticomedullary border demarcation noted in both kidneys. Mild pyelectasia was present in the left kidney. The left kidney measured 4.6 cm in length. A focal caudolateral cortical infarct was present in the right kidney. The right kidney measured 5.7 cm in length.

INTERPRETED BY

R. McKenzie Daniel, DVM,
DABVP (Canine and
Feline)

Adrenal Glands

The left adrenal gland was uniform in size and contour with a uniformly hypoechoic parenchyma. The left adrenal gland measured 0.61 cm width at the caudal pole and 0.68 cm width at the cranial pole.

IMAGING

PERFORMED BY

Crystal Hill

The right adrenal gland was uniform in size and contour with a uniformly hypoechoic parenchyma. The right adrenal gland measured 0.38 cm width at the caudal pole.

HOSPITAL NAME

New Hamburg VC

Spleen

The spleen exhibited a finely textured and homogenous parenchyma which was hyperechoic to the liver and renal cortical parenchyma. The capsule was smooth and regular without apparent expansion. The splenic vasculature at the hilus was normal in volume with no evidence of congestion or thrombosis. Acute to chronic inflammatory, neoplastic, or benign parenchyma changes were not noted.

REFERRING VET

Schroeder

Liver

The liver was subjectively normal in size, structure, and contour. The liver parenchyma was uniform and hypoechoic to the spleen with a mild coarse echotexture. The hepatic and portal vasculature were normal in appearance without signs of congestion.

INVOICE

13841

DATE

2/7/22

The gallbladder was non distended in size with mild nondependent nonmineralized gallbladder debris. The cystic duct and common bile ducts were normal without evidence of dilation.

Gastrointestinal



PATIENT

The stomach presented intact wall layering with a normal wall layer ratio. The lumen of the stomach was empty with no signs of ileus, obstruction or foreign material.

Max Pop

The small intestine presented intact wall layering with 1:3 muscularis/mucosa ratio. The lumen of the small intestine was empty with no signs of ileus, obstruction or foreign material.

SPECIES

Canine

Normal visible colon wall layers were present with apparent formed feces in lumen.

Pancreas

BREED

Entlebucher

The parenchyma of the left limb, body and right limb of the pancreas presented isoechoic to the adjacent omental fat. A normal curvilinear capsule contour of the pancreas was present. The visible pancreatic duct was normal. No signs of active inflammation or neoplastic disease was evident.

SEX

ULTRASONOGRAPHIC FINDINGS

Neutered Male

Primary Findings

AGE

6.5 Years

- Bilateral chronic nephropathy with minor left kidney pyelectasia and focal right kidney cortical infarct
- Sonographically unremarkable urinary bladder
- Low-grade hepatopathy
- Mild gallbladder debris- incidental

WEIGHT

23.3 kg

Secondary Findings

INTERPRETED BY

INTERPRETATION OF THE FINDINGS & FURTHER RECOMMENDATIONS

R. McKenzie Daniel, DVM,
DABVP (Canine and
Feline)

The gallbladder debris may be secondary to fasting or indicate nonclinical cholestasis. Hepatosupportive medications and ursodiol, if increasing evidence of cholestasis recommended.

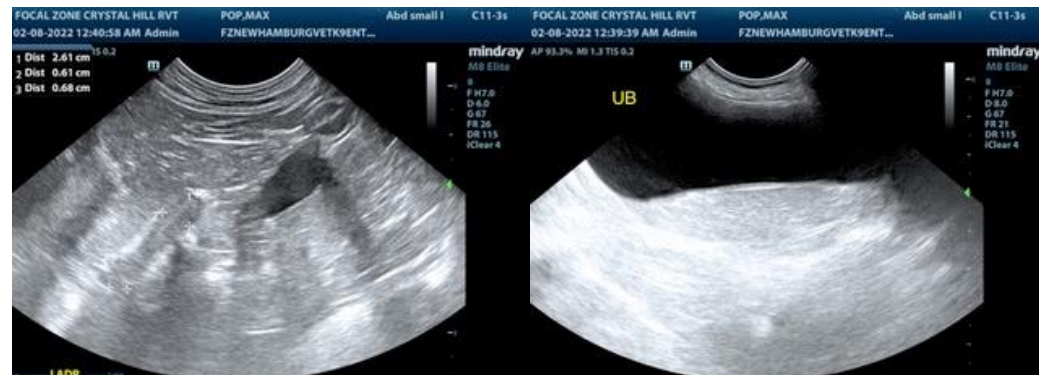
IMAGING PERFORMED BY

Crystal Hill

Given the elevated UPC, in the face of quiet urinary bladder sediment, chronic glomerulopathy such as nonspecific glomerulonephritis is likely. No overt evidence of renal dysplasia. Continued therapy for CKD and glomerulonephritis, pending recheck urine culture and sensitivity recommended. Periodic monitoring of blood pressure would be ideal. Renal biopsy would be required for a definitive diagnosis.

HOSPITAL NAME

New Hamburg VC



REFERRING VET

Schroeder

INVOICE

13841

DATE

2/7/22



PATIENT

Max Pop

SPECIES

Canine

BREED

Entlebucher

SEX

Neutered Male

AGE

6.5 Years

WEIGHT

23.3 kg

INTERPRETED BY

R. McKenzie Daniel, DVM,
DABVP (Canine and
Feline)

**IMAGING
PERFORMED BY**

Crystal Hill

HOSPITAL NAME

New Hamburg VC

REFERRING VET

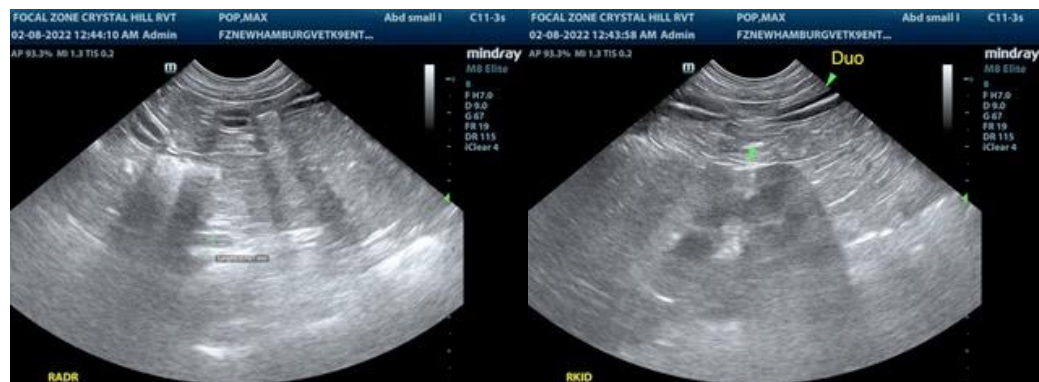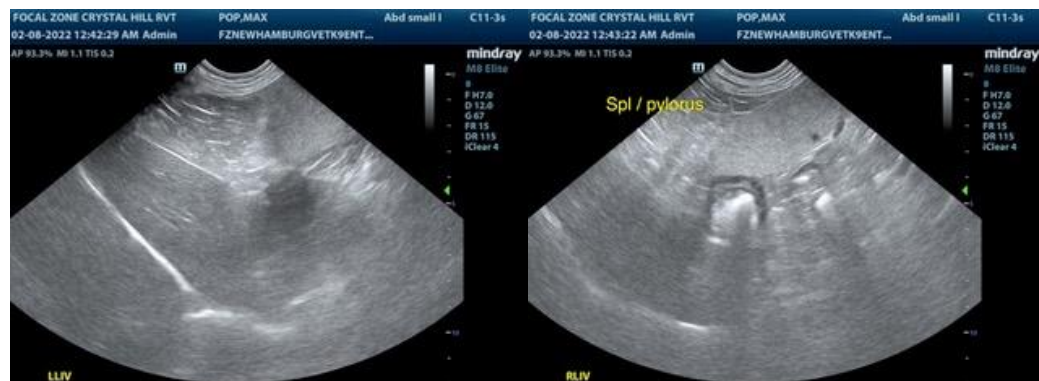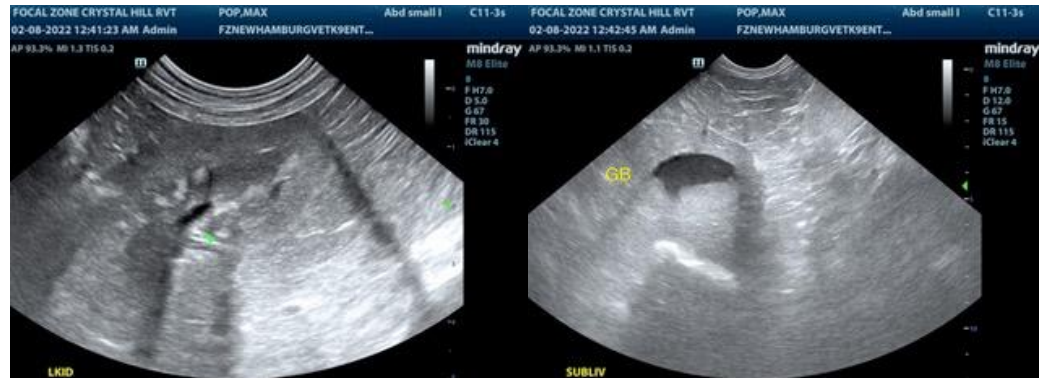Schroeder

INVOICE

13841

DATE

2/7/22

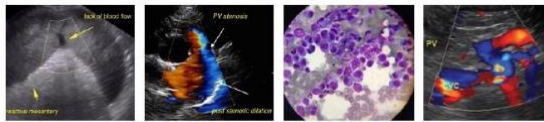


The information and recommendations provided are based on the images presented by the referring veterinarian. No evaluation can be communicated regarding pathology that was not visible in the image/video clips provided.

Thank you for this referral. If the clinical or image interpretation does not parallel your findings or if I can be of any further assistance please contact me.

R. McKenzie Daniel, DVM, DABVP (Canine / Feline Practice)
info@SonoPath.com

Protein-Losing Nephropathy (PLN)



PATIENT <http://www.sonopath.com/PLN>

Max Pop

SPECIES

Canine

BREED

Entlebucher

SEX

Neutered Male

AGE

6.5 Years

WEIGHT

23.3 kg

INTERPRETED BY

R. McKenzie Daniel, DVM,
DABVP (Canine and
Feline)

IMAGING

PERFORMED BY

Crystal Hill

HOSPITAL NAME

New Hamburg VC

REFERRING VET

Schroeder

INVOICE

13841

DATE

2/7/22

Description: Protein-losing nephropathy (PLN) is a common form of renal disease that typically affects dogs in middle age; it occurs less commonly in cats. Glomerular causes of renal protein loss encompass two broad categories: glomerulonephritis (GN) and amyloidosis. (The causes of GN in human medicine are more specifically differentiated based on a combination of histopathology, immunofluorescence, and electron microscopy findings.) Membranoproliferative glomerulonephritis is the most common cause of GN in dogs and is associated with infectious disease with secondary immune complex deposition as well as Lyme disease. Membranous nephropathy is the second most common cause of GN in dogs and the most common cause in cats. It occurs due to primary immune complex deposition on the urinary side of the basement membrane of the glomerulus, resulting in the leakage of albumin. Amyloidosis is caused by the deposition of amyloid A proteins in a β -pleated sheet configuration in the glomeruli. It is a familial disease in the Shar Pei, but occurs as a reactive disease in other canine breeds. It is also inheritable in the Abyssinian cat, but the amyloidosis occurs in the medulla and is therefore not a protein-losing condition in this breed.

Glomerular lesions can be associated with:

- Infectious diseases:
 - Protozoan: *Babesia*, *Hepatozoon*, and *Leishmania*.
 - Bacterial: *Borrelia*, *Bartonella*, *Brucella*, *Ehrlichia*, *Mycoplasma*, pyometra, pyoderma, endocarditis, and pyelonephritis.
 - Viral: FeLV, FIV, and FIP.
 - Fungal
 - Helminthic: *Dirofilaria*.
- Non-infectious inflammatory diseases: pancreatitis, chronic dermatitis, inflammatory bowel disease, periodontal disease, polyarthritis, and systemic lupus erythematosus (SLE).
- Neoplasia: lymphoma, leukemia, and mast cell disease.
- Familial conditions in the soft-coated Wheaten Terrier, Shar Pei, Beagle, Cocker Spaniel, and Bernese mountain dog.
- Idiopathic conditions.

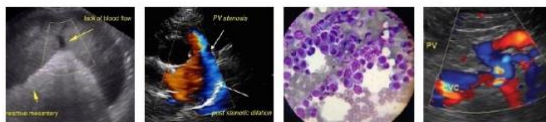
Post-glomerular causes, such as hemorrhage and inflammation, also contribute to urine protein quantification.

Proteinuria Classifications: Patients can be divided into three tiers, depending on their clinical characteristics:

Tier 1A: persistent subclinical proteinuria

Tier 1B: persistent proteinuria with hypertension

Tier 2A: proteinuria and hypoalbuminemia



PATIENT Tier 2B: proteinuria, hypoalbuminemia, and hypertension

Max Pop

SPECIES Tier 3A: proteinuria and azotemia

Canine

Tier 3B: proteinuria, azotemia, and hypertension

Tier 3C: proteinuria, azotemia, hypertension, and hypoalbuminemia

BREED

Entlebucher

Diagnostics: Traditionally, urine protein loss has been detected either through a qualitative test, such as a urine dipstick, or with a semi-quantitative test, such as a urine protein-creatinine (UPC) ratio. When the latter is greater than 0.5, it is considered abnormal. False positive results can occur due to contamination of urine with red blood cells, white blood cells, and bacterial protein. Thus, one must use a urine sample with inactive sediment and a negative culture for measurement purposes. A 24-hour urine protein quantification is more accurate but technically more difficult to obtain, as it requires hospitalization and 24-hour urinary catheterization with a closed collection system. Pooling urine samples can be considered in cases where urine protein loss is stable. One must obtain three different urine samples, combine 1 ml from each sample to submit for a UPC test, and ensure that inactive sediments are present in all the samples. There should be a high degree of correlation between the UPC on the pooled sample and the mean of the three samples measured independently. Research has not yet demonstrated the accuracy of pooled samples for urine samples with high protein loss (i.e., in cases where the UPC is > 8).

SEX

Neutered Male

AGE

6.5 Years

WEIGHT

23.3 kg

INTERPRETED BY

R. McKenzie Daniel, DVM,
DABVP (Canine and
Feline)

Further diagnostic tests will depend on the tier classification. Once proteinuria is documented repeatedly, additional tests can be considered to assess for potential underlying causes, and, further to that, possible sources of antigen stimulation. Depending on presentation, tests may include:

IMAGING PERFORMED BY

Crystal Hill

HOSPITAL NAME

New Hamburg VC

REFERRING VET

Schroeder

INVOICE

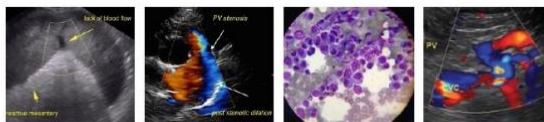
13841

- CBC and biochemical profile
- Urine culture and sensitivity
- 4DX
- Blood pressure measurement
- Thoracic and abdominal radiographs
- Spinal radiographs to assess for discospondylitis
- Abdominal ultrasound to assess for evidence of underlying infection or neoplasia
- Echocardiogram to assess for vegetative endocarditis and possible effects of hypertension
- Screen for Cushing's disease, especially if hypertensive (LDDST or ACTH stimulation)
- ANA
- Expanded tick or infectious disease screen
- Renal biopsy to differentiate among specific causes of PLN

DATE

2/7/22

Renal biopsy should be considered if proteinuria is severe (UPC > 3.5) and hypoalbuminemia and/or hypertension have been documented. Renal biopsy is an invasive procedure and should



PATIENT

Max Pop

be considered only to determine if there is an underlying disease process that would benefit from specific therapy. If the patient is debilitated, severely azotemic, or has uncontrolled hypertension or coagulation abnormalities, then the risk of the procedure and anesthesia may be too great and should not be pursued.

SPECIES

Canine

BREED

Entlebucher

Tissue samples should be submitted for a combination of light microscopy (in formalin; use with special stains), immunofluorescence (in Michel's solution or frozen), and electron microscopy (in formalin with glutaraldehyde). It is imperative to request special media before obtaining the biopsy. Samples can be obtained via ultrasound guidance, laparotomy, or laparoscopy, but cortical samples must be divided so that they can be placed in the three different media. One must ensure that the pre-surgical clotting profile and platelet count are both normal. Patients should undergo pre-biopsy and post-biopsy diuresis.

SEX

Neutered Male

AGE

6.5 Years

Treatment: The main goals of therapy are to i) reduce proteinuria (i.e., UPC < 1.0); ii) prevent a thrombotic event; iii) manage hypertension; and iv) replace fluid deficits. Fluid therapy should be approached cautiously, especially in patients with nephrotic syndrome. Standard therapy for PLN includes a low-protein diet, which in itself will reduce proteinuria, and the administration of an angiotensin-converting enzyme (ACE) inhibitor, such as enalapril (0.5 mg/kg PO BID) or benazepril (0.5 mg/kg PO Q24hr). Newer proposed therapeutic protocols include increasing the ACE inhibitor dose slowly while monitoring BUN and creatinine carefully. The dose can be raised to 1 mg/kg PO BID if needed, provided creatinine has not increased more than 30% from the baseline level.

WEIGHT

23.3 kg

INTERPRETED BY

R. McKenzie Daniel, DVM,
DABVP (Canine and
Feline)

Another class of drugs currently being used is angiotensin receptor blockers, such as Losartan (the dose in azotemic dogs is 0.125-0.25 mg/kg/day PO Q12-24hr and 0.5-1.0 mg/kg/day in non-azotemic patients). This can be combined with an ACE inhibitor, but it is important to monitor BUN, creatinine, and potassium levels. Spironolactone has been used in people in combination with the other two classes of drugs to further modify the renin-angiotensin-aldosterone system (RAAS) (1-2 mg/kg PO BID); however, the effect of using all three drug classes in dogs has not yet been fully investigated. All of these medications are potassium sparing; thus, monitoring for hyperkalemia is important.

IMAGING PERFORMED BY

Crystal Hill

HOSPITAL NAME

New Hamburg VC

REFERRING VET

Schroeder

Hypertension is managed with amlodipine (0.1-0.2 mg/kg PO Q12-24hr) when an ACE inhibitor is insufficient to control blood pressure. Supplementing with an anti-thrombotic agent, such as aspirin (1 mg/kg PO Q24hr), may be considered in advanced cases, especially once the patient is hypoalbuminemic. Omega-3 fatty acids can be given (0.25-0.5 g/day), but are typically increased in standard kidney diets.

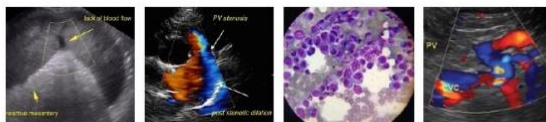
INVOICE

13841

DATE

2/7/22

The most recent controversy in the management of glomerular diseases is the use of immunosuppressive medications. Because it is possible to arrive at a more definitive diagnosis in human patients, the use of immunosuppressive agents can be useful in the management of



PATIENT

Max Pop

SPECIES

Canine

BREED

Entlebucher

SEX

Neutered Male

AGE

6.5 Years

WEIGHT

23.3 kg

INTERPRETED BY

R. McKenzie Daniel, DVM,
DABVP (Canine and
Feline)

**IMAGING
PERFORMED BY**

Crystal Hill

HOSPITAL NAME

New Hamburg VC

REFERRING VET

Schroeder

INVOICE

13841

DATE

2/7/22

the disease, specifically when the disease is immune-mediated in its pathogenesis, such as SLE, membranous nephropathy, and minimal change disease glomerulonephritis. The procurement of a renal biopsy is being advocated in dogs so that practitioners can identify the population of patients that may benefit most from immunosuppressive therapy. Presently, there is no evidence-based medicine to suggest that immunosuppressive therapy should definitely be incorporated into a daily protocol for canine patients; however, it could be beneficial in some cases and may even result in remission. Further investigation is warranted. Trials are currently being conducted in patients with Lyme nephritis that are treated with immunosuppressive agents in addition to standard antibiotic therapy. The IRIS Treatment of Canine Glomerular Disease Study Group has suggested the trial use of immunosuppressive therapy in severe, persistent, or progressive PLN, even without a biopsy diagnosis in specific cases that are unresponsive to standard therapy (i.e., nephrotic syndrome, progressively azotemic, hypoalbuminemic patients). One can also consider administering the following drugs: pulse steroid therapy, mycophenolate, cyclophosphamide, azathioprine, and chlorambucil. One should monitor blood work, UPC ratio, and blood pressure weekly for 2 weeks, then biweekly for 6 weeks, then monthly. If there is further deterioration, immunosuppressive therapy should be discontinued.

References:

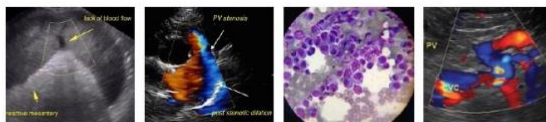
Goldstein R and Polzin D. Treatment of canine glomerular disease: report of the IRIS treatment of canine glomerular disease study group. Proceedings from the American College of Veterinary Internal Medicine, Denver, CO, June 15-18, 2011.

Grauer GF, Greco DS, Getzy DM, et al. Effects of enalapril versus placebo as a treatment for canine idiopathic glomerulonephritis. *J Vet Intern Med* 2000;14:526-33.

Less GE, Cianciolo RE, and Clubb FJ. Renal biopsy and pathologic evaluation of glomerular disease. *Top Companion Anim Med* 2011;26(3):143-53.

LeVine DA, Zhang D, Vaden SL. The use of pooled vs. serial urine samples to measure urine protein:creatinine ratios. *Vet Clin Pathol* 2010;39(1):53-56.

Nabity MB, Boggess MM, Kashtan CE, et al. Day-to-day variability in the urine protein:creatinine ratio in female dogs with stable glomerular proteinuria caused by x-linked hereditary nephropathy. *J Vet Intern Med* 2007;21:425-30.



PATIENT Vaden SL. Glomerular Disease. *Top Companion Anim Med* 2011;26(3):128-34.

Max Pop

SPECIES

Vaden SL. Glomerular Diseases. In: Ettinger SJ and Feldman EC, eds. *Textbook of Veterinary Internal Medicine, 7th Ed.* St Louis, MI: Saunders Elsevier; 2010;2021-36.

Canine

BREED

Vaden SL. Microalbuminuria: What is it and how do I interpret it. Proceedings from the American College of Veterinary Internal Medicine, Charlotte, NC, June 4-7, 2003.

Entlebucher

SEX

Vaden SL et al. Urinary tract inflammation has a variable effect in urine albumin concentration. *J Vet Intern Med* 2002;16:378 (abstract).

Neutered Male

AGE

6.5 Years

WEIGHT

23.3 kg

INTERPRETED BY

R. McKenzie Daniel, DVM,
DABVP (Canine and
Feline)

**IMAGING
PERFORMED BY**

Crystal Hill

HOSPITAL NAME

New Hamburg VC

REFERRING VET

Schroeder

INVOICE

13841

DATE

2/7/22