

PATIENT

"Daisy" Gubernot

PRESENTING CLINICAL SIGNS

Patient presents for echo.

ULTRASONOGRAPHIC EXAMINATION OF THE HEART

SPECIES

Canine

BREED

K9 Mixed Breed

SEX

FS

AGE

9 Years

WEIGHT

22.5 lbs

CANINE CARDIAC PARAMETERS	MR VMAX (m/s)	TR VMAX (m/s)	LA/AO (Boon method)	LA/AO (Heart Base; Swe)	FS (%)	EF (%)	EPSS (cm)
NORMAL PARAMETER	4.5-5.5	<2.7	1.3	<1.6	28-40	40-100	<0.6
PATIENT			1.14	1.3	36.3	68.1	0.2
CANINE CARDIAC PARAMETERS	HR (BPM)	AV VMAX (m/s)	PV MAX (m/s)	BODY WEIGHT (kg)	LA 2D short axis Base view (cm)	LVIDd Avg; 2D and m- mode short axis (cm)	LVIDs Avg; 2D and m-mode short axis (cm)
NORMAL PARAMETER	50-100	0.7-1.7	0.7-1.6	BELOW	BELOW	BELOW	BELOW
PATIENT	102	1.4	0.96		3.4	2.6	

INTERPRETED BY

R. McKenzie Daniel,
DVM, DABVP
(Canine and Feline)

**IMAGING
PERFORMED BY**

Kelly Vazquez

HOSPITAL NAME

Animal Paradise
Hospital

REFERRING VET

Dr. Elshafie

Cardiac Presentation

The echocardiogram in this patient demonstrated normal **left atrial** size based on 3 different LA measurement methods. Chamber volumes and echogenicity were normal. The cranial and caudal **mitral** valve leaflets presented vegetative thickening consistent with endocardiosis. Doppler indicated measurable eccentric insufficiency. The **left ventricle** presented thicknesses with linear contour and was not dilated nor restricted. The **myocardium** presented normal echogenicity without subjective evidence of significant fibrotic or ischemic disease. **Contractility** of the ventricular walls was adequate and in normal range for this patient evidenced by the fractional shortening measurement and subjective evaluation of the different regions of the myocardium. The **left ventricular outflow** tract demonstrated normal laminar flow and subjective structural integrity. The **right atrium** and auricle revealed normal size, structure and content. No evidence of masses was noted or chamber overload. **Tricuspid** valvular assessment demonstrated adequate linear morphology. The **right ventricle** was of normal size (1/3 diameter of LV), chordae structure, myocardial echogenicity and thickness. **Pulmonic** tract assessment revealed normal valve structure, laminar flow, and diameter (approx.1:1 pa/ao ratio). No visible **pericardial** or free pleura fluid was noted. No echographically detectable evidence of infiltrative disease was visible. The cranial **mediastinum and pericardial regions** were free of masses in the visible window

ULTRASONOGRAPHIC FINDINGS

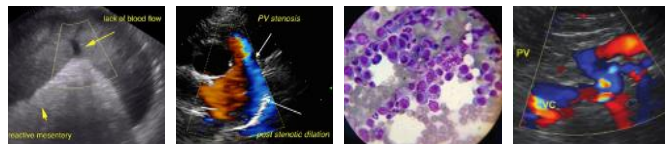
- Chronic mitral valve disease (ACVIM b1).

INVOICE

50126

DATE

2-7-22



PATIENT

"Daisy" Gubernot

SPECIES

Canine

BREED

K9 Mixed Breed

SEX

FS

AGE

9 Years

WEIGHT

22.5 lbs

INTERPRETED BY

R. McKenzie Daniel,
DVM, DABVP
(Canine and Feline)

IMAGING PERFORMED BY

Kelly Vazquez

HOSPITAL NAME

Animal Paradise
Hospital

REFERRING VET

Dr. Elshafie

INVOICE

50126

DATE

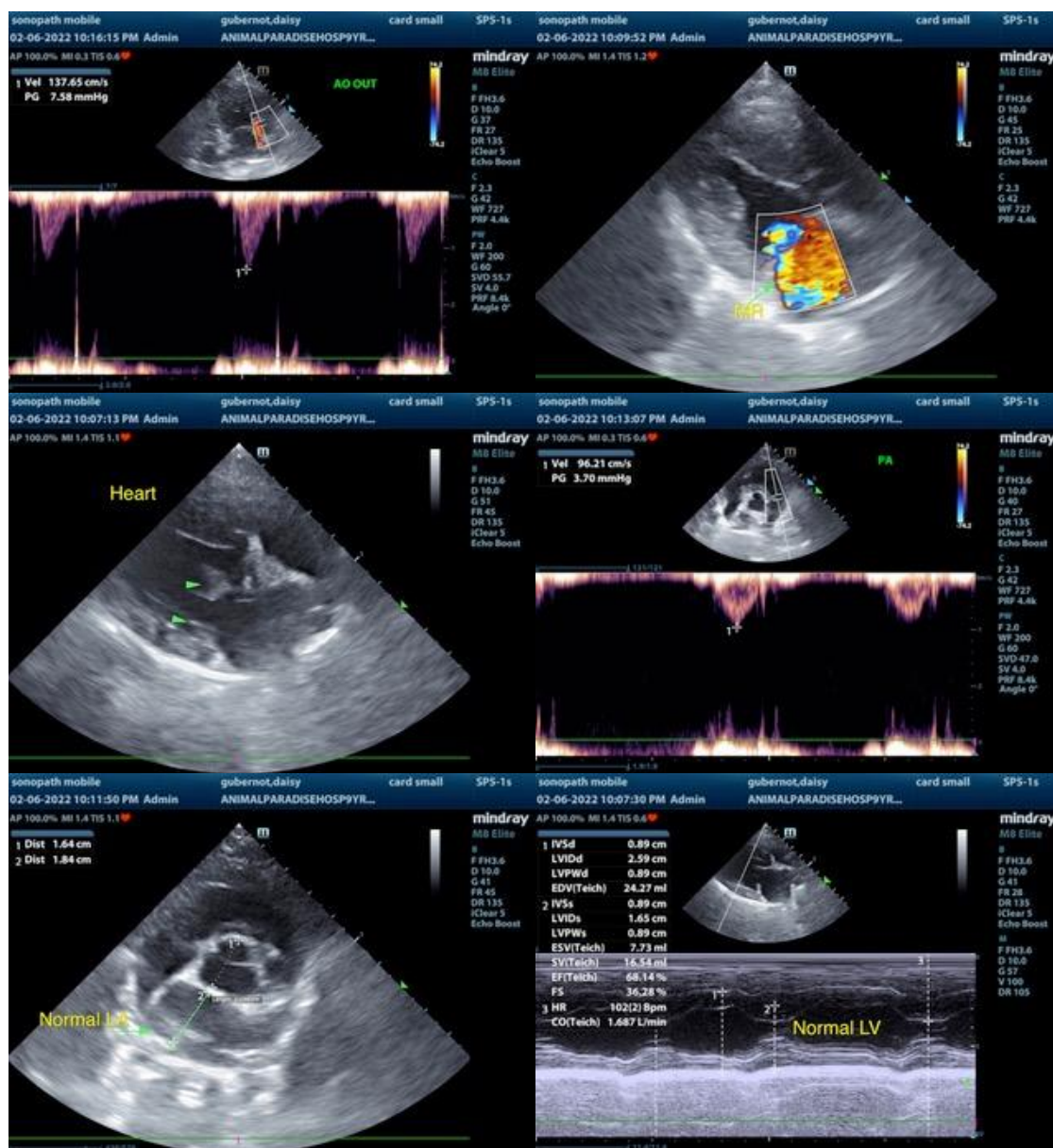
2-7-22

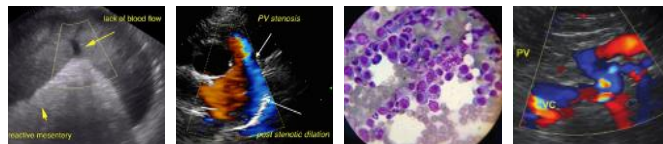
INTERPRETATION OF THE FINDINGS & FURTHER RECOMMENDATIONS

The cause of the murmur is chronic degenerative valvular changes with secondary eccentric mitral valve insufficiency. No other clinical issues such as systolic dysfunction or evidence of clinical pulmonary hypertension were present. The lack of left atrial enlargement implies that the risk of complication secondary to mitral valve insufficiency is low at this time and, without current clinical signs, indicates that medical therapy is not required. Conservative monitoring is recommended with a recheck echocardiogram in 6-12 months, sooner if clinical signs suggestive of heart disease develop.

No overt anesthetic contraindications if anesthesia is required.

Suggested anesthetic protocol may include opioid or Benzodiazepine pre-med, induction with Propofol or Alfaxalone, and appropriate gas anesthesia with avoidance of alpha 2 agonists.





PATIENT

"Daisy" Gubernot

The information and recommendations provided are based on the images presented by the referring veterinarian/sonographer. No evaluation can be communicated regarding pathology that was not visible in the image/video clips provided.

SPECIES

Canine

Thank you for this referral. If the clinical or image interpretation does not parallel your findings or if I can be of any further assistance please contact me.

BREED

K9 Mixed Breed

R. McKenzie Daniel, DVM, DABVP (Canine / Feline Practice)
info@SonoPath.com

SEX

FS

AGE

9 Years

WEIGHT

22.5 lbs

INTERPRETED BY

R. McKenzie Daniel,
DVM, DABVP
(Canine and Feline)

**IMAGING
PERFORMED BY**

Kelly Vazquez

HOSPITAL NAME

Animal Paradise
Hospital

REFERRING VET

Dr. Elshafie

INVOICE

50126

DATE

2-7-22