



PATIENT

Angus Eidet

SPECIES

Feline

BREED

DSH

SEX

Neutered Male

AGE

15 Years

WEIGHT

17 Lbs.

PRESENTING CLINICAL SIGNS

History: Coughing often especially with food.

Abnormal PE/Chem/CBC/UA Results: Bloodwork unremarkable. Standard geriatric exam. Multi view rads show potential adenocarcinoma in right caudal thoracic cavity.

ULTRASONOGRAPHIC EXAMINATION OF THE HEART & ABDOMEN

| FELINE CARDIAC PARAMETERS | BODY WEIGHT (kg) | HR (BPM) | IVSd (cm) | LVIDd (cm) | LVWd (cm) | FS (%) | EF (%) |
|---|------------------|---------------------------|--|-----------------|-----------------|-----------|--------|
| NORMAL PARAMETER | ----- | 150-240 | 0.3-0.6 | 1.0-2.1 | 0.25-0.6 | 35-67 | 80-100 |
| PATIENT | -- | 210 | 0.56 | 1.6 | 0.56 | 54.9 | 88.2 |
| FELINE CARDIAC PARAMETERS | LA/AO (Boon) | LA/AO HEART BASE (Sisson) | LA 2D 4-chamber long axis AS to FW (Sisson) (cm) | LVOT VEL. (m/s) | RVOT VEL. (m/s) | IVRT (m/) | |
| NORMAL PARAMETER | <1.5 | 0.88-1.79 | 0.7-1.7 | <1.6 | <1.3 | 40-60 | |
| PATIENT | 1.3 | 1.2 | 1.3 | 1.0 | 0.82 | NM | |
| Adapted from June Boon, Veterinary Echocardiography, 1998 | | | | | | | |
| Sisson D et al. JVIM 1991; 5: 232, Jacobs et al. Am J Vet Res 1985; 46:1705 | | | | | | | |

INTERPRETED BY

R. McKenzie Daniel,
DVM, DABVP
(Canine and Feline)

IMAGING PERFORMED BY

Rachel Runnells, RVT

HOSPITAL NAME

SVS Imaging KC

REFERRING VET

Dr. Breinin

INVOICE

13845

DATE

2/7/22

Cardiac Presentation

The echocardiogram in this patient demonstrated normal **left atrial** size and structure. Chamber volume and blood echogenicity were normal. The cranial and caudal **mitral** valve leaflets presented minor irregular age-related changes that are not clinically significant at this time with adequate extension in systole and union in diastole. The **left ventricle** presented normal free wall and septal thicknesses with linear contour. The **myocardium** presented some echogenic remodeling consistent with expected age-related change. **Contractility** of the ventricular walls was adequate and in normal range for this breed and patient size. The **left ventricular outflow** tract demonstrated normal laminar flow with subjectively unremarkable structure. Subjective assessment of the **right atrium** and auricle revealed normal size, structure and content. No evidence of masses was noted. **Tricuspid** valvular assessment demonstrated expected findings for this age patient. The **right ventricle** was of normal size (1/3 diameter of LV), echogenicity and thickness. **Pulmonic** tract assessment revealed normal valve structure, laminar flow, and diameter (approx. 1:1 pa/ao ratio). No visible **pericardial** or free pleural fluid was noted. The **mediastinum** and pericardial regions were free of overt masses in the visible window. Several to multiple, non-homogeneous and well-demarcated from peripheral to deep aerated lung nodules were present as well as nodule noted immediately cranial to the diaphragm within the caudal thorax or lung was present. An example of a nodule measured 1.5 cm to 2.5 cm in diameter.

Urinary System

The urinary bladder, trigone, cystourethral junction, and visible pelvic urethra to a depth of 3.0 cm exhibited normal thickness and tone. Primarily anechoic urine was present in the lumen. Mild non-



PATIENT

Angus Eidet

dependent particulate sediment was present, likely indicative of cellular or crystalline debris with potential for mucus. The ureteral papillae were normal. The ureters were not visible which is normal. No evidence of inflammatory or neoplastic mural changes were noted. Aortic trifurcation was normal.

SPECIES

Feline

Normal size and margination was present in the kidneys. A normal 1:3 cortex / medulla ratio was maintained. The medulla and cortices were uniform in texture with some increased echogenicity and loss of corticomedullary symmetry and definition expected for the age of the patient. No evidence of pelvic dilation was present. The left kidney measured 4.2 cm in length. The right kidney measured 4.5 cm in length.

BREED

DSH

Adrenal Glands

The left adrenal gland was uniform in size and contour with a uniformly hypoechoic parenchyma. The left adrenal gland measured 0.31 cm width.

SEX

Neutered Male

The right adrenal gland was uniform in size and contour with a uniformly hypoechoic parenchyma. The right adrenal gland measured 0.32 cm width.

AGE

15 Years

Spleen

The spleen exhibited potential for borderline enlargement, measuring 1.0 cm in width. Subtle asymmetrical medial capsule contour was present with generalized mild splenic parenchyma heterogeneity with intermittent non-expansive discrete hypoechoic parenchymal nodule present.

WEIGHT

17 Lbs.

Liver

The liver was subjectively normal in size, structure, and contour. The liver parenchyma was uniform and hypoechoic to the spleen with a mild coarse echotexture. The hepatic and portal vasculature were normal in appearance without signs of congestion.

INTERPRETED BY

R. McKenzie Daniel,
DVM, DABVP
(Canine and Feline)

The gallbladder was non-distended in size with thin walls and primarily anechoic luminal content. The cystic and common bile ducts were normal.

IMAGING PERFORMED BY

Rachel Runnells, RVT

Gastrointestinal

The stomach presented intact wall layering with a normal wall layer ratio. The lumen of the stomach was empty with no signs of ileus, obstruction or foreign material. The gastric body wall measured 0.25 cm.

HOSPITAL NAME

SVS Imaging KC

The small intestine presented intact wall layering and primarily maintained 1:3 muscularis/mucosa ratio with segmental propensity for mildly prominent muscularis layer. No overt evidence of loss of small intestinal wall layering or intestinal masses. The jejunum wall measured up to 0.30 cm in width.

REFERRING VET

Dr. Breinin

Normal visible colon wall layers were present with apparent formed feces in lumen.

Pancreas

The parenchyma of the left limb, body and right limb of the pancreas presented isoechoic to the adjacent omental fat. A normal curvilinear capsule contour of the pancreas was present. The visible pancreatic duct was normal. No signs of active inflammation or neoplastic disease was evident.

INVOICE

13845

Free Abdomen

DATE

2/7/22

No omental masses, lymphadenopathy or effusion was present.

ULTRASONOGRAPHIC FINDINGS



PATIENT

Angus Eidet

SPECIES

Feline

BREED

DSH

SEX

Neutered Male

AGE

15 Years

WEIGHT

17 Lbs.

INTERPRETED BY

R. McKenzie Daniel,
DVM, DABVP
(Canine and Feline)

IMAGING PERFORMED BY

Rachel Runnells, RVT

HOSPITAL NAME

SVS Imaging KC

REFERRING VET

Dr. Breinin

INVOICE

13845

DATE

2/7/22

- Normal echocardiogram with minor LV myocardial remodeling
- Several to multiple right to caudal thoracic pulmonary nodules
- Mild urinary bladder sediment
- Mild chronic renal changes
- Potential borderline splenomegaly with intermittent nonspecific discreet hypochoic nodules
- Possible segmental mild inflammatory enteropathy pattern

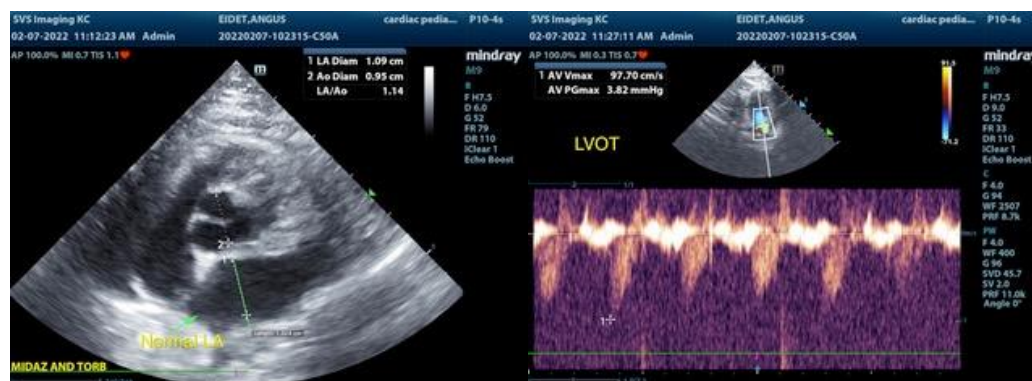INTERPRETATION OF THE FINDINGS & FURTHER RECOMMENDATIONS

The small intestine exhibited subtle mural changes, which if history of weight loss or gastrointestinal signs, may suggest potential for mild inflammatory enteropathy. However, given the lack of reported gastrointestinal signs or weight loss, this finding is nonspecific.

Age-related splenic changes with incidental areas of lymphoid hyperplasia, hematopoiesis or incidental splenitis possible. The spleen was not overtly consistent with neoplastic criteria, yet this potential cannot be definitively excluded.

Overall, an obvious source of overt intraabdominal neoplasia as the potential cause of metastatic pulmonary nodules was not overtly evident. This is suggestive of probable primary pulmonary or thoracic neoplasia.

Assuming normal clotting status, ultrasound guided FNA of a peripheral pulmonary nodule as well as the spleen, using a 25-gauge needle, could be considered for screening cytology and further clarification.





PATIENT

Angus Eidet

SPECIES

Feline

BREED

DSH

SEX

Neutered Male

AGE

15 Years

WEIGHT

17 Lbs.

INTERPRETED BY

R. McKenzie Daniel,
DVM, DABVP
(Canine and Feline)

IMAGING PERFORMED BY

Rachel Runnells, RVT

HOSPITAL NAME

SVS Imaging KC

REFERRING VET

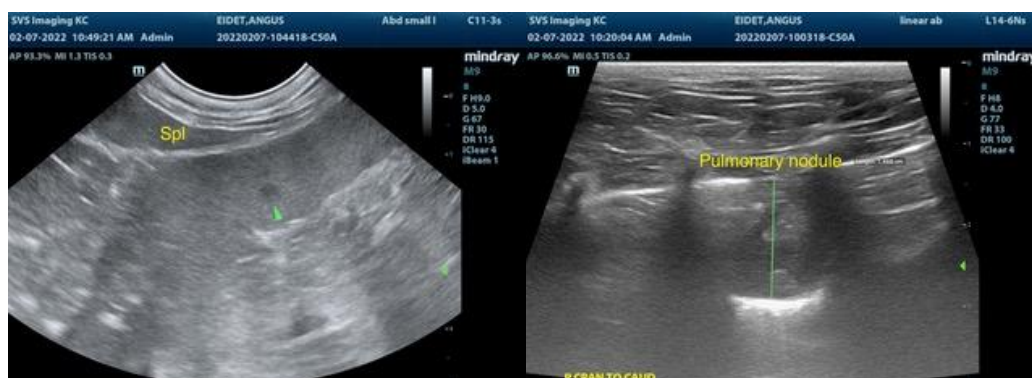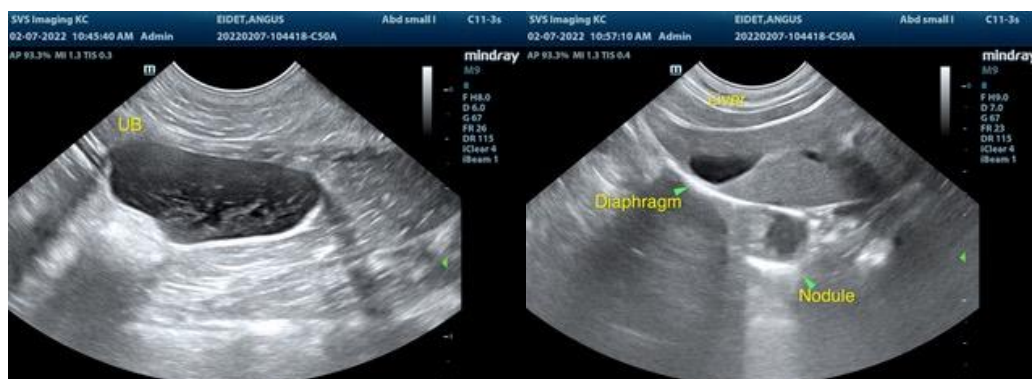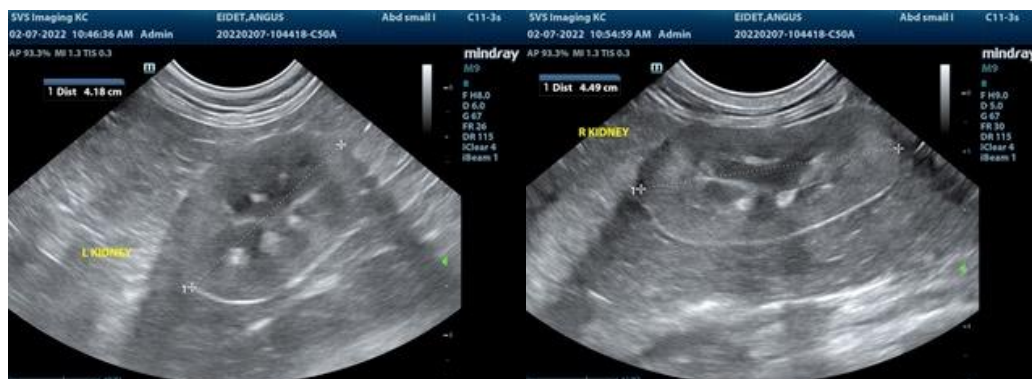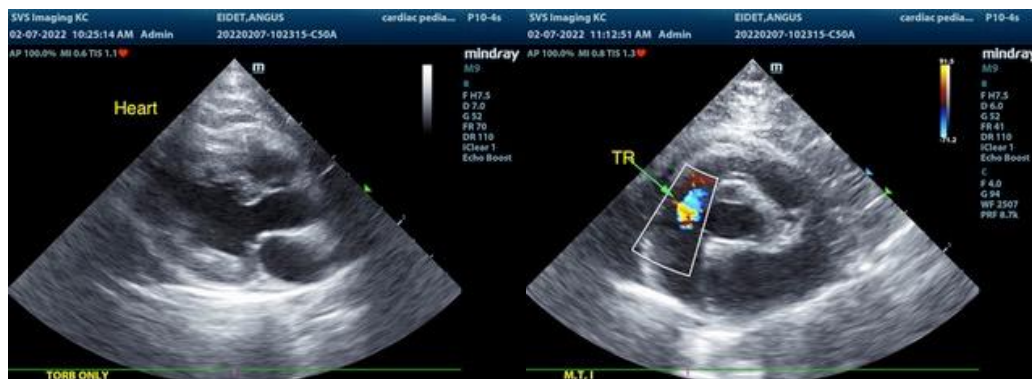Dr. Breinin

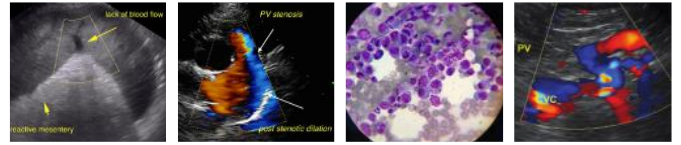
INVOICE

13845

DATE

2/7/22





PATIENT

Angus Eidet

SPECIES

Feline

BREED

DSH

SEX

Neutered Male

AGE

15 Years

WEIGHT

17 Lbs.

INTERPRETED BY

R. McKenzie Daniel,
DVM, DABVP
(Canine and Feline)

**IMAGING
PERFORMED BY**

Rachel Runnells, RVT

HOSPITAL NAME

SVS Imaging KC

REFERRING VET

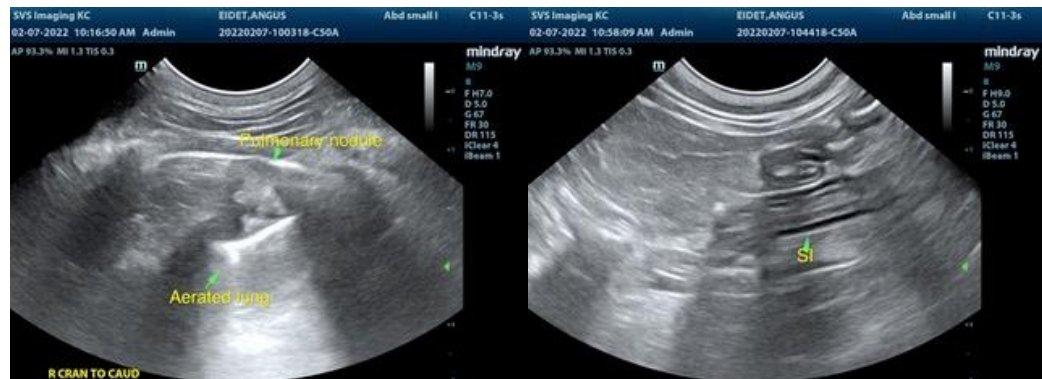Dr. Breinin

INVOICE

13845

DATE

2/7/22



The information and recommendations provided are based on the images presented by the referring veterinarian. No evaluation can be communicated regarding pathology that was not visible in the image/video clips provided.

Thank you for this referral. If the clinical or image interpretation does not parallel your findings or if I can be of any further assistance please contact me.

R. McKenzie Daniel, DVM, DABVP (Canine / Feline Practice)
info@SonoPath.com