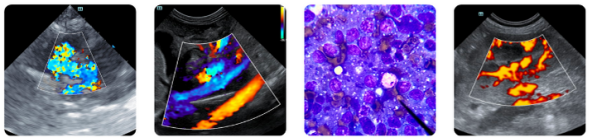

PATIENT
Tobie Skeen

SPECIES
Feline

BREED
DSH

SEX
Male Neutered

AGE
15y

WEIGHT
10.5 lbs

INTERPRETED BY
R. McKenzie Daniel, DVM, DABVP (Canine and Feline)

IMAGING PERFORMED BY
Brita Kiffney

HOSPITAL NAME
Northshore VH

REFERRING VET
Brita Kiffney

INVOICE
13171

DATE
2/6/26

PRESENTING CLINICAL SIGNS

History:

- New patient, was feral and trapped about 12 years ago, has had all his teeth previously extracted. Owner notes weight loss
- Exam No teeth, EENT normal, slightly thickened intestines

Abnormal PE/Chem/CBC/UA Results: Pending cbc chem ua fecal T4

ULTRASONOGRAPHIC EXAMINATION OF THE ABDOMEN

Urinary System

The urinary bladder, trigone, cystourethral junction, and visible pelvic urethra to a depth of 2.0 cm exhibited normal thickness and tone. Anechoic urine was present in the lumen with no uroliths or sediment. The ureteral papillae were normal. The ureters were not visible which is normal. No evidence of inflammatory or neoplastic changes were noted.

The area of the aortic trifurcation was free of pathology.

Normal size and margination was present in the kidneys. A normal 1:3 cortex / medulla ratio was maintained. The medulla and cortices were uniform in texture with some increased echogenicity and mild loss of corticomedullary symmetry and definition expected for the age of the patient. No evidence of pelvic dilation was present. Medullary mineral was present but more prominent in the left kidney. The left kidney measured 3.6 cm in length. The right kidney measured 3.7 cm in length.

Adrenal Glands

The left adrenal gland was uniform in size and contour with a uniformly hypoechoic parenchyma. The left adrenal gland measured 0.37 cm. The right adrenal gland was indistinctly visualized with no obvious pathology subjectively measuring 0.30 cm.

Spleen

The spleen exhibited a finely textured and homogenous parenchyma which was hyperechoic to the liver and renal cortical parenchyma. The capsule was smooth and regular without apparent expansion. The splenic vasculature at the hilus was normal in volume with no evidence of congestion or thrombosis. Acute to chronic inflammatory, neoplastic, or benign parenchyma changes were not noted.

Liver

The liver was subjectively normal in size, structure, and contour. The liver parenchyma was uniform and hypoechoic to the spleen with a mild coarse echotexture. The hepatic and portal vasculature were normal in appearance without signs of congestion. The gallbladder was non distended in size with primarily gravity dependent, non-homogeneous, echogenic, nonmineralized biliary sludge. Small, non-obstructive cholelith present measuring ~0.5 cm in diameter. The common bile duct was not visualized.

PATIENT
Tobie Skeen

SPECIES
Feline

BREED
DSH

SEX
Male Neutered

AGE
15y

WEIGHT
10.5 lbs

INTERPRETED BY
R. McKenzie Daniel, DVM, DABVP (Canine and Feline)

IMAGING PERFORMED BY
Brita Kiffney

HOSPITAL NAME
Northshore VH

REFERRING VET
Brita Kiffney

INVOICE
13171

DATE
2/6/26

Gastrointestinal

The stomach presented intact wall layering with a normal wall layer ratio. The lumen of the stomach was empty with no signs of ileus, obstruction or foreign material.

The small intestine presented mildly thickened intact wall layering with 1:3 muscularis/mucosa ratio. Jejunum wall measured 0.29 cm and duodenum wall measured 0.31 cm. The lumen of the small intestine was empty with no signs of ileus, obstruction or foreign material.

Normal visible colon wall layers were present with apparent formed feces in lumen.

Pancreas

The parenchyma of the left limb, body and right limb of the pancreas presented isoechoic to the adjacent omental fat. A normal curvilinear capsule contour of the pancreas was present. The visible pancreatic duct was normal. No signs of active inflammation or neoplastic disease was evident.

Free Abdomen

No visualized significant omental lymphadenopathy or peritoneal effusion was present.

ULTRASONOGRAPHIC FINDINGS

- Intact mildly thickened small intestine wall
- Age-related kidneys with medullary mineral
- Gallbladder debris with non-obstructive cholelith

INTERPRETATION OF THE FINDINGS & FURTHER RECOMMENDATIONS

Although possible patient variant, the small intestine suggests mild to chronic inflammatory enteropathy criteria, i.e. IBD or other. No overt sonographic evidence of abdominal or intestinal neoplastic criteria which is thought less likely. Correlation with pending lab work is recommended. Concurrent GI panel to include PLI/TLI/Cobalamin/Folate and screening 3-view chest radiographs suggested.

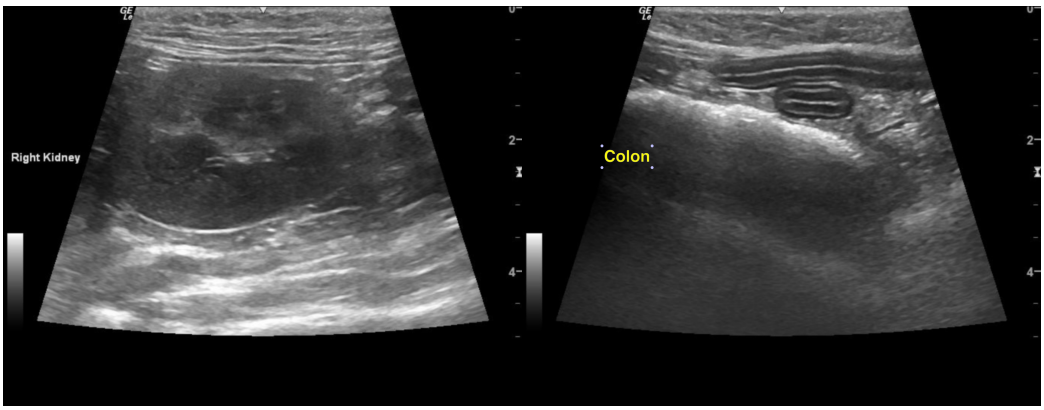

SonoPath

FOSTERING THE ART OF VETERINARY MEDICINE™

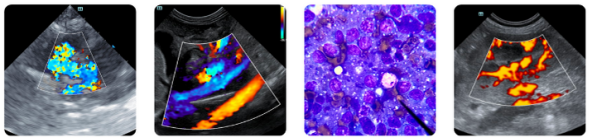

Clinical Sonography & Telecytology

Educational Teleconsultation Services™

SonoPath.com *info@sonopath.com* *1.800.838.4268*

PATIENT

Tobie Skeen

SPECIES

Feline

BREED

DSH

SEX

Male Neutered

AGE

15y

WEIGHT

10.5 lbs

INTERPRETED BY

R. McKenzie Daniel, DVM, DABVP (Canine and Feline)

IMAGING PERFORMED BY

Brita Kiffney

HOSPITAL NAME

Northshore VH

REFERRING VET

Brita Kiffney

INVOICE

13171

DATE

2/6/26

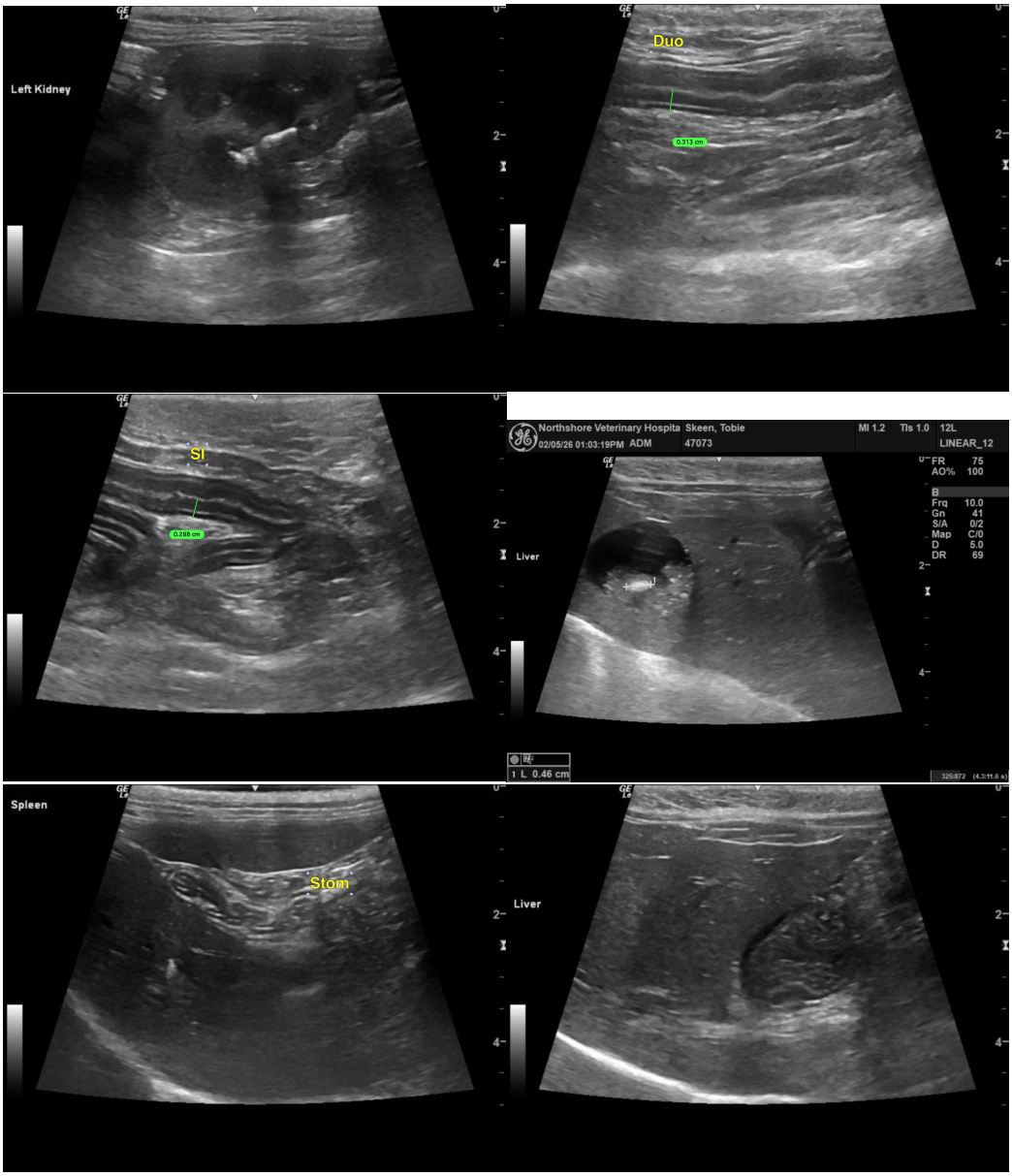

The information and recommendations provided are based on the images presented by the referring veterinarian/sonographer. No evaluation can be communicated regarding pathology that was not visible in the image/video clips provided.

Thank you for this referral. If the clinical or image interpretation does not parallel your findings or if I can be of any further assistance, please contact me.

R. McKenzie Daniel, DVM, DABVP (Canine / Feline Practice)

info@sonopath.com

SonoPath
FOSTERING THE ART OF VETERINARY MEDICINE™

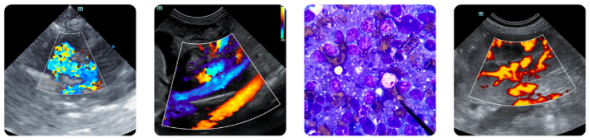

Clinical Sonography & Telecytology
Educational Teleconsultation Services™

SonoPath.com info@sonopath.com 1.800.838.4268

PATIENT

Tobie Skeen

SPECIES

Feline

BREED

DSH

SEX

Male Neutered

AGE

15y

WEIGHT

10.5 lbs

INTERPRETED BY

R. McKenzie Daniel, DVM, DABVP (Canine and Feline)

IMAGING PERFORMED BY

Brita Kiffney

HOSPITAL NAME

Northshore VH

REFERRING VET

Brita Kiffney

INVOICE

13171

DATE

2/6/26