



PATIENT

Pippi Carucci

SPECIES

Feline

BREED

Siamese

SEX

Spayed Female

AGE

11

WEIGHT

11

INTERPRETED BY

R. McKenzie Daniel,
DVM, DABVP (Canine
/ Feline Practice)

IMAGING PERFORMED BY

Jenn

HOSPITAL NAME

Rockaway Animal
Hospital

REFERRING VET

Dr. Maniar

INVOICE

13603

DATE

02/05/26

PRESENTING CLINICAL SIGNS

- Coughing, Hx of asthma O found carpet fibers in pets mouth

ULTRASONOGRAPHIC EXAMINATION OF THE HEART & ABDOMEN \

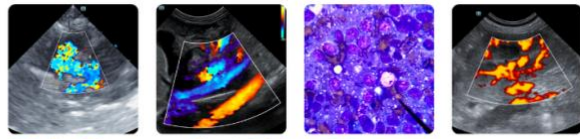
FELINE CARDIAC PARAMETERS	BODY WEIGHT	HR (BPM)	IVSd (cm)	LVIDd (cm)	LVWd (cm)	FS (%)	EF (%)
NORMAL PARAMETER	-----	150-240	0.3-0.6	1.0-2.1	0.25-0.6	35-67	80-100
PATIENT	11.0	NM	0.5	1.37	0.46	48	82
FELINE CARDIAC PARAMETERS	LA/AO (M-mode)	LA/AO HEART BASE (Sisson)	LAD LA MAX 4 Chamber		LVOT VEL. (m/s)	RVOT VEL. (m/s)	IVRT (m/)
NORMAL PARAMETER	<1.5	1.6	0.7-1.7		<1.6	<1.3	40-60
PATIENT	--	1.2	1.2		--	1.0	NM
Adapted from June Boon, Veterinary Echocardiography, 1998 Sisson D et al. JVIM 1991; 5: 232, Jacobs et al. Am J Vet Res 1985; 46:1705							

Cardiac Presentation

The echocardiogram in this patient demonstrated normal **left atrial** size based on 2 separate LA measurements. The cranial and caudal **mitral** valve leaflets presented normal linear structure and kinetics. The **left ventricle** presented normal thicknesses with linear contour and was not dilated nor restricted. The **myocardium** presented normal echogenicity without subjective evidence of significant fibrotic or ischemic disease. **Contractility** of the ventricular walls was adequate and in normal range for this patient evidenced by the fractional shortening measurement and subjective evaluation of the different regions and angles of the myocardium. The **left ventricular outflow** tract demonstrated normal laminar flow and subjective structural integrity. The **right atrium** and auricle revealed normal size, structure and content. No evidence of masses was noted or chamber overload. **Tricuspid** valvular assessment demonstrated adequate linear morphology and kinetics. The **right ventricle** was of normal size (1/3 diameter of LV), chordae structure, myocardial echogenicity and thickness. **Pulmonic** tract assessment revealed normal valve structure, laminar flow, and diameter (approx.1:1 pa/ao ratio). No visible **pericardial** or free pleura fluid was noted or extra cardiac pathology in the visible planes. The cranial **mediastinum and pericardial regions** were free of masses in the visible window.

Urinary System

The urinary bladder, trigone, cystourethral junction, and visible pelvic urethra exhibited normal thickness and tone. Primarily anechoic urine was present in the lumen. Echogenic to particulate nondependent mild sediment was present without evidence of calculus formation. The ureteral papillae were normal. The ureters were not visible which is normal. No evidence of inflammatory or neoplastic mural changes were noted.



PATIENT

Pippi Carucci

SPECIES

Feline

BREED

Siamese

SEX

Spayed Female

AGE

11

WEIGHT

11

INTERPRETED BY

R. McKenzie Daniel,
DVM, DABVP (Canine
/ Feline Practice)

IMAGING PERFORMED BY

Jenn

HOSPITAL NAME

Rockaway Animal
Hospital

REFERRING VET

Dr. Maniar

INVOICE

13603

DATE

02/05/26

Normal size and margination was present in the kidneys. A normal 1:3 cortex / medulla ratio was maintained. Mild hyperechoic cortex with mildly enhanced indistinct corticomedullary border demarcation and mild increased medullary echogenicity. The left kidney measured 3.4 cm in length. The right kidney measured 3.6 cm in length.

Adrenal Glands

No obvious pathology in the areas of the left and right adrenal glands.

Spleen

The spleen exhibited a finely textured and homogenous parenchyma which was hyperechoic to the liver and renal cortical parenchyma. The capsule was smooth and regular without apparent expansion. The splenic vasculature at the hilus was normal in volume with no evidence of congestion or thrombosis. Acute to chronic inflammatory, neoplastic, or benign parenchyma changes were not noted.

Liver & Gallbladder

The liver was subjectively normal in size, structure, and contour. The liver parenchyma was uniform and hypoechoic to the spleen with a mild coarse echotexture. The hepatic and portal vasculature were normal in appearance without signs of congestion.

The gallbladder was subnormal to contracted in size. The common bile duct was visualized without dilation.

Gastrointestinal

The stomach presented intact wall layering with a normal wall layer ratio. The lumen of the stomach contained variably echogenic, nonshadowing ingesta and lumen gas without signs of obstruction or foreign material.

The small intestine presented intact wall layering with 1:3 muscularis/mucosa ratio. Segmental mild nonshadowing ingesta/chyme. The jejunum wall measured 0.24 cm wall width. The ileocolic wall measured 0.36 cm wall width.

Normal visible colon wall layers were present with apparent formed feces in lumen.

Pancreas

The parenchyma of the left limb, body and right limb of the pancreas presented isoechoic to the adjacent omental fat. A normal curvilinear capsule contour of the pancreas was present. The visible pancreatic duct was normal. No signs of active inflammation or neoplastic disease was evident.

Free Abdomen

No overt lymphadenopathy or peritoneal effusion was present.

ULTRASONOGRAPHIC FINDINGS

- Normal cardiac structure/function.
- Mild urine sediment.
- Mild chronic renal changes.



PATIENT

Pippi Carucci

SPECIES

Feline

BREED

Siamese

SEX

Spayed Female

AGE

11

WEIGHT

11

INTERPRETED BY

R. McKenzie Daniel,
DVM, DABVP (Canine
/ Feline Practice)

IMAGING PERFORMED BY

Jenn

HOSPITAL NAME

Rockaway Animal
Hospital

REFERRING VET

Dr. Maniar

INVOICE

13603

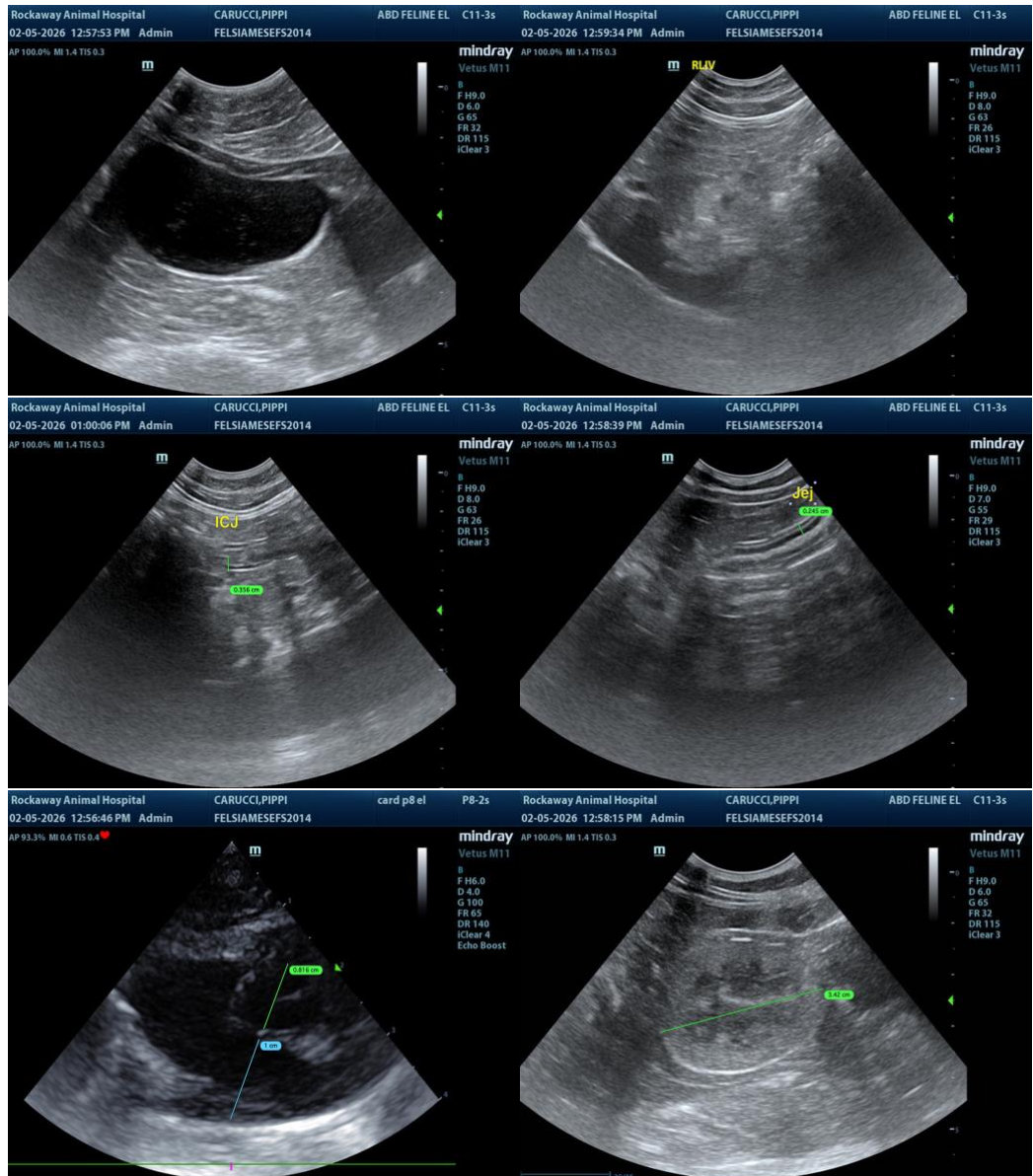
DATE

02/05/26

- Normal gastrointestinal tract with gastrointestinal ingesta- most consistent with food echogenicity.

INTERPRETATION OF THE FINDINGS & FURTHER RECOMMENDATIONS

Correlation with most recent meal ingestion is recommended. If documented fasted or if gastrointestinal signs, hospitalization with documented 12-hour NPO and sonographic reassessment of the gastrointestinal tract may be considered. No evidence of significant cardiac or abdominal visceral pathology. The coughing in this patient is non-cardiogenic in origin in conjunction with the patient's clinical history.





PATIENT

Pippi Carucci

SPECIES

Feline

BREED

Siamese

SEX

Spayed Female

AGE

11

WEIGHT

11

INTERPRETED BY

R. McKenzie Daniel, DVM, DABVP (Canine / Feline Practice)

IMAGING PERFORMED BY

Jenn

HOSPITAL NAME

Rockaway Animal Hospital

REFERRING VET

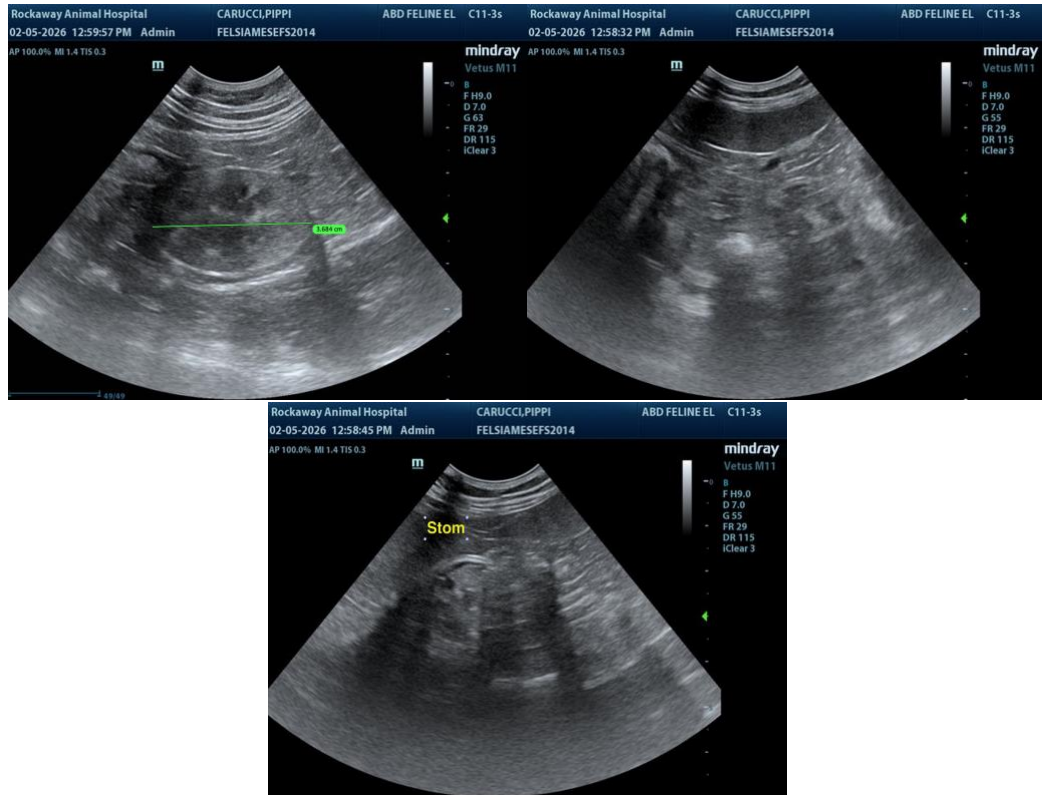
Dr. Maniar

INVOICE

13603

DATE

02/05/26



The information and recommendations provided are based on the images presented by the referring veterinarian/sonographer. No evaluation can be communicated regarding pathology that was not visible in the image/video clips provided.

Thank you for this referral. If the clinical or image interpretation does not parallel your findings or if I can be of any further assistance, please contact me.

R. McKenzie Daniel, DVM, DABVP (Canine / Feline Practice)

info@SonoPath.com