



PATIENT

Qwinci Kostelecky

SPECIES

Canine

BREED

German Wirehaired
Pointer

SEX

M

AGE

13 years, 4 months

WEIGHT

54 lbs

INTERPRETED BY

R. McKenzie Daniel,
DVM, DABVP
(Canine and Feline)

IMAGING PERFORMED BY

Dr. Jessie Evoniuk

HOSPITAL NAME

State Avenue Vet
Clinic

REFERRING VET

Dr. Jessie Evoniuk

INVOICE

10610

DATE

2/4/26

PRESENTING CLINICAL SIGNS

History:

- Presented for abdominal ultrasound to evaluate for any masses, gallbladder disease, etc
- No change in clinical status since last visit on 1/27, Last meal at 5:30 PM previous evening
- Current medications: - Trazodone (administered this morning) - Gabapentin (administered this morning)

Abnormal PE/Chem/CBC/UA Results: Abnormal PE: Multiple cutaneous masses: periocular mass (right side) increased size, sensitive to palpation, non-ulcerated, non-draining; additional masses upper left, right side, and other locations, some with evidence of licking/irritation Heart murmur present Mild post-exercise stiffness Previously fractured canine tooth, no current swelling or drainage Citrated Prothrombin Time (PT)-12.0, Citrated Partial Thromboplastin Time (PTT)- 87 1/27/26 bloodwork: ALP 1348, AST 241

ULTRASONOGRAPHIC EXAMINATION OF THE ABDOMEN

Urinary System

The urinary bladder, trigone, cystourethral junction, and visible pelvic urethra to a depth of 5.0 cm exhibited normal thickness and tone. Anechoic urine was present in the lumen with no uroliths or sediment. The ureteral papillae were normal. The ureters were not visible which is normal. No evidence of inflammatory or neoplastic changes were noted.

The prostate was enlarged in size with intact, symmetrical capsule contour. The margins of the gland were intact and able to be differentiated from the surrounding tissue. The prostatic parenchyma was mildly echogenic to heteroechoic without parenchymal mineralization. The prostate measured 5.3 cm in diameter.

No evidence of pathology in the area of the aortic trifurcation.

Normal size and margination were present in the kidneys. A normal 1:3 cortex / medulla ratio was maintained. The medulla and cortices were uniform in texture with some increased echogenicity and mild loss of corticomedullary symmetry and definition expected for the age of the patient. No evidence of pelvic dilation was present. The left kidney measured 7.7 cm in length. The right kidney measured 7.7 cm in length.

Adrenal Glands

The left adrenal gland was uniform in size and contour with a uniformly hypoechoic parenchyma. The left adrenal gland measured 0.67 cm width at the caudal pole. The area of the right adrenal gland was free of obvious pathology.

Spleen

The spleen exhibited a finely textured and homogenous parenchyma which was hyperechoic to the liver and renal cortical parenchyma. The capsule was smooth and regular without apparent expansion. The splenic vasculature at the hilus was normal in volume with no evidence of congestion or thrombosis. Acute to chronic inflammatory, neoplastic, or benign parenchyma changes were not noted.



PATIENT

Qwinci Kostelecky

SPECIES

Canine

BREED

German Wirehaired
Pointer

SEX

M

AGE

13 years, 4 months

WEIGHT

54 lbs

INTERPRETED BY

R. McKenzie Daniel,
DVM, DABVP
(Canine and Feline)

IMAGING PERFORMED BY

Dr. Jessie Evoniuk

HOSPITAL NAME

State Avenue Vet
Clinic

REFERRING VET

Dr. Jessie Evoniuk

INVOICE

10610

DATE

2/4/26

Liver/ Gallbladder

Caudally expansive, mixed echogenic liver mass was present, measuring ~14.0 -15.0 cm in diameter. The discernible intact hepatic parenchyma exhibited normal echogenicity with mild coarse echotexture and parenchymal remodeling. The gallbladder was non-distended in size with thin walls and primarily anechoic luminal content. The cystic and common bile ducts were normal.

Gastrointestinal

The stomach presented intact wall layering with a normal wall layer ratio. The lumen of the stomach was empty without evidence of retained ingesta, fluid, or foreign material. The stomach was displaced caudally and subjectively dorsally, owing to the liver mass.

The small intestine presented intact wall layering with 1:3 muscularis/mucosa ratio. The lumen of the small intestine was empty with no signs of ileus, obstruction, or foreign material.

Normal visible colon wall layers were present with formed feces in lumen.

Pancreas

The parenchyma of the left limb, body and right limb of the pancreas presented isoechoic to the adjacent omental fat. A normal curvilinear capsule contour of the pancreas was present. The visible pancreatic duct was normal. No signs of active inflammation or neoplastic disease was evident.

Free Abdomen

No overt lymphadenopathy or peritoneal effusion was present.

ULTRASONOGRAPHIC FINDINGS

- Large caudally expanding liver mass
- Normal spleen
- Age-related renal changes
- Normal gallbladder
- Benign prostatic hyperplasia

INTERPRETATION OF THE FINDINGS & FURTHER RECOMMENDATIONS

The liver mass is consistent with neoplastic criteria, i.e., carcinoma or other. Non-neoplastic etiologies, such as severe hyperplasia or granuloma, are thought to be less likely.

Assuming normal clotting status, initial liver mass FNA cytology could be considered. Biopsy of the mass is required for a definitive diagnosis. Complete surgical resectability of the mass is questionable, given the size of the mass and potential involvement of more than one liver lobe.



PATIENT

Qwinci Kostelecky

SPECIES

Canine

BREED

German Wirehaired Pointer

SEX

M

AGE

13 years, 4 months

WEIGHT

54 lbs

INTERPRETED BY

R. McKenzie Daniel,
DVM, DABVP
(Canine and Feline)

IMAGING PERFORMED BY

Dr. Jessie Evoniuk

HOSPITAL NAME

State Avenue Vet
Clinic

REFERRING VET

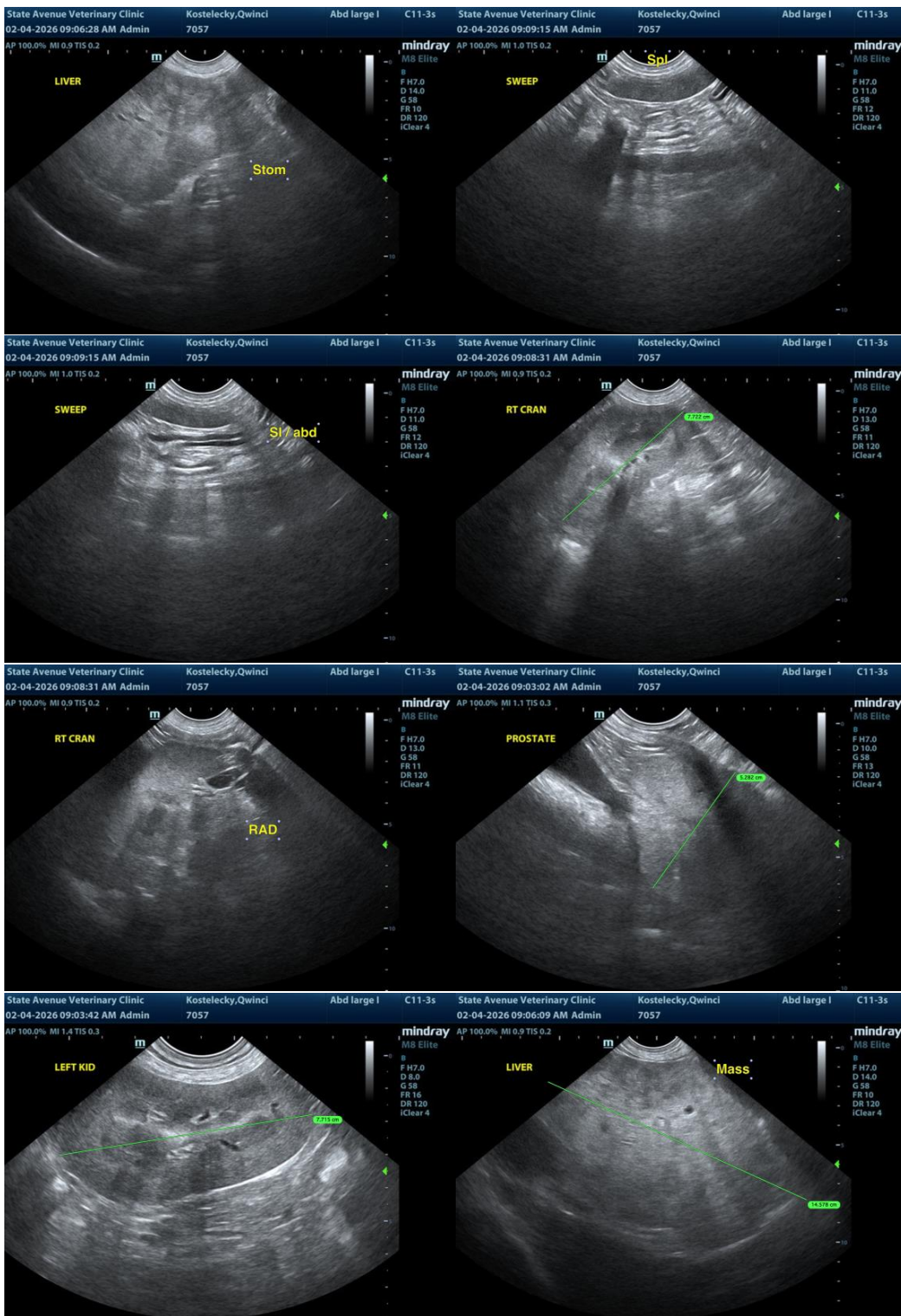
Dr. Jessie Evoniuk

INVOICE

10610

DATE

2/4/26





PATIENT

Qwinci Kostelecky

SPECIES

Canine

BREED

German Wirehaired
Pointer

SEX

M

AGE

13 years, 4 months

WEIGHT

54 lbs

INTERPRETED BY

R. McKenzie Daniel,
DVM, DABVP
(Canine and Feline)

IMAGING PERFORMED BY

Dr. Jessie Evoniuk

HOSPITAL NAME

State Avenue Vet
Clinic

REFERRING VET

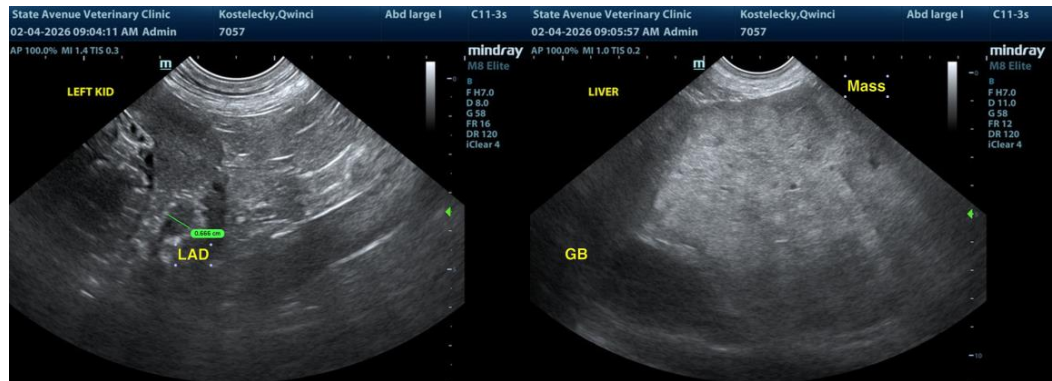
Dr. Jessie Evoniuk

INVOICE

10610

DATE

2/4/26



The information and recommendations provided are based on the images presented by the referring veterinarian/sonographer. No evaluation can be communicated regarding pathology that was not visible in the image/video clips provided.

Thank you for this referral. If the clinical or image interpretation does not parallel your findings or if I can be of any further assistance, please contact me.

R. McKenzie Daniel, DVM, DABVP (Canine/Feline Practice)
info@sonopath.com