

## PATIENT

Marlie Kushibiki

## SPECIES

Canine

## BREED

Dachshund

## SEX

Spayed Female

## AGE

8 Years

## WEIGHT

31 pounds

## INTERPRETED BY

R. McKenzie Daniel,  
DVM, DABVP (Canine  
/ Feline Practice)

## IMAGING PERFORMED BY

Arielle Roldan CVT

## HOSPITAL NAME

Milford Animal  
Hospital

## REFERRING VET

Dr. Sean Grasso DVM

## INVOICE

13600

## DATE

02/04/26

## PRESENTING CLINICAL SIGNS

- Presented for mass removal surgery, Grade II/VI heart murmur ausculted (no history of murmur noted), no other pertinent history. Holding off on surgery/anesthesia to ensure no contraindications.

Abnormal PE/Chem/CBC/UA Results: CBC/Chem 15/ T4/Lytes/ SDMA: all wnl ProBNP: WNL TNL abnormal : 0.41 (normal <0.1)

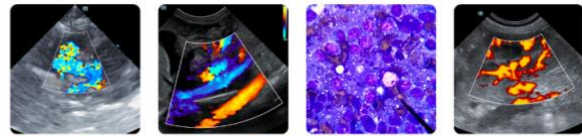
## ULTRASONOGRAPHIC EXAMINATION OF THE HEART

CANINE CARDIAC PARAMETERS	MR VMAX (m/s)	TR VMAX (m/s)	LA/AO (M-Mode)	LA/AO (Heart Base; Swe)	FS (%)	EF (%)	EPSS (cm)
NORMAL PARAMETER	4.5-5.5	<2.7	1.3	Up to 1.6	28-40	40-100	<0.6
PATIENT	5.0	--	NM	1.5	45	78	0.32
CANINE CARDIAC PARAMETERS	HR (BPM)	AV VMAX (m/s)	PV MAX (m/s)	BODY WEIGHT (lbs)	LAD LA MAX 4 Chamber	LVIDd Avg; 2D and m-mode short axis (cm)	LVIDs Avg; 2D and m-mode short axis (cm)
NORMAL PARAMETER	50-100	0.7-1.7	0.7-1.6				
PATIENT	NM	1.4	0.7	31.0	3.7	4.0	--

## Cardiac Presentation

The echocardiogram in this patient demonstrated normal **left atrial** size based on 2 different LA measurement methods. The cranial and caudal **mitral** valve leaflets presented mild thickening consistent with mild endocardiosis. Doppler indicated mild to moderate eccentric MR. The **left ventricle** presented thicknesses with linear contour and was not dilated nor restricted. The **myocardium** presented normal echogenicity without subjective evidence of significant fibrotic or ischemic disease. **Contractility** of the ventricular walls was adequate and in normal range for this patient evidenced by the fractional shortening measurement and subjective evaluation of the different regions of the myocardium. The **left ventricular outflow** tract demonstrated normal laminar flow and subjective structural integrity. The **right atrium** and auricle revealed normal size, structure and content. No evidence of masses was noted or chamber overload. **Tricuspid** valvular assessment demonstrated adequate linear morphology. The **right ventricle** was of normal size (1/3 diameter of LV), chordae structure, myocardial echogenicity and thickness. **Pulmonic** tract assessment revealed normal valve structure, laminar flow, and diameter (approx.1:1 pa/ao ratio). No visible **pericardial** or free pleura fluid was noted. No echographically detectable evidence of cardiac / pericardial tumors was visible.

## ULTRASONOGRAPHIC FINDINGS



**PATIENT**

- Chronic mitral valve disease (B1).

Marlie Kushibiki

**INTERPRETATION OF THE FINDINGS & FURTHER RECOMMENDATIONS**

**SPECIES**

The cause of the murmur is chronic degenerative valvular changes with secondary eccentric mitral valve insufficiency. The lack of left atrial enlargement implies that the risk of complication secondary to mitral valve insufficiency is low at this time and, without current clinical signs, indicates that medical therapy is not required. Prognosis is considered variable and sonographic monitoring is recommended.

Canine

**BREED**

Recheck echo cardiogram is suggested in 6-12 months, sooner if clinical signs arise. Anesthetic risk is considered mild without anesthetic contraindications. Suggested anesthetic protocol may include opioid or Benzodiazepine pre-med, induction with Propofol or Alfaxalone, and appropriate gas anesthesia with avoidance of alpha 2 agonists.

Dachshund

**SEX**

Spayed Female

**AGE**

8 Years

**WEIGHT**

31 pounds

**INTERPRETED BY**

R. McKenzie Daniel, DVM, DABVP (Canine / Feline Practice)

**IMAGING PERFORMED BY**

Arielle Roldan CVT

**HOSPITAL NAME**

Milford Animal Hospital

**REFERRING VET**

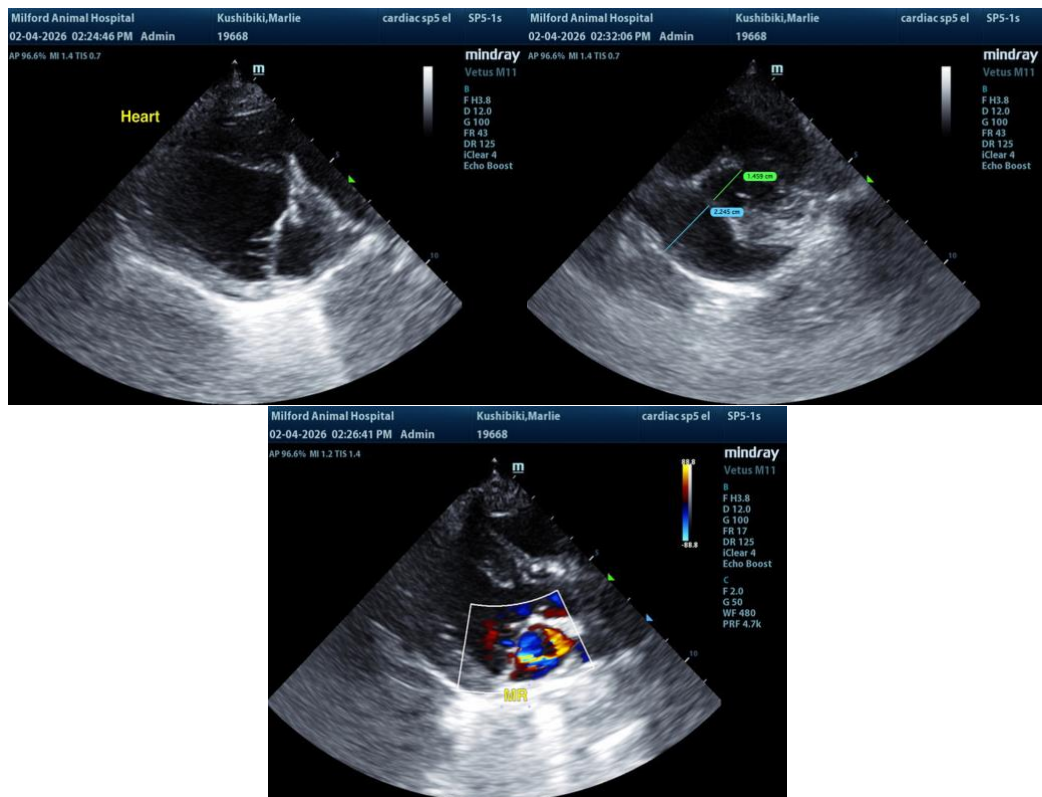
Dr. Sean Grasso DVM

**INVOICE**

13600

**DATE**

02/04/26

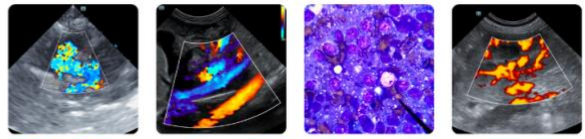


The information and recommendations provided are based on the images presented by the referring veterinarian/sonographer. No evaluation can be communicated regarding pathology that was not visible in the image/video clips provided.

Thank you for this referral. If the clinical or image interpretation does not parallel your findings or if I can be of any further assistance, please contact me.

R. McKenzie Daniel, DVM, DABVP (Canine / Feline Practice)

[info@SonoPath.com](mailto:info@SonoPath.com)



## PATIENT

Marlie Kushibiki

## SPECIES

Canine

## BREED

Dachshund

## SEX

Spayed Female

## AGE

8 Years

## WEIGHT

31 pounds

## INTERPRETED BY

R. McKenzie Daniel,  
DVM, DABVP (Canine  
/ Feline Practice)

## IMAGING PERFORMED BY

Arielle Roldan CVT

## HOSPITAL NAME

Milford Animal  
Hospital

## REFERRING VET

Dr. Sean Grasso DVM

## INVOICE

13600

## DATE

02/04/26