



PATIENT PRESENTING CLINICAL SIGNS

Sisi Dogan

History:

SPECIES

Feline

- Wellness US per O mild lethargy x2weeks/ some tenesmus. rads unremarkable- rectal wnl

Abnormal PE/Chem/CBC/UA Results: UA wnl

BREED

DLH

SEX

Female Spayed

AGE

9y

WEIGHT

11 lbs

ULTRASONOGRAPHIC EXAMINATION OF THE HEART & ABDOMEN

FELINE CARDIAC PARAMETERS	BODY WEIGHT (kg)	HR (BPM)	IVSd (cm)	LVIDd (cm)	LVWd (cm)	FS (%)	EF (%)
NORMAL PARAMETER	-----	150-240	0.3-0.6	1.0-2.1	0.25-0.6	35-67	80-100
PATIENT	--	NM	0.5	1.3	0.48	50	42
FELINE CARDIAC PARAMETERS	LA/AO (M-mode)	LA/AO HEART BASE (Sisson)	LAD LA MAX 4 Chamber		LVOT VEL. (m/s)	RVOT VEL. (m/s)	IVRT (m/)
NORMAL PARAMETER	<1.5	1.6	0.7-1.7		<1.6	<1.3	40-60
PATIENT	--	1.3	1.3		1.0	0.75	--
Adapted from June Boon, Veterinary Echocardiography, 1998 Sisson D et al. JVIM 1991; 5: 232, Jacobs et al. Am J Vet Res 1985; 46:1705							

INTERPRETED BY

R. McKenzie Daniel, DVM, DABVP (Canine and Feline)

IMAGING PERFORMED BY

Kerri Becker

HOSPITAL NAME

All Creatures Denville

REFERRING VET

Dr. Ashmore

INVOICE

13159

DATE

2/3/26

Cardiac Presentation

The echocardiogram in this patient demonstrated normal **left atrial** size based on 3 separate LA measurements. The cranial and caudal **mitral** valve leaflets presented normal linear structure and kinetics. The **left ventricle** presented normal thicknesses with linear contour and was not dilated nor restricted. The **myocardium** presented normal echogenicity without subjective evidence of significant fibrotic or ischemic disease. **Contractility** of the ventricular walls was adequate and in normal range for this patient evidenced by the fractional shortening measurement and subjective evaluation of the different regions and angles of the myocardium. The **left ventricular outflow** tract demonstrated normal laminar flow and subjective structural integrity. The **right atrium** and auricle revealed normal size, structure and content. No evidence of masses was noted or chamber overload. **Tricuspid** valvular assessment demonstrated adequate linear morphology and kinetics. The **right ventricle** was of normal size (1/3 diameter of LV), chordae structure, myocardial echogenicity and thickness. **Pulmonic** tract assessment revealed normal valve structure, laminar flow, and diameter (approx. 1:1 pa/ao ratio). No visible **pericardial** or free pleura fluid was noted or extra cardiac pathology in the visible planes. The cranial **mediastinum** and **pericardial** regions were free of masses in the visible window.



PATIENT

Sisi Dogan

SPECIES

Feline

BREED

DLH

SEX

Female Spayed

AGE

9y

WEIGHT

11 lbs

INTERPRETED BY

R. McKenzie Daniel,
 DVM, DABVP
 (Canine and Feline)

IMAGING PERFORMED BY

Kerri Becker

HOSPITAL NAME

All Creatures Denville

REFERRING VET

Dr. Ashmore

INVOICE

13159

DATE

2/3/26

Urinary System

The urinary bladder, trigone, cystourethral junction, and visible pelvic urethra to a depth of 2.0 cm exhibited normal thickness and tone. Anechoic urine was present in the lumen with no uroliths or sediment. The ureteral papillae were normal. The ureters were not visible which is normal. No evidence of inflammatory or neoplastic changes were noted.

The area of the iliac trifurcation was free of pathology.

Normal size and margination was present in the kidneys. A normal 1:3 cortex / medulla ratio and normal corticomedullary definition were maintained. The echogenicity of the cortex was similar to or slightly less than normal liver parenchyma while the medulla echogenicity was hypoechoic to the cortex with no evidence of pelvic dilation. The left kidney measured 3.4 cm in length. The right kidney measured 3.6 cm in length.

Adrenal Glands

The left adrenal gland was uniform in size and contour with a uniformly hypoechoic parenchyma. The left adrenal gland measured 0.30 cm. The right adrenal gland was uniform in size and contour with a uniformly hypoechoic parenchyma. The right adrenal gland measured 0.33 cm.

Spleen

The spleen exhibited a finely textured and homogenous parenchyma which was hyperechoic to the liver and renal cortical parenchyma. The capsule was smooth and regular without apparent expansion. The splenic vasculature at the hilus was normal in volume with no evidence of congestion or thrombosis. Acute to chronic inflammatory, neoplastic, or benign parenchyma changes were not noted.

Liver

The liver was subjectively normal in size, structure, and contour. The liver parenchyma was uniform and hypoechoic to the spleen with a mild coarse echotexture. The hepatic and portal vasculature were normal in appearance without signs of congestion. The gallbladder was non-distended in size with thin walls and primarily anechoic luminal content. The cystic and common bile ducts were normal.

Gastrointestinal

The stomach presented intact wall layering with a normal wall layer ratio. The lumen of the stomach was empty with no signs of ileus, obstruction or foreign material.

The small intestine presented intact wall layering with 1:3 muscularis/mucosa ratio. The lumen of the small intestine was empty with no signs of ileus, obstruction or foreign material.

Normal intact visible colon wall, the colon was non-distended in size containing formed fecal matter.

Pancreas

The parenchyma of the left limb, body and right limb of the pancreas presented isoechoic to the adjacent omental fat. A normal curvilinear capsule contour of the pancreas was present. The visible pancreatic duct was normal. No signs of active inflammation or neoplastic disease was evident.

Free Abdomen

No overt lymphadenopathy or peritoneal effusion was present.



PATIENT

Sisi Dogan

SPECIES

Feline

BREED

DLH

SEX

Female Spayed

AGE

9y

WEIGHT

11 lbs

INTERPRETED BY

R. McKenzie Daniel,
 DVM, DABVP
 (Canine and Feline)

IMAGING PERFORMED BY

Kerri Becker

HOSPITAL NAME

All Creatures Denville

REFERRING VET

Dr. Ashmore

INVOICE

13159

DATE

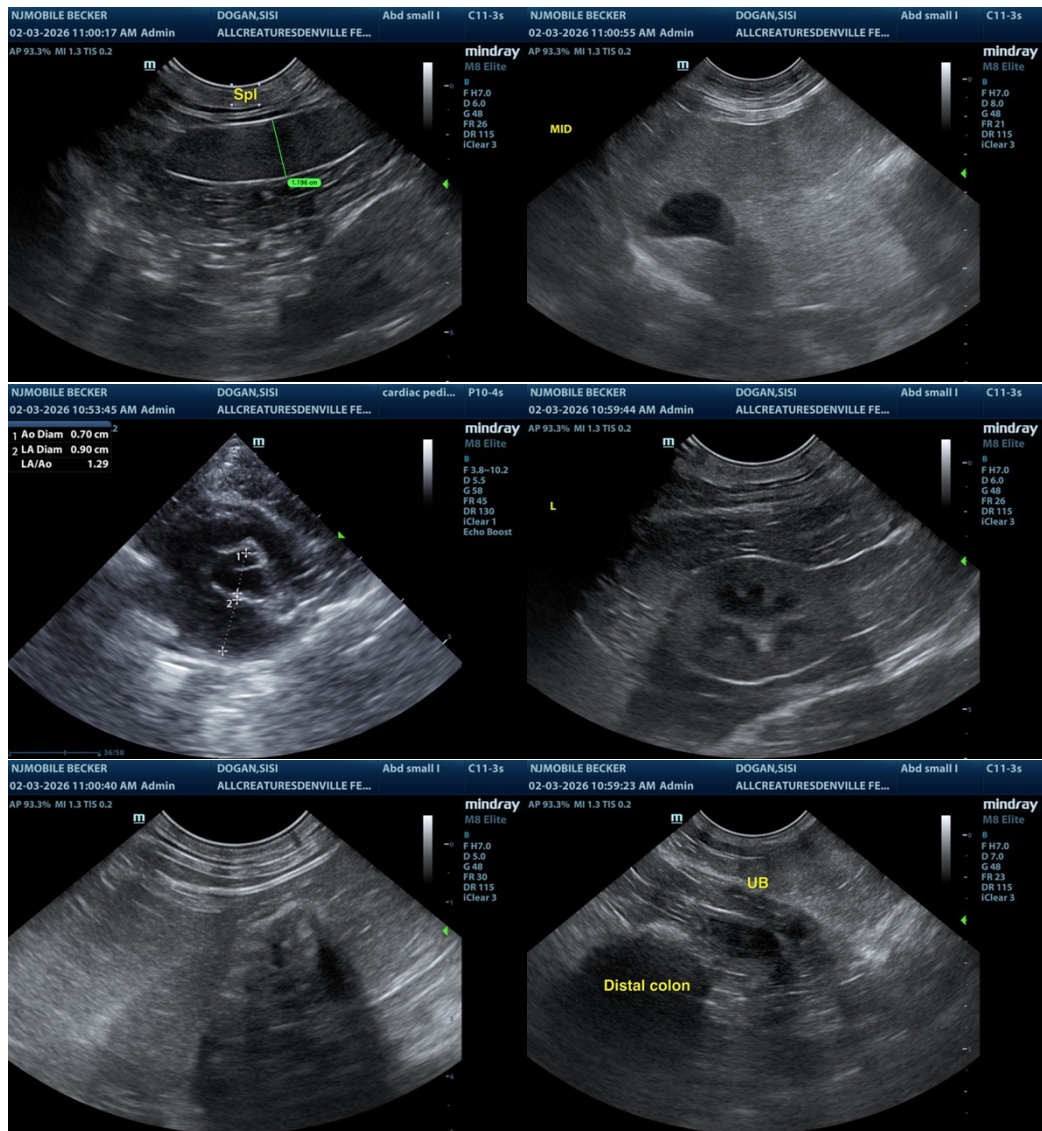
2/3/26

ULTRASONOGRAPHIC FINDINGS

- Normal echocardiogram
- Sonographically normal abdomen

INTERPRETATION OF THE FINDINGS & FURTHER RECOMMENDATIONS

No evidence of cardiac or abdominal visceral pathology. Full lab work and thoracic radiographs may be considered if not done.





PATIENT

Sisi Dogan

SPECIES

Feline

BREED

DLH

SEX

Female Spayed

AGE

9y

WEIGHT

11 lbs

INTERPRETED BY

R. McKenzie Daniel,
 DVM, DABVP
 (Canine and Feline)

IMAGING PERFORMED BY

Kerri Becker

HOSPITAL NAME

All Creatures Denville

REFERRING VET

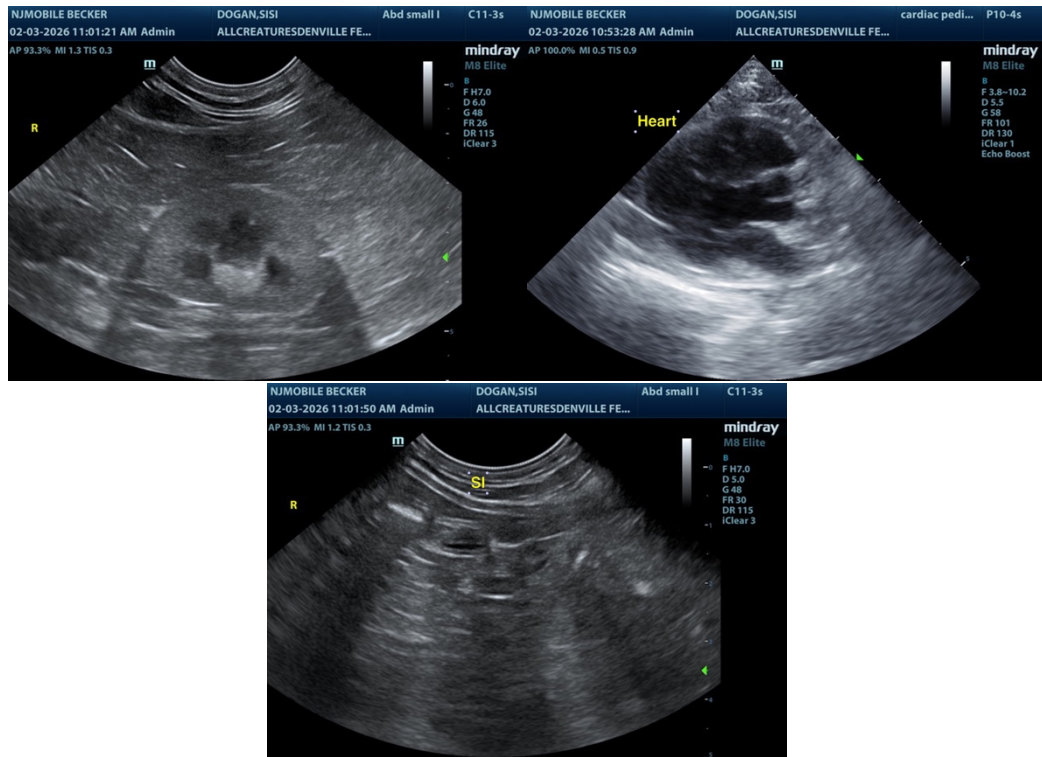
Dr. Ashmore

INVOICE

13159

DATE

2/3/26



The information and recommendations provided are based on the images presented by the referring veterinarian/sonographer. No evaluation can be communicated regarding pathology that was not visible in the image/video clips provided.

Thank you for this referral. If the clinical or image interpretation does not parallel your findings or if I can be of any further assistance, please contact me.

R. McKenzie Daniel, DVM, DABVP (Canine / Feline Practice)

info@sonopath.com