



PATIENT

Scarlett Pineda

SPECIES

Feline

BREED

DSH

SEX

FS

AGE

4y, 9m

WEIGHT

4.65 kgs

INTERPRETED BY

R. McKenzie Daniel,
 DVM, DABVP
 (Canine and Feline)

IMAGING PERFORMED BY

Vincent Ravancho, CVT

HOSPITAL NAME

Bond Vet Union

REFERRING VET

Dr. Bedoya/Berkowitz

INVOICE

10608

DATE

2/3/26

PRESENTING CLINICAL SIGNS

- Hx of spayed but exhibiting female intact behaviors
- Anti-Mullerian Hormone Positive
- Would like to evaluate for ovarian remnants and location

Abnormal PE/Chem/CBC/UA Results: Positive Anti-Mullerian Hormone

ULTRASONOGRAPHIC EXAMINATION OF THE ABDOMEN

Urinary System

The urinary bladder, trigone, cystourethral junction, and visible pelvic urethra to a depth of 2.0 cm exhibited normal thickness and tone. Primarily anechoic urine was present in the lumen. Moderate, particulate, dependent to nondependent sediment was present without evidence of calculus formation. The ureteral papillae were normal. The ureters were not visible which is normal. No evidence of inflammatory or neoplastic mural changes were noted.

The visualized uterine remnant was sonographically normal measuring 0.5 cm diameter. The bilateral ovarian fossa were free of definitive ovarian remnant or other pathology.

The area of the iliac trifurcation was free of pathology.

Normal size and margination were present in the kidneys. A normal 1:3 cortex / medulla ratio and normal corticomedullary definition were maintained. The echogenicity of the cortex was similar to or slightly less than normal liver parenchyma while the medulla echogenicity was hypoechoic to the cortex with no evidence of pelvic dilation. The left kidney measured 3.5 cm in length. The right kidney measured 3.7 cm in length.

Adrenal Glands

The area of the left and right adrenal glands was free of pathology.

Spleen

The spleen exhibited a finely textured and homogenous parenchyma which was hyperechoic to the liver and renal cortical parenchyma. The capsule was smooth and regular without apparent expansion. The splenic vasculature at the hilus was normal in volume with no evidence of congestion or thrombosis. Acute to chronic inflammatory, neoplastic, or benign parenchyma changes were not noted.

Liver/ Gallbladder

The liver was subjectively normal in size, structure, and contour. Normal hepatic vascular volume was present. The liver parenchyma was uniform and hypoechoic to the spleen with a mild coarse echotexture. The hepatic and portal vasculature were normal in appearance without signs of congestion. The gallbladder was non-distended in size with thin walls and primarily anechoic luminal content. The cystic and common bile ducts were normal.



PATIENT

Scarlett Pineda

SPECIES

Feline

BREED

DSH

SEX

FS

AGE

4y, 9m

WEIGHT

4.65 kgs

INTERPRETED BY

R. McKenzie Daniel,
DVM, DABVP
(Canine and Feline)

IMAGING PERFORMED BY

Vincent Ravancho, CVT

HOSPITAL NAME

Bond Vet Union

REFERRING VET

Dr. Bedoya/Berkowitz

INVOICE

10608

DATE

2/3/26

Gastrointestinal

The stomach presented intact wall layering with a normal wall layer ratio. The lumen of the stomach was empty without evidence of retained ingesta, fluid, or foreign material.

The small intestine presented intact wall layering with 1:3 muscularis/mucosa ratio. The lumen of the small intestine was empty with no signs of ileus, obstruction, or foreign material.

Normal visible colon wall layers were present with formed feces in lumen.

Pancreas

The parenchyma of the left limb, body, and right limb of the pancreas presented isoechoic to the adjacent omental fat. A normal curvilinear capsule contour of the pancreas was present. The visible pancreatic duct was normal. No signs of active inflammation or neoplastic disease were evident.

Free Abdomen

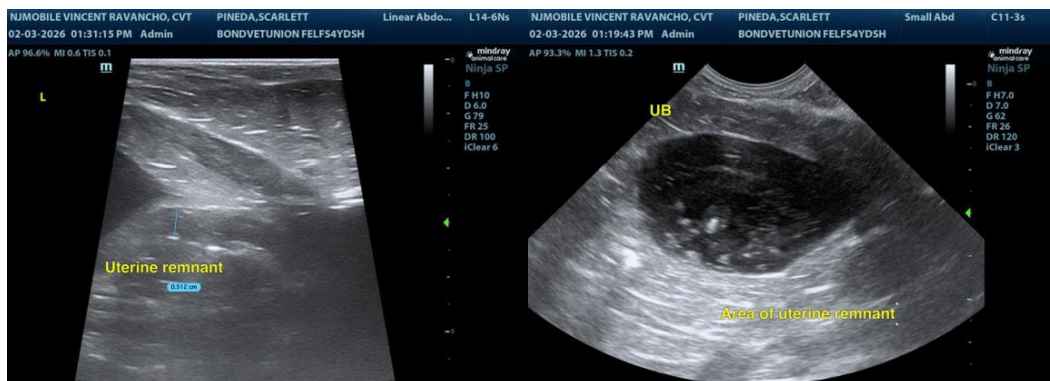
No overt lymphadenopathy or peritoneal effusion was present.

ULTRASONOGRAPHIC FINDINGS

- Moderate urine sediment
- Overtly normal uterine remnant

INTERPRETATION OF THE FINDINGS & FURTHER RECOMMENDATIONS

An obvious left or right ovarian remnant was not definitively visualized. This may be owing to small ovarian remnant size in conjunction with general feline ovarian size. Recheck sonogram could be considered during estrus behavior. Likewise, in conjunction with positive anti-mullerian hormone test, exploratory laparotomy with gross inspection of the left and right ovarian fossa could be considered. Correlation with urinalysis +/- urine C/S, if evidence of inflammatory sediment, is recommended.





PATIENT

Scarlett Pineda

SPECIES

Feline

BREED

DSH

SEX

FS

AGE

4y, 9m

WEIGHT

4.65 kgs

INTERPRETED BY

R. McKenzie Daniel,
 DVM, DABVP
 (Canine and Feline)

IMAGING PERFORMED BY

Vincent Ravancho, CVT

HOSPITAL NAME

Bond Vet Union

REFERRING VET

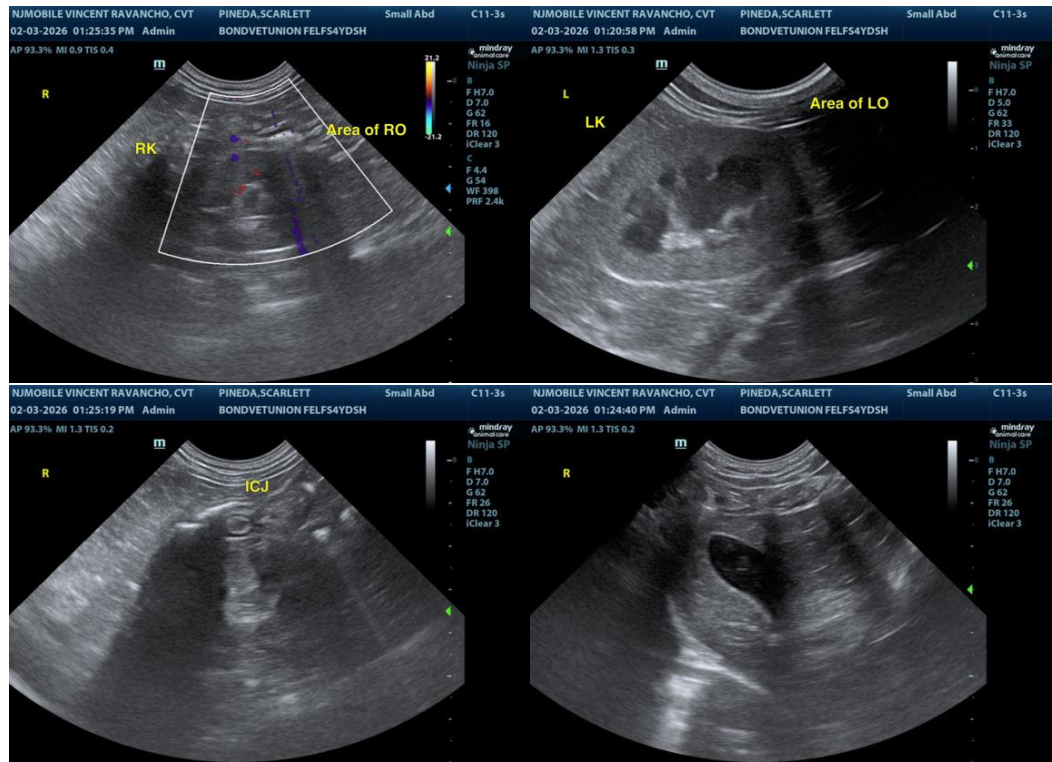
Dr. Bedoya/Berkowitz

INVOICE

10608

DATE

2/3/26



The information and recommendations provided are based on the images presented by the referring veterinarian/sonographer. No evaluation can be communicated regarding pathology that was not visible in the image/video clips provided.

Thank you for this referral. If the clinical or image interpretation does not parallel your findings or if I can be of any further assistance, please contact me.

R. McKenzie Daniel, DVM, DABVP (Canine/Feline Practice)
info@sonopath.com