



PATIENT

Norman McGlade

SPECIES

Canine

BREED

Chihuahua

SEX

Male Neutered

AGE

8y 6m

WEIGHT

7.8 lbs

INTERPRETED BY

R. McKenzie Daniel,
 DVM, DABVP
 (Canine and Feline)

IMAGING PERFORMED BY

Becca Hamilton

HOSPITAL NAME

Cummings VH

REFERRING VET

Dr. Sweney

INVOICE

13161

DATE

2/3/26

PRESENTING CLINICAL SIGNS

History:

- Frequent coughing
- Cardiac heart murmur grade 4/6
- Meds: Gabapentin susp, Trazadone, Credelia quatro
- Given 0.05 ml Torb for scan

ULTRASONOGRAPHIC EXAMINATION OF THE HEART

CANINE CARDIAC PARAMETERS	MR VMAX (m/s)	TR VMAX (m/s)	LA/AO (M-Mode)	LA/AO (Heart Base; Swe)	FS (%)	EF (%)	EPSS (cm)
NORMAL PARAMETER	4.5-5.5	<2.7	1.3	Up to 1.6	28-40	40-100	<0.6
PATIENT	5.9	--	--	1.4	50	82	0.1
CANINE CARDIAC PARAMETERS	HR (BPM)	AV VMAX (m/s)	PV MAX (m/s)	BODY WEIGHT (kg)	LAD LA MAX 4 Chamber	LVIDd Avg; 2D and m-mode short axis (cm)	LVIDs Avg; 2D and m-mode short axis (cm)
NORMAL PARAMETER	50-100	0.7-1.7	0.7-1.6				
PATIENT	NM	1.8	0.9	--	2.2	2.4	--

Cardiac Presentation

The echocardiogram in this patient demonstrated normal **left atrial** size based on 2 different LA measurement methods. The cranial and caudal **mitral** valve leaflets presented thickening consistent with endocardiosis. Doppler indicated measurable moderate eccentric MR. MR velocity measured 5.9 m/s. The **left ventricle** presented thicknesses with linear contour and was not dilated nor restricted. The **myocardium** presented normal echogenicity without subjective evidence of significant fibrotic or ischemic disease. **Contractility** of the ventricular walls was adequate and in normal range for this patient evidenced by the fractional shortening measurement and subjective evaluation of the different regions of the myocardium. The **left ventricular outflow** tract demonstrated normal laminar flow and subjective structural integrity. Mild aortic valve insufficiency noted on doppler measuring 4.0 m/s. The **right atrium** and auricle revealed normal size, structure and content. No evidence of masses was noted or chamber overload. **Tricuspid** valvular assessment demonstrated adequate linear morphology. The **right ventricle** was of normal size (1/3 diameter of LV), chordae structure, myocardial echogenicity and thickness. **Pulmonic** tract assessment revealed normal valve structure, laminar flow, and diameter (approx.1:1 pa/ao ratio). No visible **pericardial** or free pleura fluid was noted. No echographically detectable evidence of cardiac / pericardial tumors was visible. No evidence of arrythmia or hepatic congestion.



PATIENT

Norman McGlade

SPECIES

Canine

BREED

Chihuahua

SEX

Male Neutered

AGE

8y 6m

WEIGHT

7.8 lbs

INTERPRETED BY

R. McKenzie Daniel,
 DVM, DABVP
 (Canine and Feline)

IMAGING PERFORMED BY

Becca Hamilton

HOSPITAL NAME

Cummings VH

REFERRING VET

Dr. Sweney

INVOICE

13161

DATE

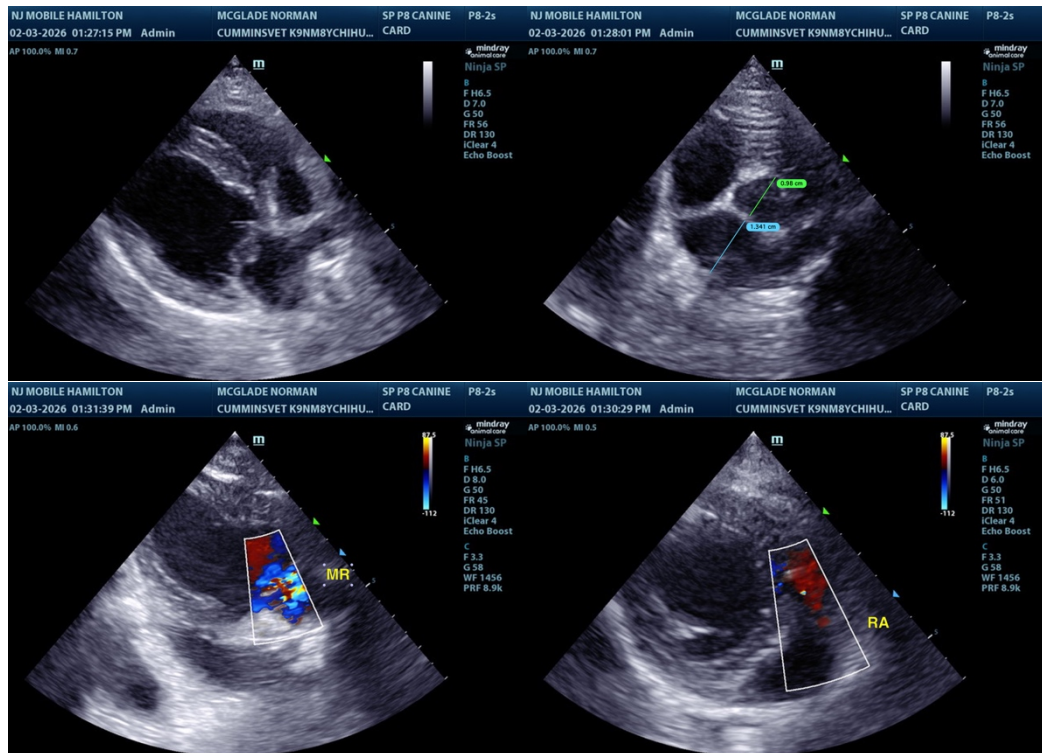
2/3/26

ULTRASONOGRAPHIC FINDINGS

- Compensated mitral valve disease (B1)
- Mild aortic valve insufficiency

INTERPRETATION OF THE FINDINGS & FURTHER RECOMMENDATIONS

The cause of the murmur is chronic degenerative valvular changes with secondary eccentric mitral valve insufficiency. The lack of left atrial enlargement implies that the risk of complication secondary to mitral valve insufficiency is low at this time and, without current clinical signs, indicates that medical therapy is not required. No additional clinical issues such as pulmonary hypertension. The coughing in this patient is non-cardiogenic in origin. Correlation with thoracic radiographs and assessment of lower airway disease is indicated. Prognosis is considered variable and sonographic monitoring is recommended. Recheck echo cardiogram is suggested in 6-12 months, sooner if clinical signs arise. No anesthetic contraindications. Suggested anesthetic protocol may include opioid or Benzodiazepine pre-med, induction with Propofol or Alfaxalone, and appropriate gas anesthesia with avoidance of alpha 2 agonists.



The information and recommendations provided are based on the images presented by the referring veterinarian/sonographer. No evaluation can be communicated regarding pathology that was not visible in the image/video clips provided.

Thank you for this referral. If the clinical or image interpretation does not parallel your findings or if I



PATIENT

Norman McGlade

SPECIES

Canine

BREED

Chihuahua

SEX

Male Neutered

AGE

8y 6m

WEIGHT

7.8 lbs

INTERPRETED BY

R. McKenzie Daniel,
DVM, DABVP
(Canine and Feline)

**IMAGING
PERFORMED BY**

Becca Hamilton

HOSPITAL NAME

Cummings VH

REFERRING VET

Dr. Sweney

INVOICE

13161

DATE

2/3/26

can be of any further assistance, please contact me.

R. McKenzie Daniel, DVM, DABVP (Canine / Feline Practice)

info@sonopath.com