



PATIENT

Freya Tiffany

SPECIES

Feline

BREED

DSH

SEX

FI

AGE

7mo

WEIGHT

6lb

INTERPRETED BY

R. McKenzie Daniel,
DVM, DABVP
(Canine and Feline)

IMAGING PERFORMED BY

Dr. Andrea Nason

HOSPITAL NAME

Caravan Vet

REFERRING VET

Dr. Andrea Nason

INVOICE

23764

DATE

02/03/2026

PRESENTING CLINICAL SIGNS

- Patient is presenting for routine spay + umbilical hernia repair
- Grade 4 parasternal heart murmur first heard at 2 month exam, no murmur on follow up exam at 3 months, grade 3 at 4 months. Full cardiac work up declined. Owner is aware of the limitations of this screen.

Abnormal PE/Chem/CBC/UA Results: CBC, Chem WNL ProBNP 24 No UA, T4 on file

PRE-ANESTHETIC ECHOCARDIOGRAM

8 efficiency clips from SDEP protocol provided. All four chambers revealed normal volumes and contractility. No evidence of volume overload or pressure overload. No pericardial or pleural effusion. No gross abnormalities that would preclude anesthesia.

INTERPRETATION OF THE FINDINGS & FURTHER RECOMMENDATIONS

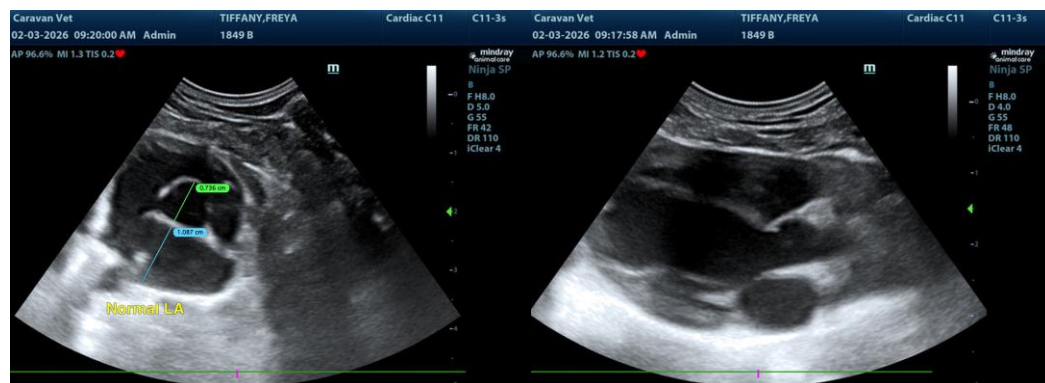
Category 1: Anesthetic risk is considered normal to mild. No gross abnormalities noted on

SDEP Screening Echo to contraindicate anesthesia. Minimal to no left atrial enlargement noted on images presented.

a. However, judicious fluid administration is advised with careful RR/RE monitoring to screen for fluid overload.

b. Monitoring of blood pressure, SpO₂, CO₂, and auscultation of heart and lungs during anesthesia should be done during every procedure.

Suggested anesthetic protocol may include opioid or Benzodiazepine pre-med, induction with Propofol or Alfaxalone, and appropriate gas anesthesia with avoidance of alpha 2 agonists.



The information and recommendations provided are based on the images presented by the referring veterinarian/sonographer. No evaluation can be communicated regarding pathology that was not visible in the image/video clips provided.



PATIENT

Freya Tiffany

Thank you for this referral. If the clinical or image interpretation does not parallel your findings or if I can be of any further assistance, please contact me.

SPECIES

Feline

R. McKenzie Daniel, DVM, DABVP (Canine/Feline Practice)

info@sonopath.com

BREED

DSH

SEX

FI

AGE

7mo

WEIGHT

6lb

INTERPRETED BY

R. McKenzie Daniel,
DVM, DABVP
(Canine and Feline)

IMAGING PERFORMED BY

Dr. Andrea Nason

HOSPITAL NAME

Caravan Vet

REFERRING VET

Dr. Andrea Nason

INVOICE 23764

DATE
02/03/2026