



PATIENT

Szala Shiloh

SPECIES

Canine

BREED

Golden Retriever

SEX

MN

AGE

7

WEIGHT

80

INTERPRETED BY

R. McKenzie Daniel,
DVM, DABVP
(Canine and Feline)

IMAGING PERFORMED BY

Chelsea Pastor and
Jeanine French

HOSPITAL NAME

Fredon AH

REFERRING VET

Dr. Linda Grau

INVOICE

13151

DATE

2/3/22

PRESENTING CLINICAL SIGNS

Chronic Loose stool, weight loss, vomiting

Abnormal PE/Chem/CBC/UA Results: mild pale mm, neut: 13817 SDMA: 17 TP: 2.7 ALB: 1.2 GLOB: 1.5

ULTRASONOGRAPHIC EXAMINATION OF THE ABDOMEN

Urinary System

The urinary bladder, trigone, and cystourethral junction exhibited normal thickness and tone. Anechoic urine was present in the lumen with no uroliths or sediment. The ureteral papillae were normal. The ureters were not visible which is normal. No evidence of inflammatory or neoplastic changes was noted.

No overt pathology was noted in the area of the residual prostate, although indistinctly visualized.

The area of the aortic trifurcation was free of pathology.

Normal size and margination were present in the kidneys. A normal 1:3 cortex / medulla ratio and normal corticomedullary definition were maintained. The echogenicity of the cortex was similar to or slightly less than normal liver parenchyma while the medulla echogenicity was hypoechoic to the cortex with no evidence of pelvic dilation. The left kidney measured 6.1 cm in length. The right kidney measured 6.1 cm in length.

Adrenal Glands

The left adrenal gland was uniform in size and contour with a uniformly hypoechoic parenchyma. The left adrenal gland measured 2.3 cm length x 0.43 cm width at the caudal pole. The right adrenal gland was uniform in size and contour with a uniformly hypoechoic parenchyma. The right adrenal gland measured 3.1 cm length x 0.53 cm width at the caudal pole.

Spleen

The spleen exhibited a finely textured and homogenous parenchyma which was hyperechoic to the liver and renal cortical parenchyma. The capsule was smooth and regular without apparent expansion. The splenic vasculature at the hilus was normal in volume with no evidence of congestion or thrombosis. Acute to chronic inflammatory, neoplastic, or benign parenchyma changes were not noted.

Liver/ Gallbladder

The liver presented normal in size. The hepatic parenchyma revealed diffuse reduced echogenicity compared to the spleen and renal cortical parenchyma with a mild coarse echotexture. Increased portal vein prominence was evident. The capsule of the liver was normal in margination. Distinct masses or nodules were not evident. The hepatic and portal vasculature were normal in appearance. The gallbladder was non-distended in size with primarily anechoic luminal content. The cystic and common bile ducts were normal.

Gastrointestinal

The stomach exhibited prominent to indistinct generalized wall layering. The stomach was moderately distended with retained primarily anechoic to mildly echogenic fluid with potential for minor retained,



PATIENT	nonspecific hyperechoic ingesta and chyme. No overt evidence of mechanical pyloric outflow obstruction was noted. The pylorus wall width measured 1.3 cm.
Szala Shiloh	
SPECIES	The small intestine presented intact wall layering and primarily maintained a 1:3 muscularis/mucosa ratio with subjective generalized propensity for decreased small intestinal mural echogenicity. Minor segmental nonobstructive duodenojejunal ileus pattern was present. No overt evidence of loss of intestinal wall layering, small Intestinal mechanical obstruction, or overt small intestinal foreign material.
Canine	
BREED	The colon was primarily empty containing small amounts of nonformed fecal matter. The colon walls were sonographically unremarkable.
Golden Retriever	
SEX	<i>Pancreas</i>
MN	The parenchyma of the left limb, body, and right limb of the pancreas presented isoechoic to the adjacent omental fat. A normal curvilinear capsule contour of the pancreas was present. The visible pancreatic duct was normal. No signs of active inflammation or neoplastic disease were evident.
AGE	<i>Free Abdomen</i>
7	Generalized, primarily peri intestinal hyperechoic mesentery and small pockets of scant peritoneal free fluid were present.
WEIGHT	Intermittent jejunal lymph nodes were present. The lymph nodes were essentially isoechoic to adjacent omentum without evidence of peripheral inflammation and maintaining a normal width: length ratio (<0.5). An example lymph node measured 0.73 cm width.
80	
INTERPRETED BY	ULTRASONOGRAPHIC FINDINGS
R. McKenzie Daniel, DVM, DABVP (Canine and Feline)	<ul style="list-style-type: none"> • Generalized gastroenteropathy exhibiting moderate gastric stasis / hypomotility and segmental minor nonobstructive duodenojejunal ileus • Associated intermittent nonspecific yet subjectively benign / reactive jejunal lymph nodes • Generalized primarily peri intestinal reactive mesentery and scant peritoneal free fluid
IMAGING PERFORMED BY	INTERPRETATION OF THE FINDINGS & FURTHER RECOMMENDATIONS
Chelsea Pastor and Jeanine French	Given the presence of panhyperproteinemia in the face of chronic gastrointestinal signs and weight loss, nonspecific protein-losing enteropathy is suspected. Overt evidence of mechanical pyloric outflow obstruction or small intestinal foreign material was not definitively evident. Potential for minor retained ingesta / chyme with possible small amount of nonspecific foreign material in the stomach cannot be definitively excluded, yet is thought less likely. Considerations could include generalized inflammatory bowel disease, lymphangiectasia, or infiltrative gastroenteropathy (neoplasia, fungal, or other).
HOSPITAL NAME	
Fredon AH	
REFERRING VET	
Dr. Linda Grau	
INVOICE	
13151	Ideally, gastrointestinal biopsies would be acquired for histopathology and definitive diagnosis, yet likely contraindicated at this time given the albumin levels (<2.0). A GI panel to include PLI/TLI/Cobalamin/Folate is recommended. Fresh fecal analysis to rule out parasitic ova / Giardia is recommended if not done. Empirical therapy for protein-losing enteropathy with as-needed gastrointestinal support would be appropriate with goal of albumin levels (≥2.0).
DATE	
2/3/22	

Adrenal screening with resting cortisol may be considered to rule out occult Addison's Disease in this case.



PATIENT

Szala Shiloh

SPECIES

Canine

BREED

Golden Retriever

SEX

MN

AGE

7

WEIGHT

80

Part or all of this protocol may be considered based on your clinical impression of the patient:

OBJECTIVE: keep albumin levels > 2 g/dl, avoid thromboembolism and cavitory effusions, monitor concurrent PLN (Wheaton Terrier PLE/PLN) and liver disease:

Plasma 10 mL / kilogram IV over 4 hours

Or **Human albumin** 2 ml/kg/h over 10 hours. Total daily volume 20.l/kg/day

And Colloids/Hetastarch

10 to 20 mL per kilogram per day and dogs

10 to 15 mL per kilogram per day cats

(Can bolus first 1/3 of dose over 15 minutes)

& maintain on LRS maintenance otherwise.

Metronidazole (10-20 mg/kg po bid)

Famotidine 1 mg/kg lv 1m po dc Sid /bid

Sucralfate 0.5-1 g po tid dogs, 0.5 g bid cats in slurry Or **Misoprostol** 1-5 ug/kg po tid

Diet: Highly digestible high quality protein, low fiber, low fat diet (< 15% of dry matter). Hydrolyzed protein or novel protein. Purina HA or Royal Canine HP or similar.

Prednisone or prednisolone 2 mg/kg bid x 3-5 days then 2 mg/kg sid. **Chlorambucil** in refractive severe IBD/alimentary lymphoma cases (monitor cbc for rare bone marrow suppression) 4 mg/m² Q 24-48 hours.

Cobalamine (B12) 250-1500 ug/dog weekly x 6 weeks.

Calcium supplementation if necessary.

Aspirin 0.5-1 mg/kg/day or **Clopidrel** (Plavix) 1-5 mg/kg/day.

INTERPRETED BY

R. McKenzie Daniel,
DVM, DABVP
(Canine and Feline)

IMAGING PERFORMED BY

Chelsea Pastor and
Jeanine French

HOSPITAL NAME

Fredon AH

REFERRING VET

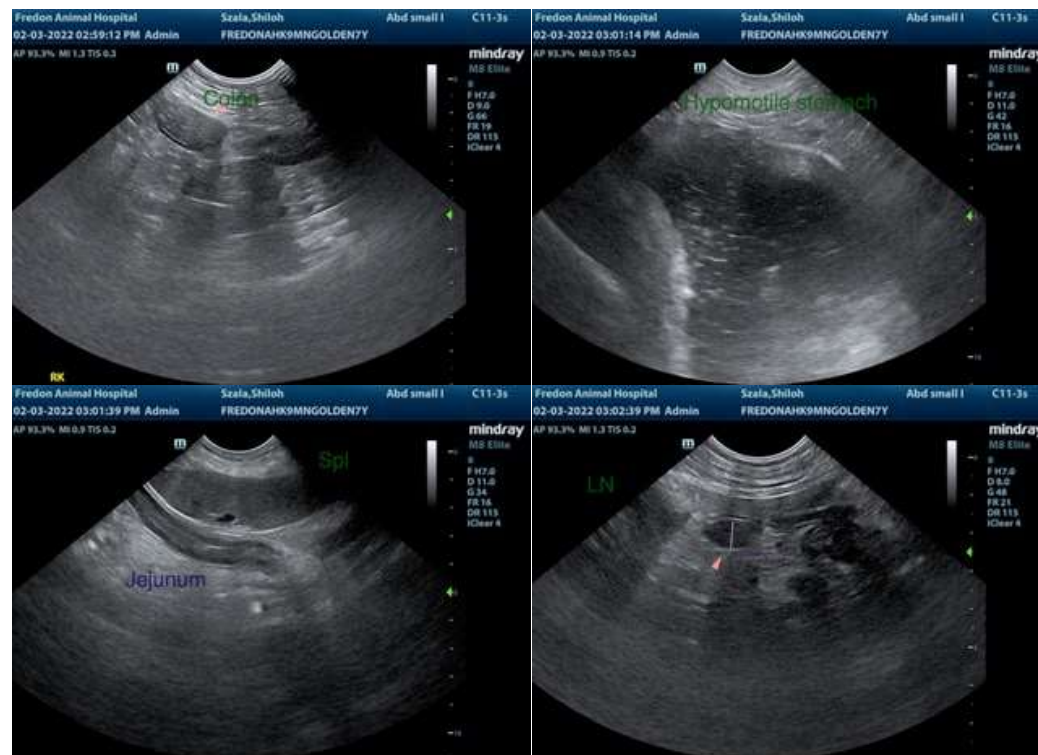
Dr. Linda Grau

INVOICE

13151

DATE

2/3/22





PATIENT

Szala Shiloh

SPECIES

Canine

BREED

Golden Retriever

SEX

MN

AGE

7

WEIGHT

80

INTERPRETED BY

R. McKenzie Daniel,
DVM, DABVP
(Canine and Feline)

IMAGING PERFORMED BY

Chelsea Pastor and
Jeanine French

HOSPITAL NAME

Fredon AH

REFERRING VET

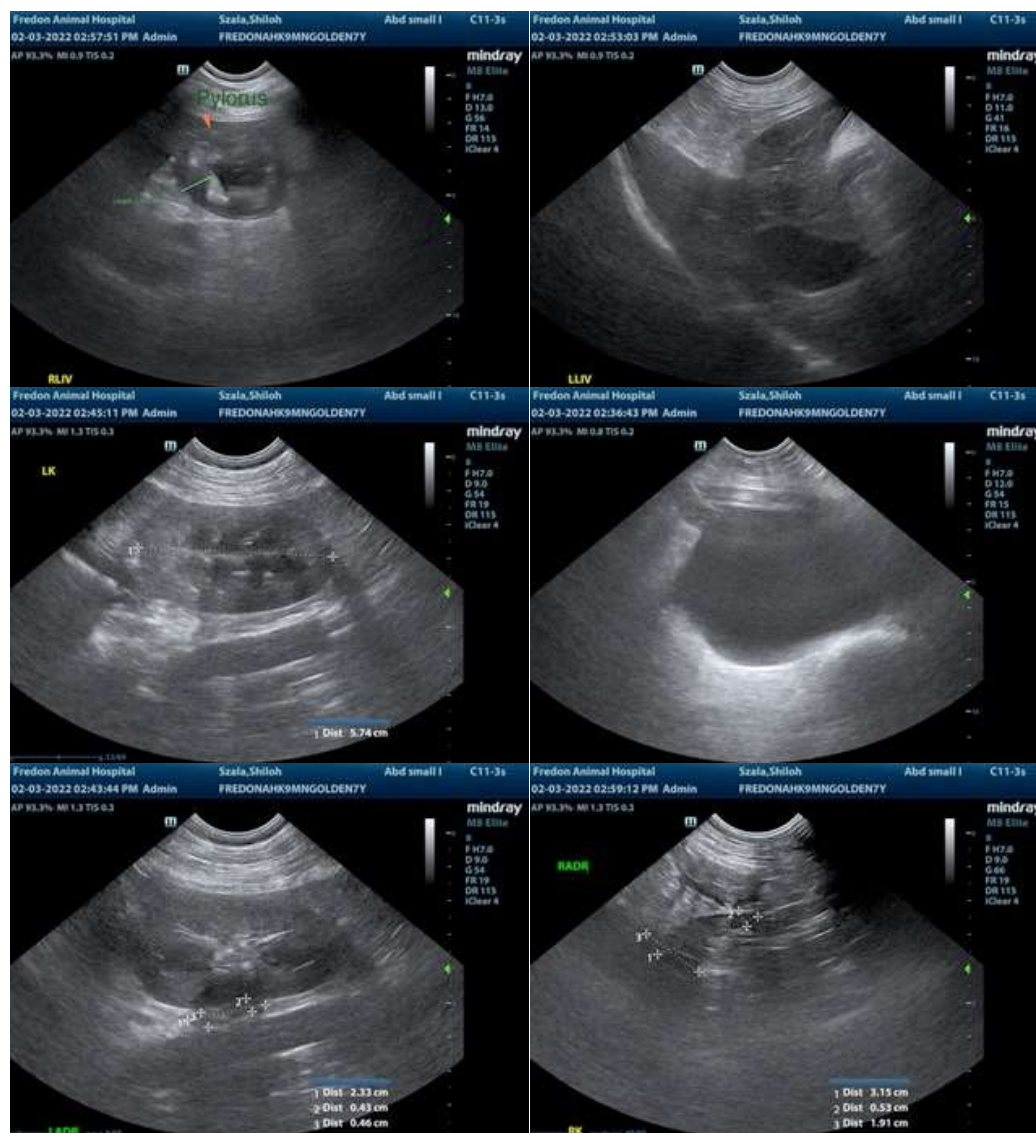
Dr. Linda Grau

INVOICE

13151

DATE

2/3/22



The information and recommendations provided are based on the images presented by the referring veterinarian/sonographer. No evaluation can be communicated regarding pathology that was not visible in the image/video clips provided.

Thank you for this referral. If the clinical or image interpretation does not parallel your findings or if I can be of any further assistance please contact me.

R. McKenzie Daniel, DVM, DABVP (Canine / Feline Practice)
info@SonoPath.com