SonoPath
Clinical Sonography & Telecytology

EDUCATIONAL TELECONSULTATION SERVICES™

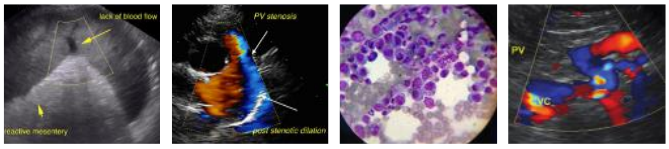

SonoPath.com™
1-800-838-4268 info@sonopath.com

PATIENT
Mira Allen

SPECIES
Canine

BREED
Lab

SEX
Spayed Female

AGE
10

WEIGHT
60

INTERPRETED BY
R. McKenzie Daniel, DVM, DABVP (Canine and Feline)

IMAGING PERFORMED BY
Robyn Lantz

HOSPITAL NAME
Eastgate VC

REFERRING VET
Josiah Moses

INVOICE
21340

DATE
2/28/23

PRESENTING CLINICAL SIGNS

History: ADR about a week ago but acting normal now. Routine/annual lab work senior was performed and all wnl except ALT was ~220. Relatives of patient (all brothers in litter) have passed away, one from suspected toxin and two to neoplasia. Ruling out possible neoplasia, other liver disease.
Abnormal PE/Chem/CBC/UA Results: Routine/annual lab work senior was performed and all wnl except ALT was ~220. Urine and fecal pending.

ULTRASONOGRAPHIC EXAMINATION OF THE ABDOMEN

Urinary System

The urinary bladder, trigone, cystourethral junction, and visible pelvic urethra to a depth of 4.0 cm exhibited normal thickness and tone. Anechoic urine was present in the lumen with no uroliths or sediment. The ureteral papillae were normal. The ureters were not visible which is normal. No evidence of inflammatory or neoplastic changes were noted.

The area of the aortic trifurcation was free of pathology.

Normal size and margination were present in the kidneys. A normal 1:3 cortex / medulla ratio was maintained. The medulla and cortices were uniform in texture with some increased echogenicity and mild loss of corticomedullary symmetry and definition expected for the age of the patient. No evidence of pelvic dilation was present. The left kidney measured 6.3 cm in length. The right kidney measured 6.1 cm in length.

Adrenal Glands

The left adrenal gland was indistinctly visualized with subjective subtle parenchyma heterogeneity. No evidence of left adrenal tumors. The left adrenal gland subjectively measured 0.59 cm width in the caudal pole.

The right adrenal gland was not definitively visualized. No obvious pathology in the area of the right adrenal gland.

Spleen

The spleen exhibited primarily finely textured parenchyma which was hyperechoic to the liver and renal cortical parenchyma. Mild generalized parenchyma heterogeneity was present without evidence of nodular changes. The capsule was smooth and regular without apparent expansion. The splenic vasculature at the hilus was normal in volume with no evidence of congestion or thrombosis. The parenchymal heterogeneity is likely consistent with benign changes such as extramedullary hematopoiesis or age-related remodeling with minor potential for inflammatory or neoplastic disease. No splenic masses were noted.

Liver

The liver was subjectively normal in size, structure, and contour. The liver parenchyma was uniform and hypoechoic to the spleen with a mild coarse echotexture. The hepatic and portal vasculature were normal in appearance without signs of congestion.

The gallbladder was non-distended in size with thin walls and primarily anechoic luminal content. The cystic and common bile ducts were normal.

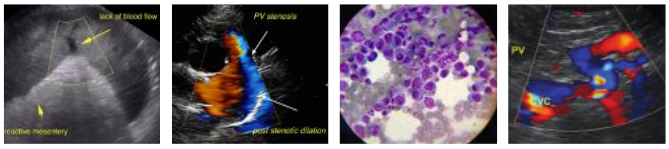

SonoPath.com™
1-800-838-4268 info@sonopath.com

PATIENT

Mira Allen

SPECIES

Canine

BREED

Lab

SEX

Spayed Female

AGE

10

WEIGHT

60

INTERPRETED BY

R. McKenzie Daniel, DVM, DABVP (Canine and Feline)

IMAGING PERFORMED BY

Robyn Lantz

HOSPITAL NAME

Eastgate VC

REFERRING VET

Josiah Moses

INVOICE

21340

DATE

2/28/23

Gastrointestinal

The stomach presented intact wall layering with a normal wall layer ratio. The lumen of the stomach was empty with no signs of ileus, obstruction or foreign material.

The small intestine presented intact wall layering with 1:3 muscularis/mucosa ratio. The lumen of the small intestine was empty with no signs of ileus, obstruction or foreign material.

Normal visible colon wall layers were present with apparent formed feces in lumen.

Pancreas

The parenchyma of the left limb, body and right limb of the pancreas presented isoechoic to the adjacent omental fat. A normal curvilinear capsule contour of the pancreas was present. The visible pancreatic duct was normal. No signs of active inflammation or neoplastic disease was evident.

Free Abdomen

No omental masses, lymphadenopathy or peritoneal effusion was present.

ULTRASONOGRAPHIC FINDINGS

- Low grade hepatopathy- benign
- Sonographically normal gallbladder
- Mild age-related spleen- benign
- Mild age-related kidneys

INTERPRETATION OF THE FINDINGS & FURTHER RECOMMENDATIONS

Largely mild geriatric abdomen without sonographic evidence of significant visceral pathology. Potential for low grade nonspecific hepatitis or other inflammatory hepatopathy given the ALT elevation is possible. Further assessment may include screening FNA cytology, assuming normal clotting status +/- Leptospirosis titers/PCR if evidence of persistent/progressive hepatic enzyme elevations. Hepatosupportive medications may prove beneficial. Correlation with pending urinalysis and fecal testing is recommended. No evidence of intraabdominal neoplastic criteria.

SonoPath

Clinical Sonography & Telecytology

EDUCATIONAL TELECONSULTATION SERVICES™

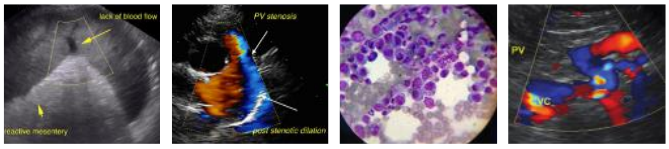

SonoPath.com™
1-800-838-4268 info@sonopath.com

PATIENT

Mira Allen

SPECIES

Canine

BREED

Lab

SEX

Spayed Female

AGE

10

WEIGHT

60

INTERPRETED BY

R. McKenzie Daniel, DVM, DABVP (Canine and Feline)

IMAGING PERFORMED BY

Robyn Lantz

HOSPITAL NAME

Eastgate VC

REFERRING VET

Josiah Moses

INVOICE

21340

DATE

2/28/23

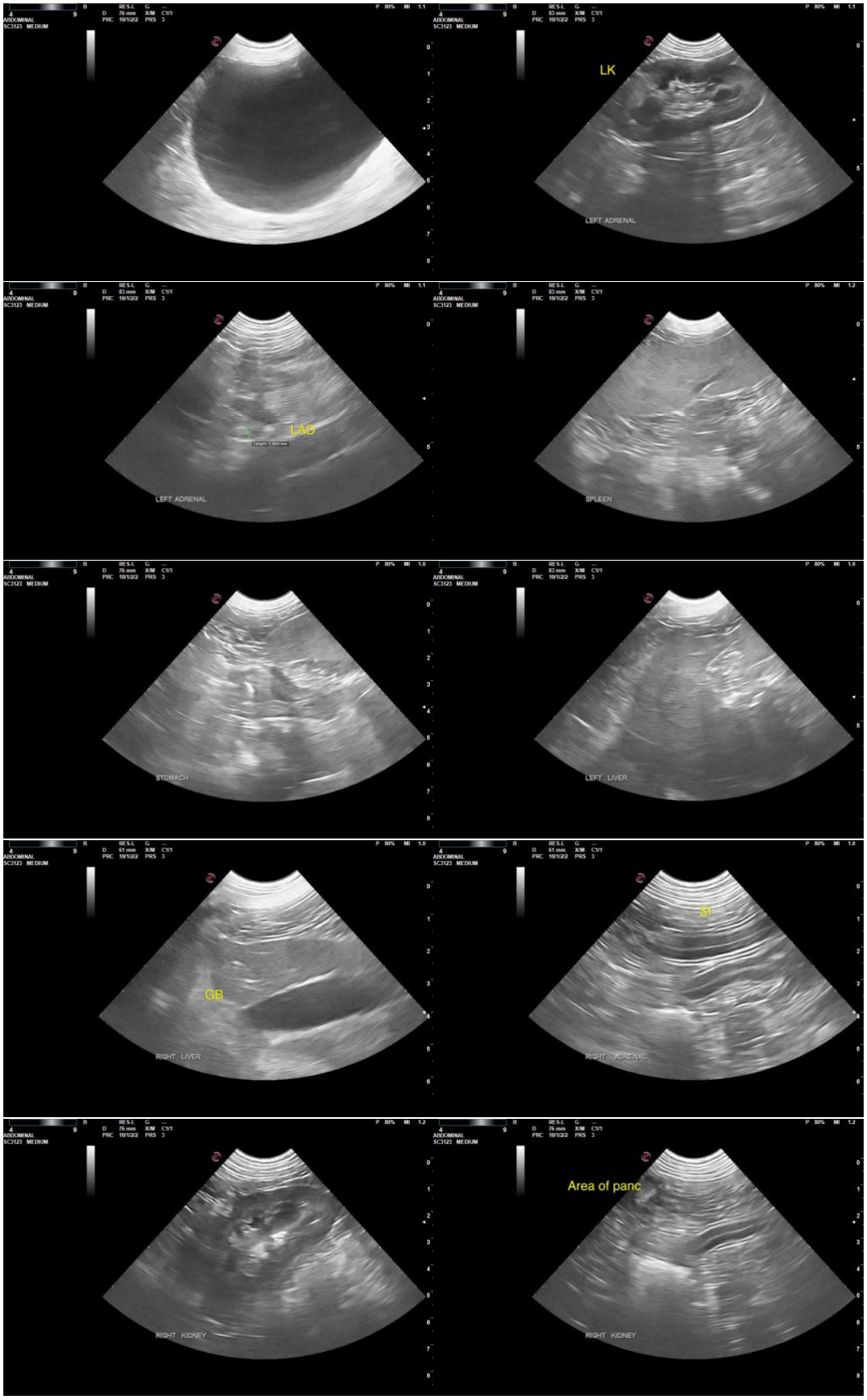

SonoPath
Clinical Sonography & Telecytology
EDUCATIONAL TELECONSULTATION SERVICES™

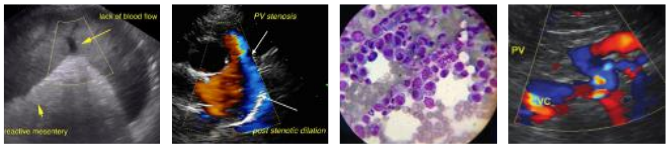

SonoPath.com™
1-800-838-4268 info@sonopath.com

PATIENT

Mira Allen

SPECIES

Canine

BREED

Lab

SEX

Spayed Female

AGE

10

WEIGHT

60

INTERPRETED BY

R. McKenzie Daniel, DVM, DABVP (Canine and Feline)

IMAGING PERFORMED BY

Robyn Lantz

HOSPITAL NAME

Eastgate VC

REFERRING VET

Josiah Moses

INVOICE

21340

DATE

2/28/23

The information and recommendations provided are based on the images presented by the referring veterinarian. No evaluation can be communicated regarding pathology that was not visible in the image/video clips provided.

Thank you for this referral. If the clinical or image interpretation does not parallel your findings or if I can be of any further assistance please contact me.

R. McKenzie Daniel, DVM, DABVP (Canine / Feline Practice)
info@SonoPath.com