**PATIENT**

Charmin Szuminski

SPECIES

Canine

BREED

Maltese

SEX

MN

AGE

9yr

WEIGHT

17lb

INTERPRETED BYR. McKenzie Daniel,
DVM, DABVP
(Canine and Feline)**IMAGING PERFORMED BY**

Sarah Pender CVT

HOSPITAL NAME

SVS Imaging QC

REFERRING VET

Dr. Doerscher

INVOICE

13063ag

DATE

02/28/2023

PRESENTING CLINICAL SIGNS

Presented for some labored and distressed breathing over the weekend. Seems distressed and like he can't get comfortable.

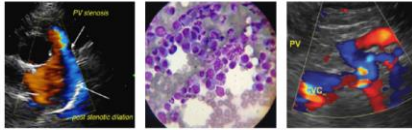
Abnormal PE/Chem/CBC/UA Results: Breathing behavior not witnessed during exam, unable to elicit anything abnormal with respirations. Cranial abdominal organomegaly or mass effect appreciated on exam. New heart murmur grade 3/6 also noted on exam, last exam in November did not note presence of heart murmur. Lab abnormalities: ALP was at 188 in 5/2022 and 367 yesterday - no other sig lab abnormalities. Rads do suggest hepatomegaly and possibly an irregular opacity just caudal to stomach on lateral projections and spleen was not readily visible. Pertinent question: Please advise re: heart murmur and indication for medical therapy. Also, is there anything concerning of the liver and/or spleen?

ULTRASONOGRAPHIC EXAMINATION OF THE ABDOMEN AND HEART

CANINE CARDIAC PARAMETERS	MR VMAX (m/s)	TR VMAX (m/s)	LA/AO (Boon method)	LA/AO (Heart Base; Swe)	FS (%)	EF (%)	EPSS (cm)
NORMAL PARAMETER	4.5-5.5	<2.7	1.3	<1.3	28-40	40-100	<0.6
PATIENT	5.0			1.5	50.3	83.2	0.26
CANINE CARDIAC PARAMETERS	HR (BPM)	AV VMAX (m/s)	PV MAX (m/s)	BODY WEIGHT (kg)	LA 2D short axis Base view (cm)	LVIDd Avg; 2D and m- mode short axis (cm)	LVIDs Avg; 2D and m- mode short axis (cm)
NORMAL PARAMETER	50-100	0.7-1.7	0.7-1.6				
PATIENT	107	1.5	1.2		2.9	2.8	

Cardiac Presentation

The echocardiogram in this patient demonstrated normal left atrial size based on 3 different LA measurement methods. Chamber volumes and echogenicity were normal. The cranial and caudal mitral valve leaflets presented mild thickening consistent with endocardiosis. Doppler indicated measurable mild eccentric insufficiency. The left ventricle presented thicknesses with linear contour and was not dilated nor restricted. The myocardium presented normal echogenicity without subjective evidence of significant fibrotic or ischemic disease. Contractility of the ventricular walls was adequate and in normal range for this patient evidenced by the fractional shortening measurement and subjective evaluation of the different regions of the myocardium. The left ventricular outflow tract demonstrated normal laminar flow and subjective structural integrity. The right atrium and auricle revealed normal size, structure and content. No evidence of masses was noted or chamber overload. Tricuspid valvular assessment demonstrated adequate linear morphology. The right ventricle was of normal size (1/3 diameter of LV), chordae structure, myocardial echogenicity and thickness. Pulmonic tract assessment revealed normal valve structure, laminar flow, and diameter (approx.1:1 pa/ao ratio). No visible pericardial or free pleura fluid was noted. No echographically detectable evidence of infiltrative

**PATIENT**

Charmin Szuminski

disease was visible. The cranial mediastinum and pericardial regions were free of masses in the visible window.

Urinary System**SPECIES**

Canine

The urinary bladder, trigone, cystourethral junction, and visible pelvic urethra to a depth of 3 cm exhibited normal thickness and tone. Anechoic urine was present in the lumen with no uroliths or sediment. The ureteral papillae were normal. The ureters were not visible which is normal. No evidence of inflammatory or neoplastic changes were noted.

BREED

Maltese

Normal size and margination were present in the kidneys. A normal 1:3 cortex / medulla ratio and normal corticomedullary definition were maintained. The echogenicity of the cortex was similar to or slightly less than normal liver parenchyma while the medulla echogenicity was hypoechoic to the cortex with no evidence of pelvic dilation. The left kidney measured 4.9 cm in length. The right kidney measured 4.6 cm in length.

SEX

MN

The area of the aortic trifurcation was free of pathology.

The area of the residual prostate appeared normal and free of pathology.

AGE

9yr

Adrenal Glands

The bilateral adrenal glands were mildly prominent in size with no adrenal tumors. The left adrenal gland measured 0.66 cm width at the caudal pole and 1.7 cm length. The right adrenal gland was uniform in size and contour with a uniformly hypoechoic parenchyma. The right adrenal gland measured 0.61 cm width at the caudal pole and 0.6 cm length.

WEIGHT

17lb

Spleen

The spleen exhibited normal size and contour with a finely textured and homogenous parenchyma which was hyperechoic to the liver and renal cortical parenchyma. Subtle to discrete hyperechoic perihilar nodules were present consistent with emerging myelolipomas, an example measuring 0.35 cm in diameter. The splenic vasculature at the hilus was normal in volume with no evidence of congestion or thrombosis.

INTERPRETED BY

R. McKenzie Daniel,
DVM, DABVP
(Canine and Feline)

Liver/Gallbladder

The liver presented enlarged in size. The parenchyma of the liver was subjectively normal in echogenicity compared to the spleen and renal cortices. The liver parenchyma was uniform with a mildly coarse echotexture. The capsule of the liver was symmetrically rounded to mildly swollen in margination. The hepatic and portal vasculature were normal in appearance without signs of congestion. The gallbladder was non-distended in size with primarily anechoic luminal content and mild non-organized echogenic debris. No evidence of gallbladder or peripheral gallbladder inflammation was present. The cystic and common bile ducts were normal.

IMAGING PERFORMED BY

Sarah Pender CVT

HOSPITAL NAME

SVS Imaging QC

REFERRING VET

Dr. Doerscher

Gastrointestinal

The stomach presented intact wall layering with a normal wall layer ratio. The lumen of the stomach contained mild retained pyloric fluid with no signs of ileus, obstruction or foreign material.

INVOICE

13063ag

The small intestine presented intact wall layering with 1:3 muscularis/mucosa ratio. The lumen of the small intestine was empty with no signs of ileus, obstruction or foreign material.

Normal visible colon wall layers were present with apparent formed feces in lumen.

DATE

02/28/2023

Pancreas

IMAGING PERFORMED BY

SVS Mobile Imaging KC 816-401-5010
svsimagingkc@gmail.com



EDUCATIONAL TELECONSULTATION SERVICES™

1-800-838-4268 info@sonopath.com SonoPath.com

PATIENT

Charmin Szuminski

The right pancreatic limb exhibited subtle prominent size with minor capsule asymmetry and heterogenous mildly hypoechoic parenchyma.

Free Abdomen**SPECIES**

Canine

No omental masses, overt lymphadenopathy or peritoneal effusion was present.

BREED

Maltese

ULTRASONOGRAPHIC FINDINGS

- Chronic mitral valve disease ACVIM B1
- Mildly prominent heterogenous right pancreas
- Vacuolar hepatopathy pattern-benign
- Minor gallbladder debris (non-mucocele)
- Possible mild gastritis
- Emerging benign splenic nodules

SEX

MN

INTERPRETATION OF THE FINDINGS & FURTHER RECOMMENDATIONS**AGE**

9yr

The lack of left atrial enlargement implies that the risk of complication secondary to mitral valve insufficiency is relatively low at this time and, without current clinical signs, indicates that medical therapy is not required at this stage. The labored/distressed breathing is non-cardiogenic in origin. Prognosis at this stage is variable and serial sonographic monitoring is recommended with a recheck echocardiogram in 8-12 months, sooner if clinical signs suggestive of heart disease develop.

WEIGHT

17lb

Overall, there is no overt evidence of significant abdominal visceral pathology as a definitive cause of the patient's clinical signs. No evidence of neoplastic criteria. The borderline prominent adrenal glands were of unclear significance given the patient's current clinical signs. An adrenal work up could be considered if clinical signs consistent with Cushing's syndrome arise. The potential for low grade pancreatitis may be possible if evidence of cranial abdominal or subxiphoid discomfort on palpation is present. Correlation with a spec cPL could be considered. Assessment for possible extra-abdominal discomfort if not done is recommended. Hepatosupportive medications such as Denamarin +/- Ursodiol may prove beneficial.

INTERPRETED BY

R. McKenzie Daniel,
DVM, DABVP
(Canine and Feline)

IMAGING PERFORMED BY

Sarah Pender CVT

HOSPITAL NAME

SVS Imaging QC

REFERRING VET

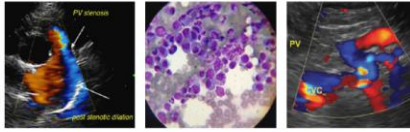
Dr. Doerscher

INVOICE

13063ag

DATE

02/28/2023



PATIENT

Charmin Szuminski

SPECIES

Canine

BREED

Maltese

SEX

MN

AGE

9yr

WEIGHT

17lb

INTERPRETED BY

R. McKenzie Daniel,
DVM, DABVP
(Canine and Feline)

IMAGING PERFORMED BY

Sarah Pender CVT

HOSPITAL NAME

SVS Imaging QC

REFERRING VET

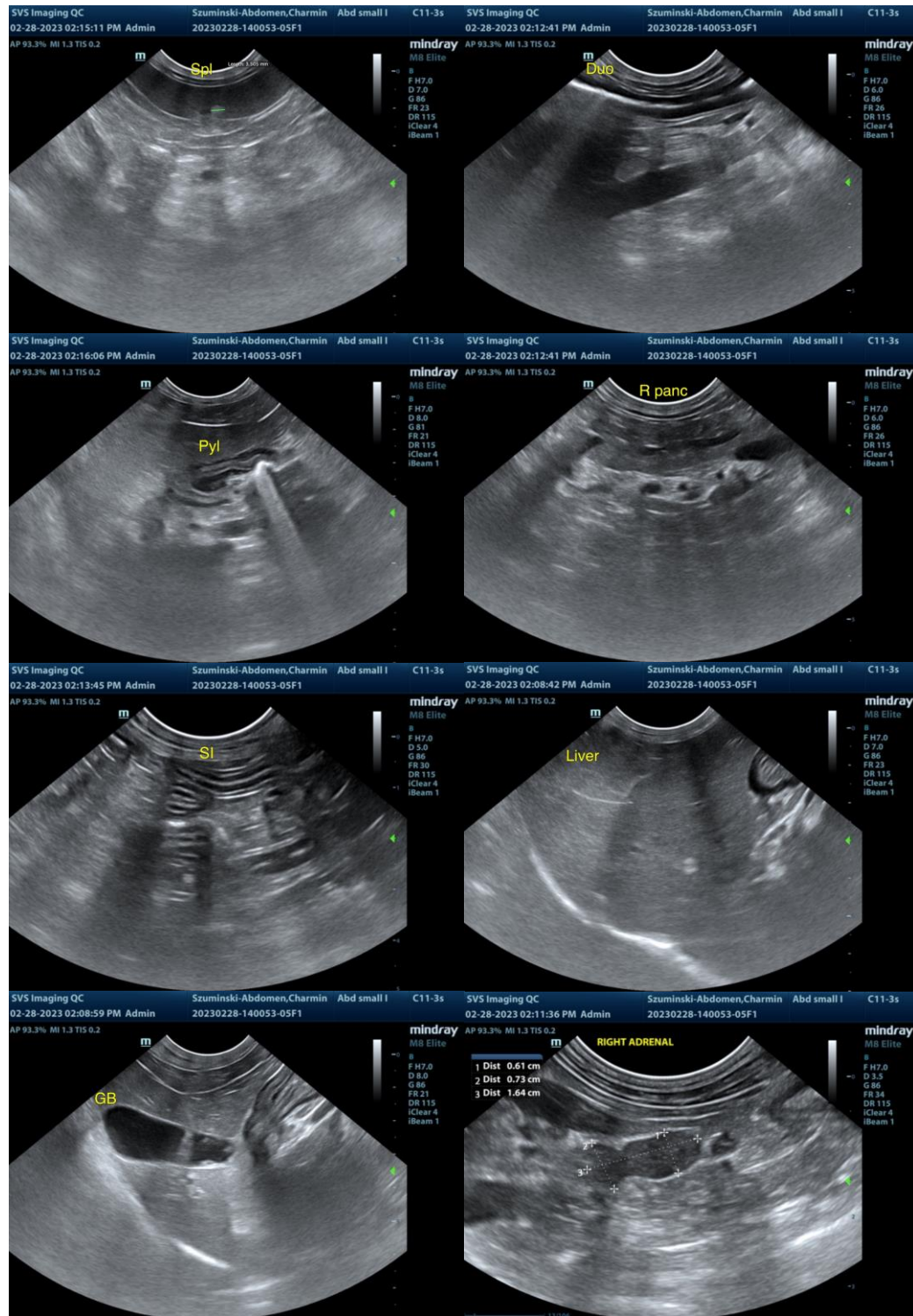
Dr. Doerscher

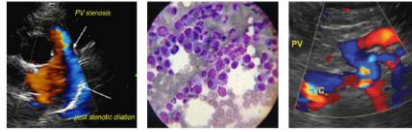
INVOICE

13063ag

DATE

02/28/2023





PATIENT

Charmin Szuminski

SPECIES

Canine

BREED

Maltese

SEX

MN

AGE

9yr

WEIGHT

17lb

INTERPRETED BY

R. McKenzie Daniel,
DVM, DABVP
(Canine and Feline)

IMAGING PERFORMED BY

Sarah Pender CVT

HOSPITAL NAME

SVS Imaging QC

REFERRING VET

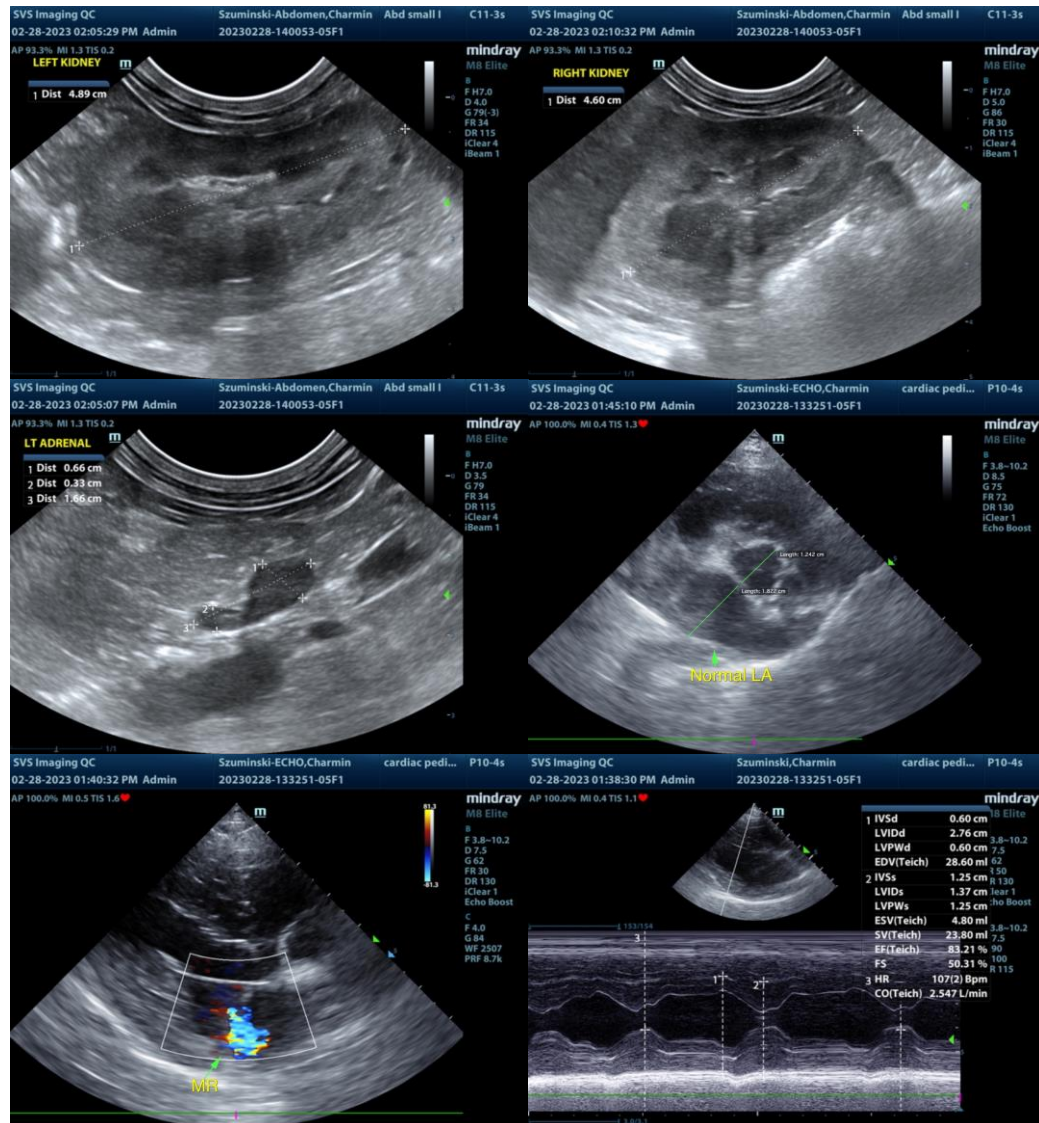
Dr. Doerscher

INVOICE

13063ag

DATE

02/28/2023



The information and recommendations provided are based on the images presented by the referring veterinarian/sonographer. No evaluation can be communicated regarding pathology that was not visible in the image/video clips provided.

Thank you for this referral. If the clinical or image interpretation does not parallel your findings or if I can be of any further assistance please contact me.

R. McKenzie Daniel, DVM, DABVP (Canine / Feline Practice)

info@SonoPath.com