

PATIENT

Quincy Lee Mains

SPECIES

Feline

BREED

DSH

SEX

Neutered Male

AGE

12 Years 6 Months

WEIGHT

10.1 Lbs.

INTERPRETED BY

R. McKenzie Daniel,
DVM, DABVP
(Canine and Feline)

IMAGING PERFORMED BY

Jenna Walsh, CVT

HOSPITAL NAME

Countryside AC

REFERRING VET

Dr. Cox

INVOICE

14132

DATE

2/28/22

PRESENTING CLINICAL SIGNS

History: On 2/25 exam: Was seen at WVH in June 2020 - had BW done, was 13lbs at that time down for 15lb in 2017. Now down to 10lbs. Seems to have steadily lost more recent weight since Fall 2021 - energy level has decreased. No vomiting seen; litter box habits seem WNL. Abdominal mass palpated Current Medications Mirtazapine on Friday

Abnormal PE/Chem/CBC/UA Results: HCT = 33%, Lymphopenia SDMA = 21 TP low at 5.5, ALb 2.1 ALT 11, AST 14 spec fPL is wnl at 2.6 T4 is wnl at 1.7 Urinalysis: spgr 1.029, ph = 6.5

ULTRASONOGRAPHIC EXAMINATION OF THE ABDOMEN

Urinary System

The urinary bladder, trigone, cystourethral junction, and visible pelvic urethra to a depth of 2.0 cm exhibited normal thickness and tone. Anechoic urine was present in the lumen with no uroliths or sediment. The ureteral papillae were normal. The ureters were not visible which is normal. No evidence of inflammatory or neoplastic changes were noted. Aortic trifurcation was normal.

Normal renal size with asymmetrical margination was present in both kidneys. The renal cortex presented uniformly increased in echogenicity with uniform echotexture. The renal cortex appeared to be hypertrophied resulting in an altered cortex: medulla ratio. Mild loss of corticomedullary distinction was also present. The renal medullary volume was subjectively reduced. Potential for emerging to indistinct, nonuniform to mildly echogenic nodule, exhibiting hyperechoic striations were present in the cranial lateral left kidney with mild capsule distortion, potential for associated subtle hypoechoic halo sign around the left kidney possible. The potential emerging left kidney nodule measured 2.3 cm in diameter. The left kidney measured 3.9 cm in length. Concurrent, mildly hypoechoic to nonhomogeneous nodule was present in the cranial lateral right kidney, measuring 0.96 cm. The right kidney measured 4.4 cm in length.

Adrenal Glands

The left adrenal gland was uniform in size and contour with a uniformly hypoechoic parenchyma. The left adrenal gland measured 0.34 cm.

The right adrenal gland was uniform in size and contour with a uniformly hypoechoic parenchyma. The right adrenal gland measured 0.25 cm.

Spleen

The spleen exhibited a finely textured and homogenous parenchyma which was hyperechoic to the liver and renal cortical parenchyma. The capsule was smooth and regular without apparent expansion. The splenic vasculature at the hilus was normal in volume with no evidence of congestion or thrombosis. Acute to chronic inflammatory, neoplastic, or benign parenchyma changes were not noted. The spleen measured 0.76 cm in width.

Liver

The liver was subjectively normal in size, structure, and contour. The liver parenchyma was mildly nonuniform and hypoechoic to the spleen with a moderate coarse echotexture and subjective mild to



PATIENT

benign parenchymal remodeling. The hepatic and portal vasculature were normal in appearance without signs of congestion.

Quincy Lee Mains

SPECIES

The gallbladder was non distended in size with mild gallbladder debris. The cystic duct and common bile ducts were normal without evidence of dilation.

Feline

BREED

Gastrointestinal

DSH

The stomach presented intact wall layering with a normal wall layer ratio. The lumen of the stomach was empty with no signs of ileus, obstruction or foreign material. The gastric body wall measured 0.28 cm.

SEX

The small intestine revealed a large mural mass, present in the mid to caudal abdomen, exhibiting marked hypoechoic mural hypertrophy and loss of discernable wall layering. The mass measured potentially 7-8 cm in length x 3.1 cm in width with wall width up to 2.0 cm – 2.1 cm. Concurrent mild metabolic to periintestinal ileus present. The rest of the small intestine was sonographically unremarkable. The ileocolic wall measured 0.28 cm. The duodenum wall measured 0.25 cm.

Neutered Male

AGE

12 Years 6 Months

The visualized and discernable colon exhibited intact sonographically unremarkable wall layering containing formed feces. No evidence of diarrhea.

WEIGHT

10.1 Lbs.

Pancreas

INTERPRETED BY

The pancreas was normal in size and contour with mildly hypoechoic to uniform parenchyma compared to adjacent omentum.

R. McKenzie Daniel,
DVM, DABVP
(Canine and Feline)

Free Abdomen

Evidence of regional periintestinal reactive mesentery. Evidence of concurrent significant mesenteric lymphadenopathy was not appreciated. No overt effusion.

IMAGING PERFORMED BY

Jenna Walsh, CVT

ULTRASONOGRAPHIC FINDINGS

- Large intestinal mural mass- suspect jejunal mural mass given the location and without overt evidence of colonic ileocecolic or duodenal involvement
- Bilateral nonspecific chronic renal changes with potential indistinct to emerging nodules, possible associated subtle left hypoechoic halo sign
- Possible low-grade pancreatitis
- Mild gallbladder debris- likely incidental, potentially owing to fasting or nonclinical cholestasis

HOSPITAL NAME

Countryside AC

REFERRING VET

Dr. Cox

INTERPRETATION OF THE FINDINGS & FURTHER RECOMMENDATIONS

INVOICE

14132

Although sampling is required for further clarification, neoplastic criteria is favored for the intestinal mural mass with non-neoplastic etiologies, such as severe inflammation or granulomatous (dry FIP) etiologies possible.

DATE

2/28/22

The bilateral kidneys may indicate nonspecific nephritis or chronic renal changes. However, the possibility of emerging primary versus metastatic neoplastic nodules, given the presence of the



PATIENT

intestinal mural mass is of concern. Cytology recommended prior to potential surgical considerations.

Quincy Lee Mains

Assuming normal clotting status, ultrasound guided FNA of the intestinal mural mass as well as the indistinct renal nodule, using a 25-gauge needle, for screening cytology is recommended with potential for oncology consult. Three-view chest radiographs recommended, if not done.

SPECIES

Feline

BREED

DSH

SEX

Neutered Male

AGE

12 Years 6 Months

WEIGHT

10.1 Lbs.

INTERPRETED BY

R. McKenzie Daniel,
DVM, DABVP
(Canine and Feline)

IMAGING PERFORMED BY

Jenna Walsh, CVT

HOSPITAL NAME

Countryside AC

REFERRING VET

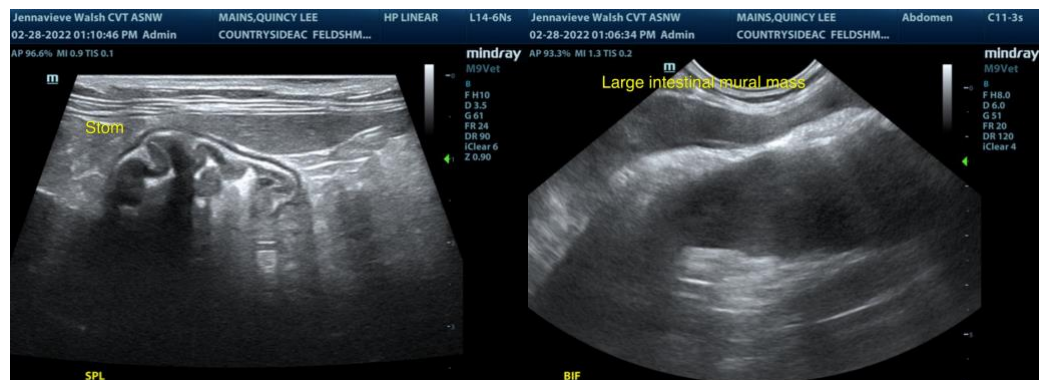
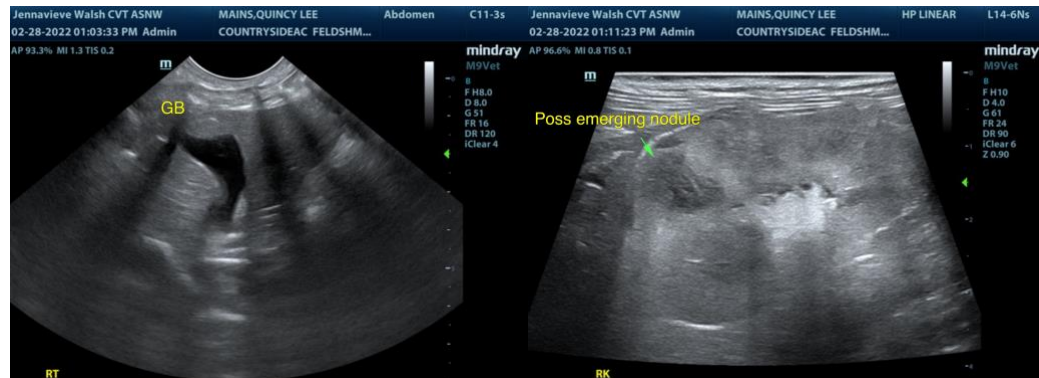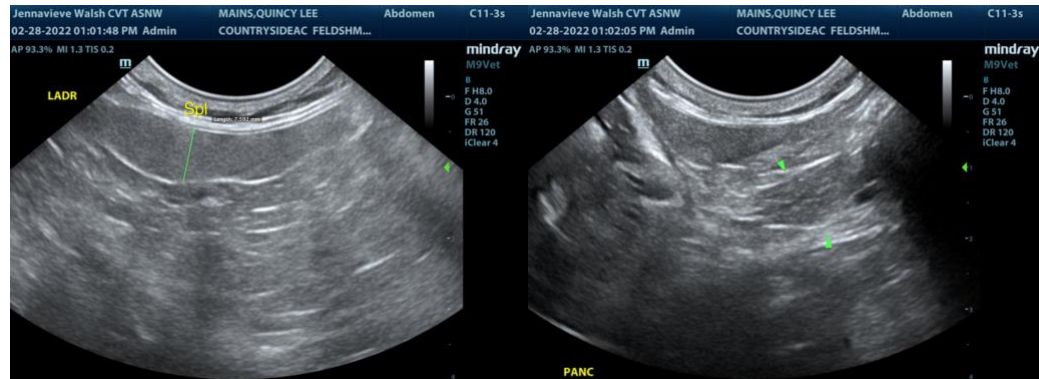
Dr. Cox

INVOICE

14132

DATE

2/28/22





PATIENT

Quincy Lee Mains

SPECIES

Feline

BREED

DSH

SEX

Neutered Male

AGE

12 Years 6 Months

WEIGHT

10.1 Lbs.

INTERPRETED BY

R. McKenzie Daniel,
DVM, DABVP
(Canine and Feline)

IMAGING PERFORMED BY

Jenna Walsh, CVT

HOSPITAL NAME

Countryside AC

REFERRING VET

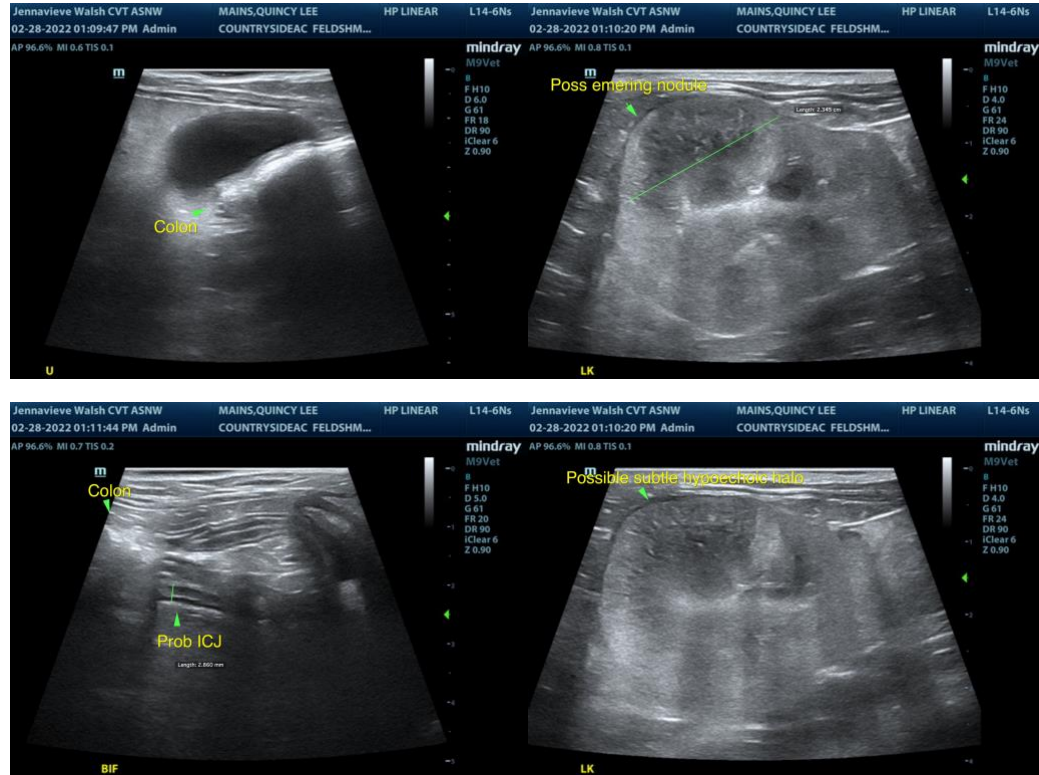
Dr. Cox

INVOICE

14132

DATE

2/28/22



The information and recommendations provided are based on the images presented by the referring veterinarian. No evaluation can be communicated regarding pathology that was not visible in the image/video clips provided.

Thank you for this referral. If the clinical or image interpretation does not parallel your findings or if I can be of any further assistance please contact me.

R. McKenzie Daniel, DVM, DABVP (Canine / Feline Practice)
info@SonoPath.com