



PATIENT

Kip Dones

SPECIES

Canine

BREED

Border Collie

SEX

Neutered Male

AGE

1 Year 3 Months

WEIGHT

42 Pounds

INTERPRETED BY

R. McKenzie Daniel,
DVM, DABVP
(Canine and Feline)

**IMAGING
PERFORMED BY**

Amanda Lacey-Crook –
SDEP Certified
Sonographer

HOSPITAL NAME

Rivers Edge PMC

REFERRING VET

Dr. David Gray

INVOICE

35947

DATE

2/28/22

PRESENTING CLINICAL SIGNS

Acute vomiting, nausea and painful abdomen. P on gabapentin and Cerenia.
Abnormal PE/Chem/CBC/UA Results: WBC 22.5 w/neutrophilia, monocytosis. Unremarkable Chem.
No electrolytes.

ULTRASONOGRAPHIC EXAMINATION OF THE ABDOMEN

Urinary System

The urinary bladder, trigone, cystourethral junction, and visible pelvic urethra to a depth of 3.0 cm exhibited normal thickness and tone. Anechoic urine was present in the lumen with no uroliths or sediment. The ureteral papillae were normal. The ureters were not visible which is normal. No evidence of inflammatory or neoplastic changes were noted.

No overt pathology associated with the residual prostate.

The area of the aortic trifurcation was free of pathology.

Normal size and margination were present in the kidneys. A normal 1:3 cortex / medulla ratio and normal corticomedullary definition were maintained. The echogenicity of the cortex was similar to or slightly less than normal liver parenchyma while the medulla echogenicity was hypoechoic to the cortex with no evidence of pelvic dilation. The left kidney measured 6.0 cm. The right kidney measured 5.9 cm.

Adrenal Glands

The adrenal glands were uniform in size and contour with a uniformly hypoechoic parenchyma. The left adrenal gland measured 0.34 cm at the cranial pole and 0.38 cm at the caudal pole. The right adrenal gland measured 0.45 cm at the caudal pole.

Spleen

The spleen exhibited a finely textured and homogenous parenchyma which was hyperechoic to the liver and renal cortical parenchyma. The capsule was smooth and regular without apparent expansion. The splenic vasculature at the hilus was normal in volume with no evidence of congestion or thrombosis. Acute to chronic inflammatory, neoplastic, or benign parenchyma changes were not noted.

Liver

The liver was subjectively normal in size, structure, and contour. The liver parenchyma was uniform and hypoechoic to the spleen with a mild coarse echotexture. The hepatic and portal vasculature were normal in appearance without signs of congestion. The gallbladder was non distended in size with minor non-dependent particulate debris. The debris is non-specific, yet suspected to be owing to fasting. The cystic duct and common bile ducts were normal without evidence of dilation.

Gastrointestinal

The stomach presented intact yet mild subjective prominent wall layering. The lumen of the stomach was empty with mild luminal gas. No evidence of retained ingesta, fluid or foreign material. Gastric body wall measured 0.46 cm.

The small intestine presented intact wall layering with 1:3 muscularis/mucosa ratio. Mild segmental jejunal mucosal speckling was present along with non-obstructive duodenal and segmental jejunal ileus. No overt evidence of foreign material in the small intestine.

Normal visible colon wall layers were present with segmental subjective semiformed feces present in the transverse colon with strongly shadowing feces present in the descending colon.



PATIENT

Pancreas

Kip Dones

The parenchyma of the left limb, body and right limb of the pancreas presented isoechoic to the adjacent omental fat. A normal curvilinear capsule contour of the pancreas was present. The visible pancreatic duct was normal. No signs of active inflammation or neoplastic disease was evident.

SPECIES

Canine

Free Abdomen

Focal to intermittent, mildly prominent to enlarged jejunal lymph nodes were present. Example measured 2.0 cm x 0.84 cm. The lymph node was essentially isoechoic to adjacent omentum without evidence of peripheral inflammation and maintaining a normal width: length ratio (<0.5).

BREED

Border Collie

SEX

Neutered Male

- Gastroenteritis pattern exhibiting mild duodenal and segmental jejunal ileus – no evidence of obstructive pattern or overt foreign material.
- Associated mild subjectively benign/reactive jejunal lymphadenopathy

AGE

1 Year 3 Months

INTERPRETATION OF THE FINDINGS & FURTHER RECOMMENDATIONS

No indication for surgical intervention based on this study and lack of definitive obstructive pattern. Dietary indiscretion/food intolerance, gastroenterotoxic insult, occult parasitism, infectious gastroenteritis, or other gastroenteropathy possible. The potential for possible passed foreign material now present in the descending colon cannot be definitively excluded. Medical therapy for gastroenteritis with monitoring of fecal output would be reasonable. Potential for low-grade pancreatitis (and sonographically normal), yet considered less likely given the normal CPL. Recheck sonogram to assess for progressive inflammatory gastrointestinal changes could be considered if persistent gastrointestinal signs non-responsive to conservative gastroenteritis protocol.

WEIGHT

42 Pounds

INTERPRETED BY

R. McKenzie Daniel,
DVM, DABVP
(Canine and Feline)

IMAGING PERFORMED BY

Amanda Lacey-Crook –
SDEP Certified
Sonographer

HOSPITAL NAME

Rivers Edge PMC

REFERRING VET

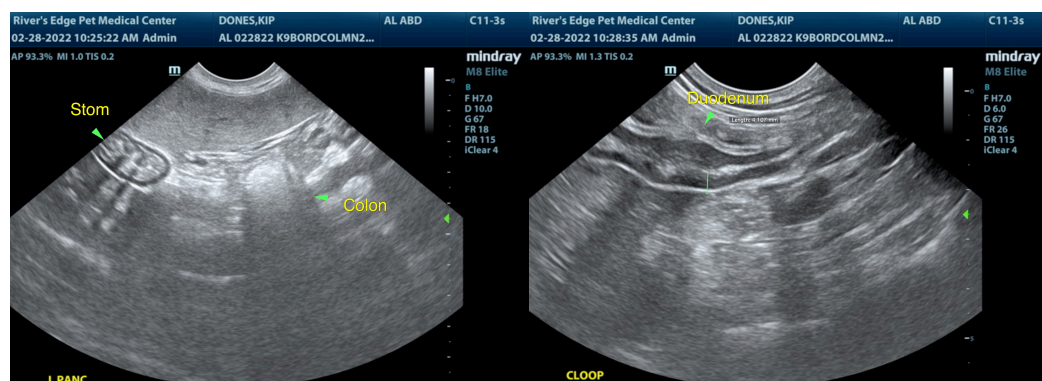
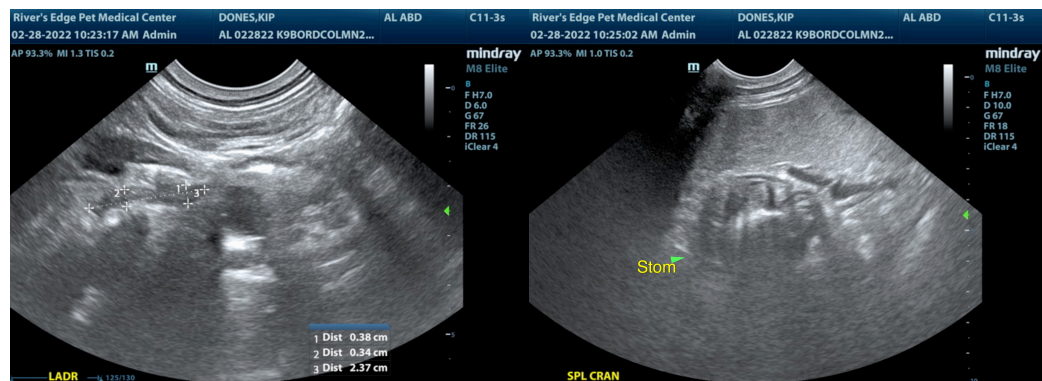
Dr. David Gray

INVOICE

35947

DATE

2/28/22





PATIENT

Kip Dones

SPECIES

Canine

BREED

Border Collie

SEX

Neutered Male

AGE

1 Year 3 Months

WEIGHT

42 Pounds

INTERPRETED BY

R. McKenzie Daniel,
DVM, DABVP
(Canine and Feline)

IMAGING PERFORMED BY

Amanda Lacey-Crook –
SDEP Certified
Sonographer

HOSPITAL NAME

Rivers Edge PMC

REFERRING VET

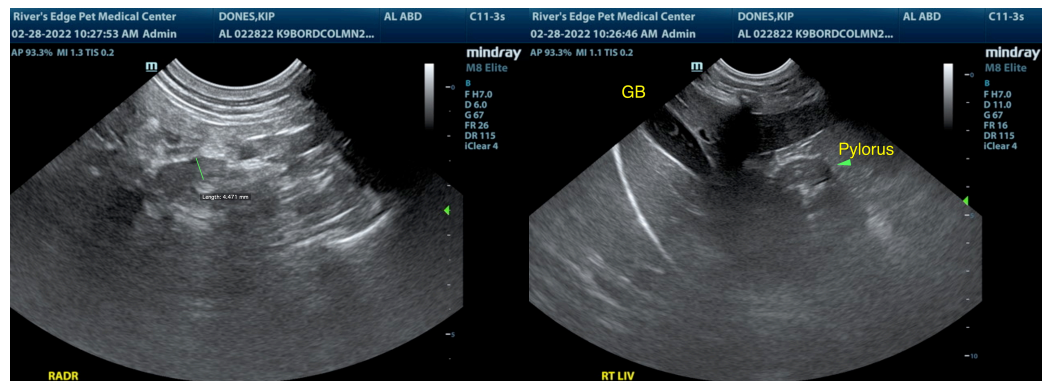
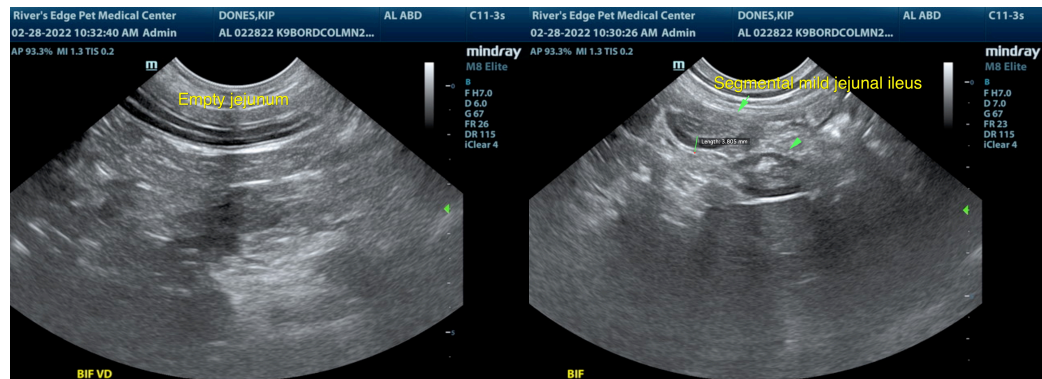
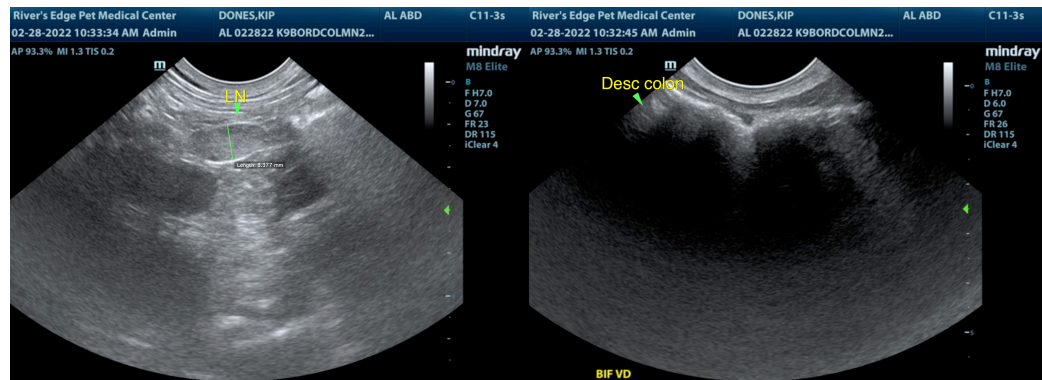
Dr. David Gray

INVOICE

35947

DATE

2/28/22



The information and recommendations provided are based on the images presented by the referring veterinarian/sonographer. No evaluation can be communicated regarding pathology that was not visible in the image/video clips provided.

Thank you for this referral. If the clinical or image interpretation does not parallel your findings or if I can be of any further assistance please contact me.

R. McKenzie Daniel, DVM, DABVP (Canine / Feline Practice)

info@SonoPath.com