



PATIENT	PRESENTING CLINICAL SIGNS
Indy Pracher	Had splenectomy on 2/10/22 - Hemangiosarcoma. Now is anemic, has hemoabdomen Abnormal PE/Chem/CBC/UA Results: PCV 19, prot 5
SPECIES	ULTRASONOGRAPHIC EXAMINATION OF THE ABDOMEN
Canine	Urinary System
BREED	The urinary bladder, trigone, cystourethral junction, and visible pelvic urethra to a depth of 5.0 cm exhibited normal thickness and tone. Primarily anechoic urine was present in the lumen. Mild non-dependent particulate to congealed sediment was present without evidence of calculus formation. The ureteral papillae were normal. The ureters were not visible which is normal. No evidence of inflammatory or neoplastic mural changes were noted.
Lab X	
SEX	No overt pathology in the area of the residual prostate.
Neutered Male	The area of the aortic trifurcation was free of pathology.
AGE	Normal size and margination were present in the kidneys. A normal 1:3 cortex / medulla ratio and normal corticomedullary definition were maintained. The echogenicity of the cortex was similar to or slightly less than normal liver parenchyma while the medulla echogenicity was hypoechoic to the cortex with no evidence of pelvic dilation. The left kidney measured 6.3 cm. The right kidney measured 6.0 cm.
7.5 Years	
WEIGHT	Adrenal Glands
56 Pounds	The adrenal glands were uniform in size and contour with a uniformly hypoechoic parenchyma. The left adrenal gland measured 3.3 cm length x 0.56 cm at the caudal pole. The right adrenal gland measured 2.3 cm length x 0.87 cm at the caudal pole.
INTERPRETED BY	Spleen
R. McKenzie Daniel, DVM, DABVP (Canine and Feline)	The area of the previous spleen revealed subtle non-uniform parenchyma without overt evidence of residual regional pathology such as omental masses or lymphadenopathy.
IMAGING PERFORMED BY	Liver
Jessica Miller	The liver exhibited generalized enlargement. Moderately sized to expansive non-homogeneous mass present in the cranial aspect of the mid to left liver measuring 5-6 cm in diameter. Concurrent intermittent, discrete hypoechoic intraparenchymal nodules not associated with the mass were visualized. Example measured 0.8 cm in diameter. The gallbladder was non-distended in size with thin walls and primarily anechoic luminal content. The cystic and common bile ducts were normal.
HOSPITAL NAME	Gastrointestinal
Newton Vet Hospital	The stomach presented intact wall layering with a normal wall layer ratio. Minor retained ingesta/chyme present.
REFERRING VET	The small intestine presented intact wall layering with 1:3 muscularis/mucosa ratio. The lumen of the small intestine was empty with no signs of ileus, obstruction or foreign material.
Dr. Bladek	Normal visible colon wall layers were present with apparent formed feces in lumen.
INVOICE	
35940	
DATE	
2/28/22	



PATIENT

Pancreas

Indy Pracher

The pancreas was normal in size and contour with isoechoic to heterogeneous parenchyma compared to adjacent omentum. No signs of active inflammation or neoplasia.

SPECIES

Free Abdomen

Canine

Moderate volume peritoneal free fluid exhibiting mild subjective cellular component. No evidence of omental masses or lymphadenopathy.

BREED

Rapid view of the heart revealed no evidence of pericardial masses or effusion in the visible window.

Lab X

SEX

- Non-homogeneous liver mass with intermittent concurrent discrete hypoechoic intraparenchymal nodules

Neutered Male

- Moderate volume peritoneal free fluid exhibiting mild cellular component – consistent with previously diagnosed hemoabdomen

AGE

- Urinary bladder sediment – suspect cellular debris/protein, potential for mild mucus.

7.5 Years

INTERPRETATION OF THE FINDINGS & FURTHER RECOMMENDATIONS

WEIGHT

Given the patient's history of previously diagnosed splenic hemangiosarcoma, the hepatic mass and potentially intermittent discrete hypoechoic intraparenchymal nodules are consistent with hepatic metastasis with potential for multicentric sarcoma. Given the lack of additional intraabdominal masses or other overt pathology, the hemoabdomen in this patient is suspected to be secondary to the hepatic mass and likely hepatic metastatic hemangiosarcoma. Correlation with coagulation panel could be considered. Unfortunately, an unfavorable prognosis is likely indicated.

56 Pounds

INTERPRETED BY

R. McKenzie Daniel,
DVM, DABVP
(Canine and Feline)

IMAGING PERFORMED BY

Jessica Miller

HOSPITAL NAME

Newton Vet Hospital

REFERRING VET

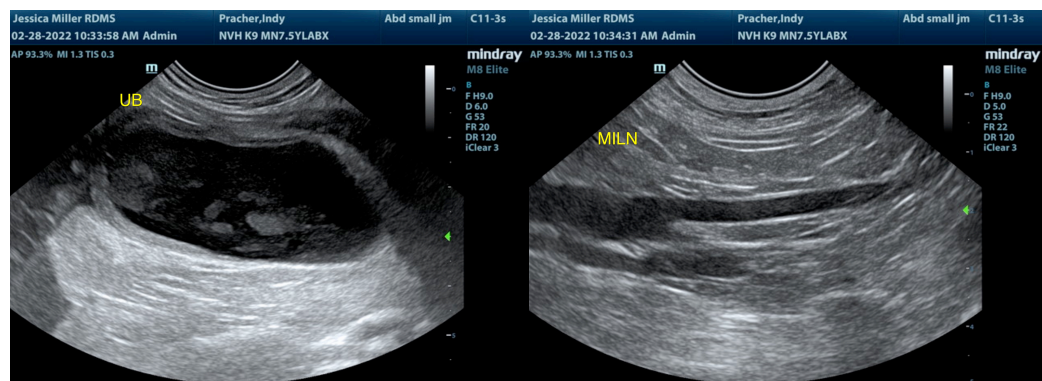
Dr. Bladek

INVOICE

35940

DATE

2/28/22





PATIENT

Indy Pracher

SPECIES

Canine

BREED

Lab X

SEX

Neutered Male

AGE

7.5 Years

WEIGHT

56 Pounds

INTERPRETED BY

R. McKenzie Daniel,
DVM, DABVP
(Canine and Feline)

IMAGING PERFORMED BY

Jessica Miller

HOSPITAL NAME

Newton Vet Hospital

REFERRING VET

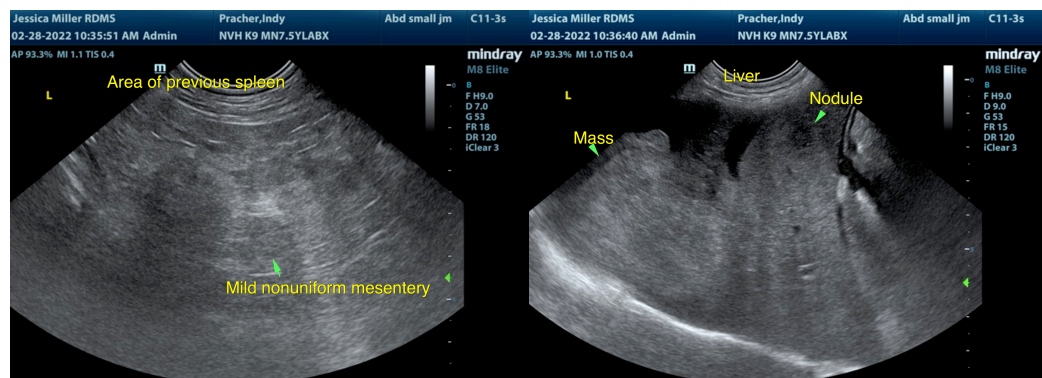
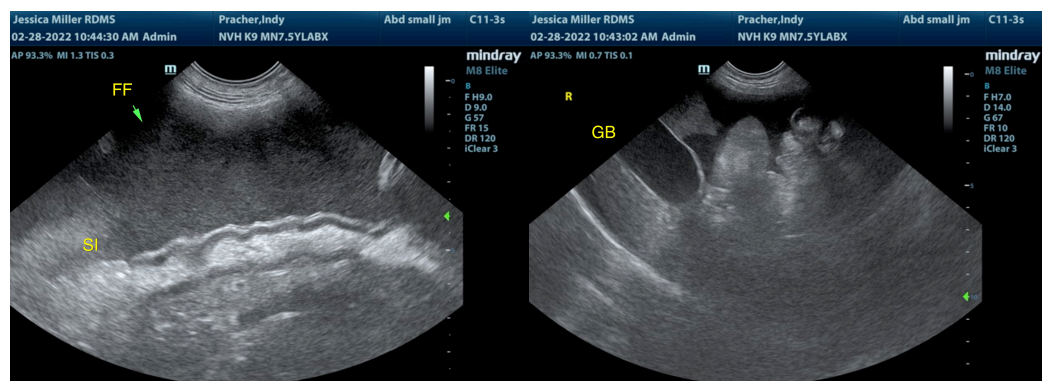
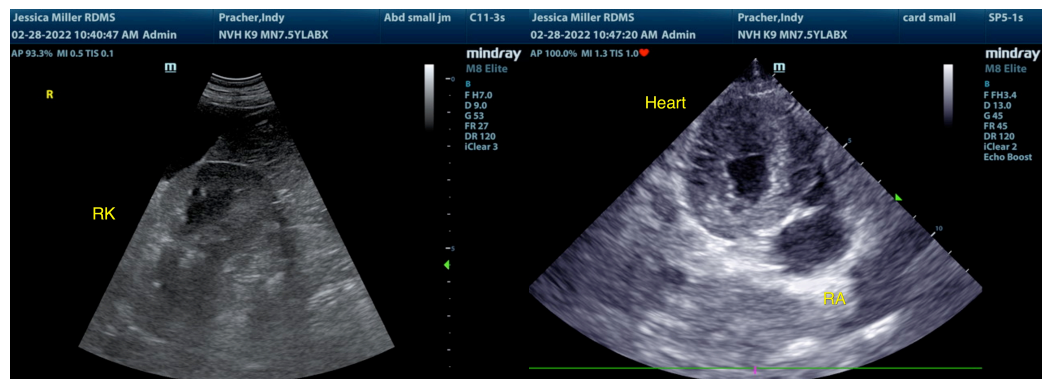
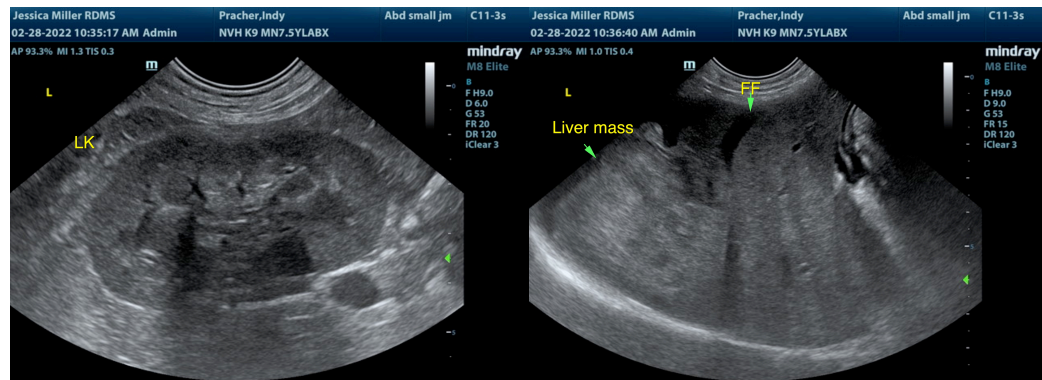
Dr. Bladek

INVOICE

35940

DATE

2/28/22





PATIENT

Indy Pracher

The information and recommendations provided are based on the images presented by the referring veterinarian/sonographer. No evaluation can be communicated regarding pathology that was not visible in the image/video clips provided.

SPECIES

Canine

Thank you for this referral. If the clinical or image interpretation does not parallel your findings or if I can be of any further assistance please contact me.

BREED

Lab X

R. McKenzie Daniel, DVM, DABVP (Canine / Feline Practice)

info@SonoPath.com

SEX

Neutered Male

AGE

7.5 Years

WEIGHT

56 Pounds

INTERPRETED BY

R. McKenzie Daniel,
DVM, DABVP
(Canine and Feline)

**IMAGING
PERFORMED BY**

Jessica Miller

HOSPITAL NAME

Newton Vet Hospital

REFERRING VET

Dr. Bladek

INVOICE

35940

DATE

2/28/22