



PATIENT

Trixie Dicks

SPECIES

Canine

BREED

Rat Terrier X

SEX

Spayed Female

AGE

8 Years

WEIGHT

19 Pounds

PRESENTING CLINICAL SIGNS

Clinical Exam Findings:

- Lobulated 4cm x 2cm firm mass dorsal mid abdomen palpated during exam on 9/27/25
- Exam on 1/23/26 dental cleaning was recommended
- Pre-op ECG and CBC/Superchem/T4/UA/Urine Culture done on 2/7/26, ECG came back with sinus with intermittent single APCs and supraventricular arrhythmia
- Blood pressure performed 2/27/26, average systolic BP of 145mmHg
- Chest radiographs performed 2/27/26
- For ECHO Only: Blood Pressure: 145mmHg average systolic
- HR/RR/BP: HR-120, RR-40, Avg Sys BP - 145
- Is there a Heart Murmur? If so, please grade: Grade 1/6 L sided systolic murmur heard 2/27/26. Ectopic beats with no pulse associated.

INTERPRETED BY

R. McKenzie Daniel,
 DVM, DABVP (Canine /
 Feline Practice)

IMAGING PERFORMED BY

Sara Hansen

HOSPITAL NAME

Edgewood AC

REFERRING VET

Dr. Callahan

INVOICE

35992

DATE

2/27/26

ULTRASONOGRAPHIC EXAMINATION OF THE HEART & ABDOMEN

CANINE CARDIAC PARAMETERS	MR VMAX (m/s)	TR VMAX (m/s)	LA/AO (M-Mode)	LA/AO (Heart Base; Swe)	FS (%)	EF (%)	EPSS (cm)
NORMAL PARAMETER	4.5-5.5	<2.7	1.3	Up to 1.6	28-40	40-100	<0.6
PATIENT	5.0	--	--	1.4	45	78	0.1
CANINE CARDIAC PARAMETERS	HR (BPM)	AV VMAX (m/s)	PV MAX (m/s)	BODY WEIGHT (lbs)	LAD LA MAX 4 Chamber	LVIDd Avg; 2D and m-mode short axis (cm)	LVIDs Avg; 2D and m-mode short axis (cm)
NORMAL PARAMETER	50-100	0.7-1.7	0.7-1.6				
PATIENT	NM	1.2	1.2	19 lbs	2.5	3.1	--

Cardiac Presentation



PATIENT

Trixie Dicks

SPECIES

Canine

BREED

Rat Terrier X

SEX

Spayed Female

AGE

8 Years

WEIGHT

19 Pounds

INTERPRETED BY

R. McKenzie Daniel,
DVM, DABVP (Canine /
Feline Practice)

IMAGING PERFORMED BY

Sara Hansen

HOSPITAL NAME

Edgewood AC

REFERRING VET

Dr. Callahan

INVOICE

35992

DATE

2/27/26

The echocardiogram in this patient demonstrated normal **left atrial** size based on 2 different LA measurement methods. Chamber volumes and echogenicity were normal. The cranial and caudal **mitral** valve leaflets presented thickening consistent with endocardiosis. Doppler indicated measurable mild eccentric insufficiency. The **left ventricle** presented thicknesses with linear contour and was not dilated nor restricted. The **myocardium** presented normal echogenicity without subjective evidence of significant fibrotic or ischemic disease. **Contractility** of the ventricular walls was adequate and in normal range for this patient evidenced by the fractional shortening measurement and subjective evaluation of the different regions of the myocardium. The **left ventricular outflow** tract demonstrated normal laminar flow and subjective structural integrity. The **right atrium** and auricle revealed normal size, structure and content. No evidence of masses was noted or chamber overload. **Tricuspid** valvular assessment demonstrated adequate linear morphology. The **right ventricle** was of normal size (1/3 diameter of LV), chordae structure, myocardial echogenicity and thickness. **Pulmonic** tract assessment revealed normal valve structure, laminar flow, and diameter (approx.1:1 pa/ao ratio). No visible **pericardial** or free pleura fluid was noted. No echographically detectable evidence of cardiac / pericardial tumors was visible. No overt arrhythmia was noted.

ULTRASONOGRAPHIC EXAMINATION OF THE ABDOMEN

Urinary System

The urinary bladder, trigone, cystourethral junction, and visible pelvic urethra to a depth of 2.0 cm exhibited normal thickness and tone. Anechoic urine was present in the lumen with no uroliths or sediment. The ureteral papillae were normal. The ureters were not visible which is normal. No evidence of inflammatory or neoplastic changes were noted. The area of the aortic trifurcation was free of pathology.

Normal size and margination was present in the kidneys. A normal 1:3 cortex / medulla ratio and normal corticomedullary definition were maintained. The echogenicity of the cortex was similar to or slightly less than normal liver parenchyma while the medulla echogenicity was hypoechoic to the cortex with no evidence of pelvic dilation. The left kidney measured 4.3 cm in length. The right kidney measured 4.5 cm in length.

Adrenal Glands

The left adrenal gland was uniform in size and contour with a uniformly hypoechoic parenchyma. The left adrenal gland measured 0.43 cm width at the caudal pole.

The right adrenal gland was uniform in size and contour with a uniformly hypoechoic parenchyma. The right adrenal gland measured 0.49 cm width at the caudal pole.

Spleen

The spleen exhibited a finely textured and homogenous parenchyma which was hyperechoic to the liver and renal cortical parenchyma. The capsule was smooth and regular without apparent expansion. The splenic vasculature at the hilus was normal in volume with no evidence of congestion or thrombosis. Acute to chronic inflammatory, neoplastic, or benign parenchyma changes were not noted.



PATIENT

Liver

Trixie Dicks

The liver presented subjective borderline to mildly enlarged in size. The parenchyma of the liver was subjectively normal in echogenicity compared to the spleen and renal cortices. The liver parenchyma was uniform with a mildly coarse echotexture. The capsule of the liver was symmetrically rounded to mildly swollen in margination. The hepatic and portal vasculature were normal in appearance without signs of congestion.

SPECIES

Canine

BREED

Rat Terrier X

The gallbladder was non distended in size with mild nonorganized gallbladder debris. The cystic duct and common bile ducts were normal without evidence of dilation.

SEX

Spayed Female

Gastrointestinal

The stomach presented intact wall layering with a normal wall layer ratio. The lumen of the stomach contained mild retained pyloric fluid.

AGE

8 Years

The small intestine presented intact wall layering with 1:3 muscularis/mucosa ratio. The lumen of the small intestine was empty with no signs of ileus, obstruction or foreign material.

Normal visible colon wall layers were present with apparent formed feces in lumen.

WEIGHT

19 Pounds

Pancreas

The parenchyma of the left limb, body and right limb of the pancreas presented isoechoic to the adjacent omental fat. A normal curvilinear capsule contour of the pancreas was present. The visible pancreatic duct was normal. No signs of active inflammation or neoplastic disease was evident.

INTERPRETED BY

R. McKenzie Daniel,
DVM, DABVP (Canine /
Feline Practice)

Free Abdomen

No overt lymphadenopathy or peritoneal effusion was present.

IMAGING PERFORMED BY

Sara Hansen

ULTRASONOGRAPHIC FINDINGS

- Chronic mitral valve disease (B1)
- Borderline/mild hepatomegaly- subjectively benign
- Mild gallbladder debris (non-mucocele)
- Normal spleen
- Normal gastrointestinal tract with mild retained gastric fluid

HOSPITAL NAME

Edgewood AC

REFERRING VET

Dr. Callahan

INTERPRETATION OF THE FINDINGS & FURTHER RECOMMENDATIONS

The cause of the murmur is chronic degenerative valvular changes with secondary eccentric mitral valve insufficiency. The lack of left atrial enlargement implies that the risk of complication secondary to mitral valve insufficiency is low at this time and, without current clinical signs, indicates that medical therapy is not required. Prognosis is considered variable and sonographic monitoring is recommended. Recheck echo cardiogram is suggested in 6-12 months, sooner if clinical signs arise.

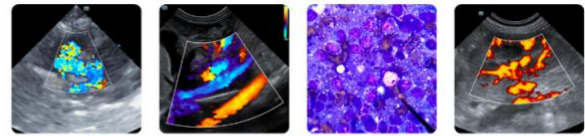
INVOICE

35992

DATE

2/27/26

No evidence of visceral pathology or intraabdominal masses. The borderline mild hepatomegaly may indicate vacuolar or cholestatic hepatopathy with minor potential for inflammation given the



PATIENT

Trixie Dicks

SPECIES

Canine

BREED

Rat Terrier X

SEX

Spayed Female

AGE

8 Years

WEIGHT

19 Pounds

INTERPRETED BY

R. McKenzie Daniel,
 DVM, DABVP (Canine /
 Feline Practice)

**IMAGING
 PERFORMED BY**

Sara Hansen

HOSPITAL NAME

Edgewood AC

REFERRING VET

Dr. Callahan

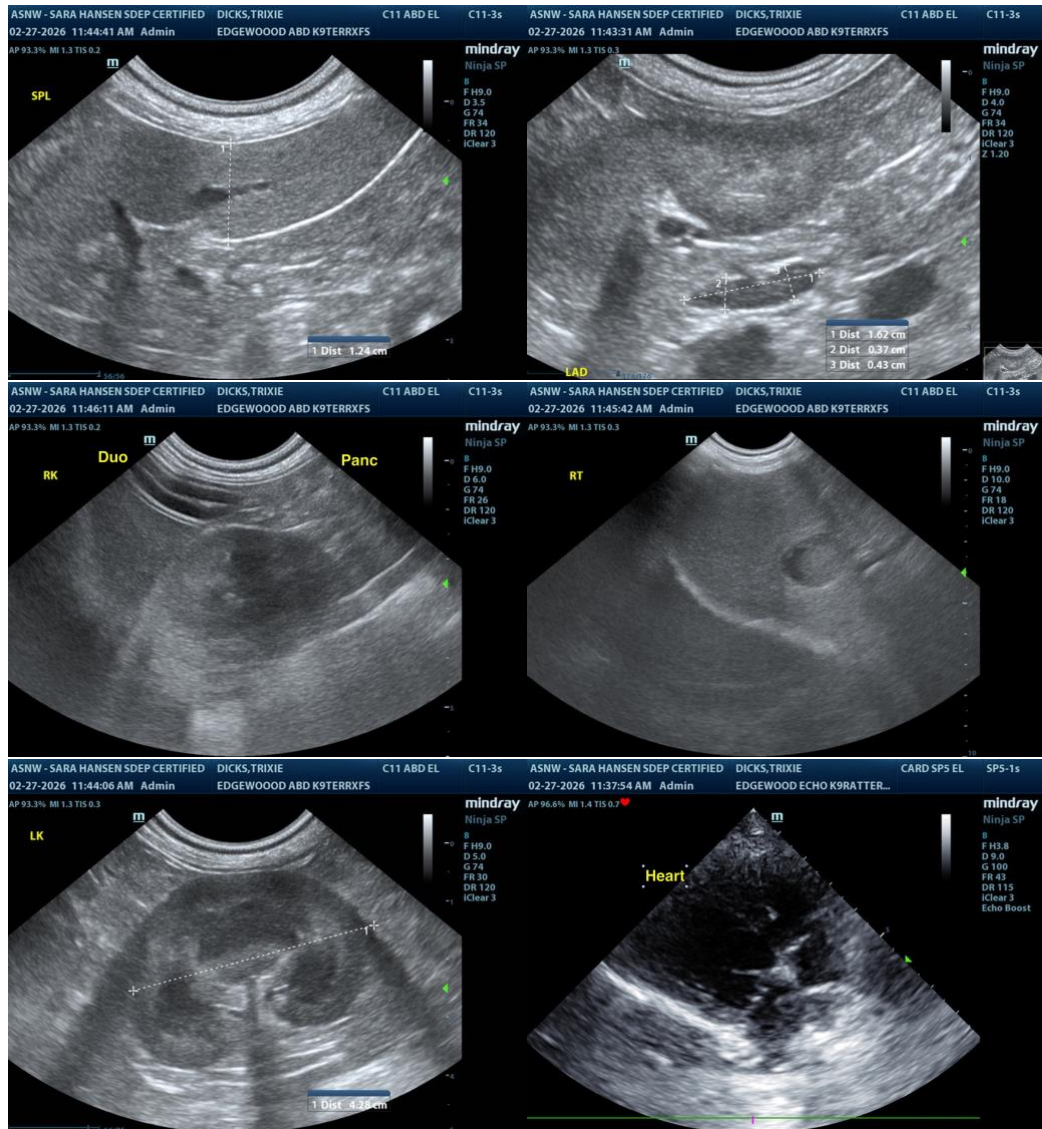
INVOICE

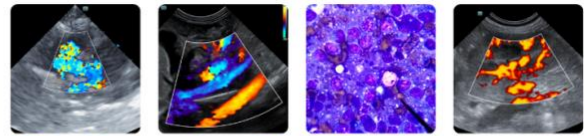
35992

DATE

2/27/26

concurrent gallbladder debris. Correlation with lab work is recommended. Hepatosupportive medications are suggested if clinically indicated.





PATIENT

Trixie Dicks

SPECIES

Canine

BREED

Rat Terrier X

SEX

Spayed Female

AGE

8 Years

WEIGHT

19 Pounds

INTERPRETED BY

R. McKenzie Daniel,
 DVM, DABVP (Canine /
 Feline Practice)

IMAGING PERFORMED BY

Sara Hansen

HOSPITAL NAME

Edgewood AC

REFERRING VET

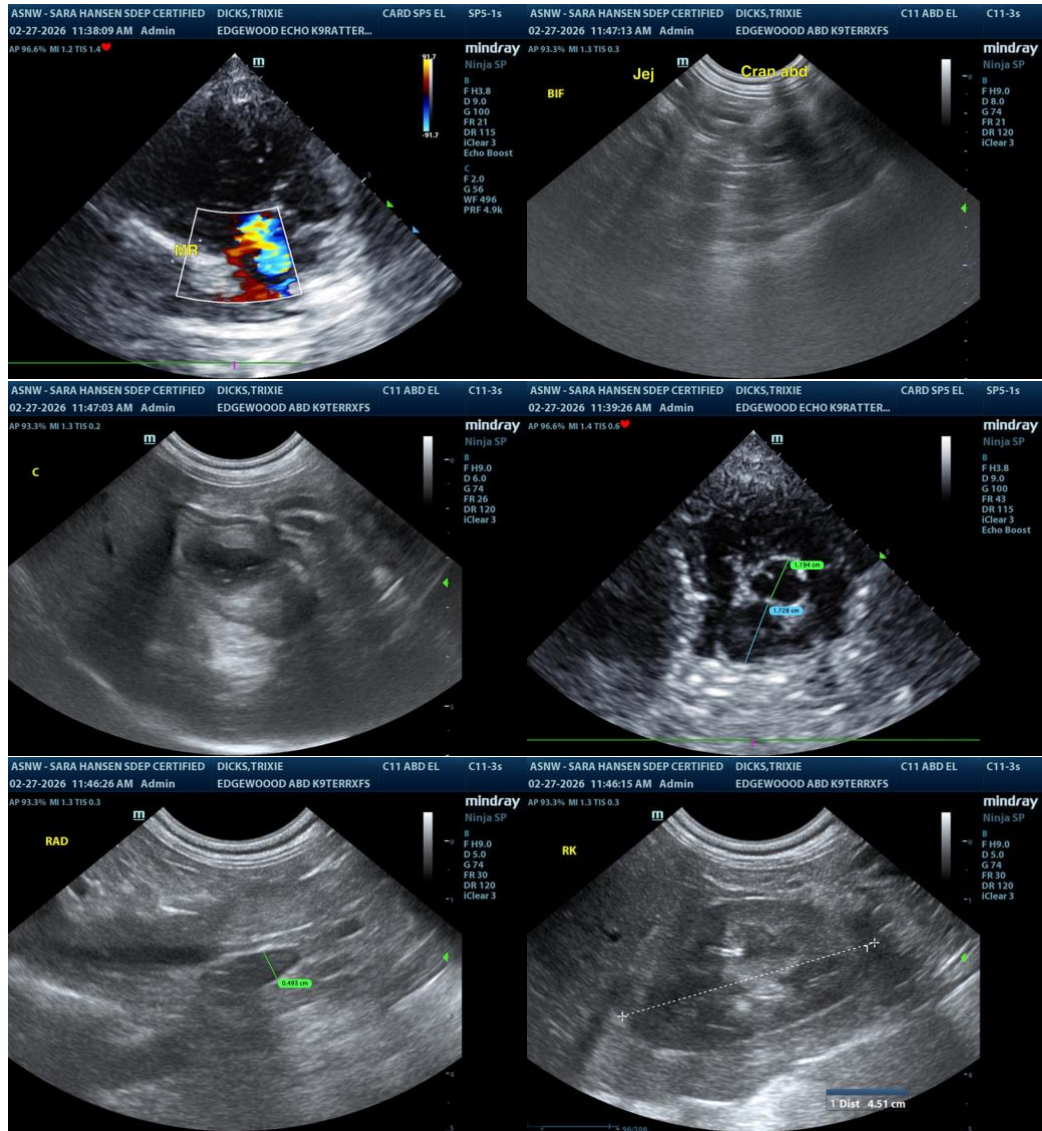
Dr. Callahan

INVOICE

35992

DATE

2/27/26



The information and recommendations provided are based on the images presented by the referring veterinarian/sonographer. No evaluation can be communicated regarding pathology that was not visible in the image/video clips provided.

Thank you for this referral. If the clinical or image interpretation does not parallel your findings or if I can be of any further assistance please contact me.

R. McKenzie Daniel, DVM, DABVP (Canine / Feline Practice)

info@SonoPath.com