



PATIENT

Dezarea Svensson

SPECIES

Canine

BREED

Dachshund

SEX

Spayed Female

AGE

11 Years

WEIGHT

9.6 Pounds

INTERPRETED BY

R. McKenzie Daniel,
DVM, DABVP
(Canine / Feline
Practice)

IMAGING PERFORMED BY

Dr. Gail Schmeider

HOSPITAL NAME

Slade VH

REFERRING VET

Dr. Gail Schmeider

INVOICE

35993

DATE

2/27/26

PRESENTING CLINICAL SIGNS

- Recheck adrenal tumor
- Slight increase in drinking
- Staff pet

ULTRASONOGRAPHIC EXAMINATION OF THE ABDOMEN

Urinary System

The urinary bladder, trigone, cystourethral junction, and visible pelvic urethra to a depth of 2.0 cm exhibited normal thickness and tone. Anechoic urine was present in the lumen with no uroliths or sediment. The ureteral papillae were normal. The ureters were not visible which is normal. No evidence of inflammatory or neoplastic changes were noted. The area of the aortic trifurcation was free of pathology.

Normal size and margination was present in the kidneys. A normal 1:3 cortex / medulla ratio was maintained. The medulla and cortices were uniform in texture with some increased echogenicity and mild loss of corticomedullary symmetry and definition expected for the age of the patient. No evidence of pelvic dilation was present. The left kidney measured 3.8 cm in length. The right kidney measured 4.7 cm in length. Previously noted static small medullary renoliths were noted in the right kidney.

Adrenal Glands

The left adrenal gland was uniform in size and contour with a uniformly hypoechoic parenchyma. The left adrenal gland measured 0.4 cm width at the caudal pole.

The previously noted mildly progressive nonhomogenous nonmineralized right adrenal mass was noted, measuring 2.1 cm x 1.5 cm, primarily occupying the mid to cranial right adrenal gland. The right adrenal gland was normal in width measuring 0.45 cm.

Spleen

The spleen exhibited a finely textured and homogenous parenchyma which was hyperechoic to the liver and renal cortical parenchyma. The capsule was smooth and regular without apparent expansion. The splenic vasculature at the hilus was normal in volume with no evidence of congestion or thrombosis. Acute to chronic inflammatory, neoplastic, or benign parenchyma changes were not noted.

Liver

The liver presented mildly enlarged in size. The parenchyma of the liver was subjectively normal in echogenicity compared to the spleen and renal cortices. The liver parenchyma was uniform with a mildly coarse echotexture. The capsule of the liver was symmetrically rounded to mildly swollen in margination. The hepatic and portal vasculature were normal in appearance without signs of congestion.

The gallbladder was non distended in size with moderate congealed hyperechoic gallbladder debris. The cystic duct and common bile ducts were normal without evidence of dilation.



PATIENT

Dezarea Svensson

SPECIES

Canine

BREED

Dachshund

SEX

Spayed Female

AGE

11 Years

WEIGHT

9.6 Pounds

INTERPRETED BY

R. McKenzie Daniel,
DVM, DABVP
(Canine / Feline
Practice)

IMAGING PERFORMED BY

Dr. Gail Schmeider

HOSPITAL NAME

Slade VH

REFERRING VET

Dr. Gail Schmeider

INVOICE

35993

DATE

2/27/26

Gastrointestinal

The stomach presented intact wall layering with a normal wall layer ratio. The lumen of the stomach was empty with no signs of ileus, obstruction or foreign material.

The small intestine presented intact wall layering with 1:3 muscularis/mucosa ratio. The lumen of the small intestine was empty with no signs of ileus, obstruction or foreign material.

Normal visible colon wall layers were present with apparent formed feces in lumen.

Pancreas

The parenchyma of the left limb, body and right limb of the pancreas presented isoechoic to the adjacent omental fat. A normal curvilinear capsule contour of the pancreas was present. The visible pancreatic duct was normal. No signs of active inflammation or neoplastic disease was evident.

Free Abdomen

No overt lymphadenopathy or peritoneal effusion was present.

ULTRASONOGRAPHIC FINDINGS

- Progressive right adrenal mass
- Normal left adrenal gland
- Static chronic renal changes and right kidney medullary renoliths
- Mild hepatomegaly
- Congealed gallbladder debris- early immature gallbladder mucocele

INTERPRETATION OF THE FINDINGS & FURTHER RECOMMENDATIONS

The right adrenal mass is almost certainly consistent with neoplastic criteria, given evidence of a progression compared to the previous study. Potential for non-obvious vascular invasion is not definitively excluded.

Note that 30% of Addisonian dogs are atypical and have normal sodium potassium ratios. Screening can be performed with a urine cortisol to creatinine ratio (UCCR) of less than 2.0 ug/dl is indicated as a screening for Addison's. This has near a 100% negative predictive value. UCCR less than 1.4 ug/dl is 100% sensitive and 97 % specific for Addison's. If the UCCR is greater than 2.0 ug/dl and Addisonian signs are present, then disease induced adrenal burnout may be the case. UCCR measures a 12-hour cortisol whereas baseline cortisol is a moment in time and fluctuates. Therefore, a UCCR is more sensitive and specific than baseline cortisol. Otherwise, baseline cortisol could be utilized if > 2.0 then this is negative also for Addison's, yet less sensitive and specific. Therefore, baseline UCCR is considered the best screening test. Therefore, if UCCR is less than 2.0 then full ACTH stimulation would be recommended for the diagnosis of Addison's. This is based on Del Baldo, et.al JVIM 2022.



PATIENT

Dezarea Svensson

SPECIES

Canine

BREED

Dachshund

SEX

Spayed Female

AGE

11 Years

WEIGHT

9.6 Pounds

INTERPRETED BY

R. McKenzie Daniel,
DVM, DABVP
(Canine / Feline
Practice)

IMAGING PERFORMED BY

Dr. Gail Schneider

HOSPITAL NAME

Slade VH

REFERRING VET

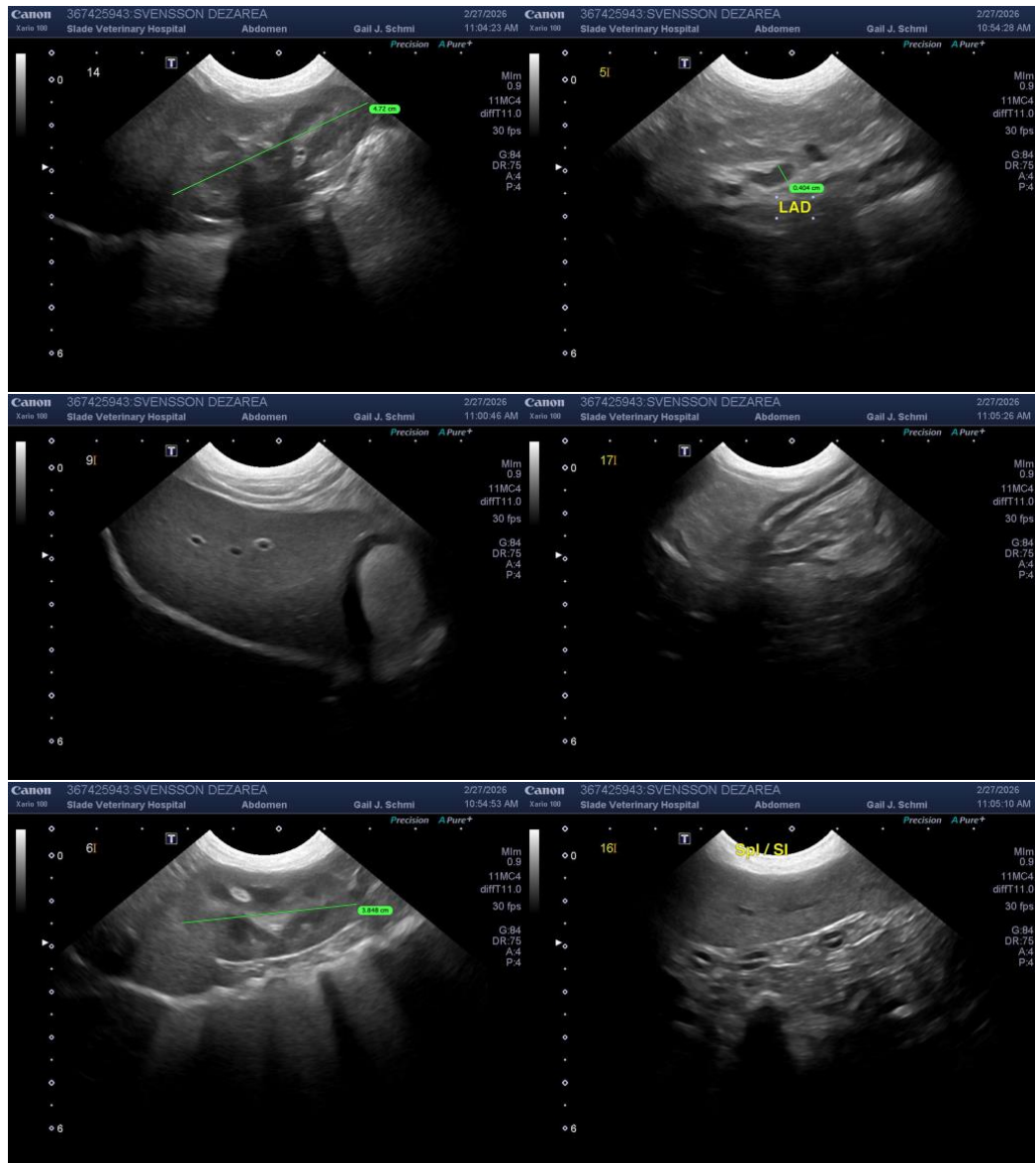
Dr. Gail Schneider

INVOICE

35993

DATE

2/27/26





PATIENT

Dezarea Svensson

SPECIES

Canine

BREED

Dachshund

SEX

Spayed Female

AGE

11 Years

WEIGHT

9.6 Pounds

INTERPRETED BY

R. McKenzie Daniel,
DVM, DABVP
(Canine / Feline
Practice)

IMAGING PERFORMED BY

Dr. Gail Schmeider

HOSPITAL NAME

Slade VH

REFERRING VET

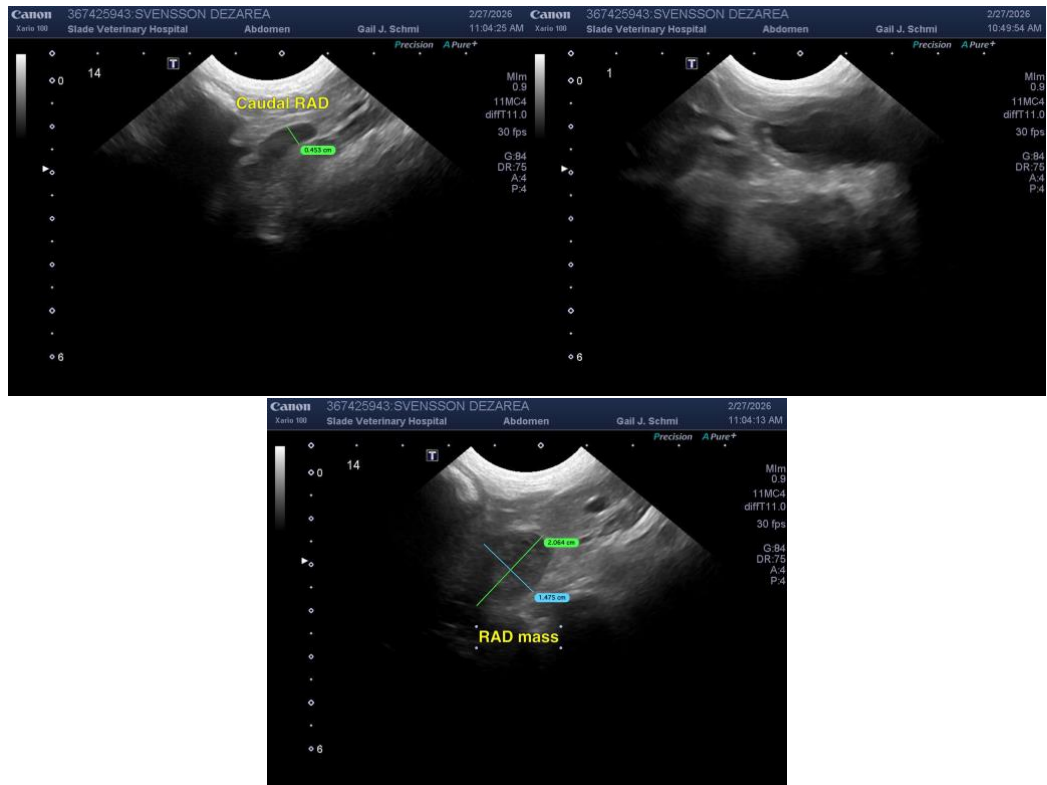
Dr. Gail Schmeider

INVOICE

35993

DATE

2/27/26



The information and recommendations provided are based on the images presented by the referring veterinarian/sonographer. No evaluation can be communicated regarding pathology that was not visible in the image/video clips provided.

Thank you for this referral. If the clinical or image interpretation does not parallel your findings or if I can be of any further assistance please contact me.

R. McKenzie Daniel, DVM, DABVP (Canine / Feline Practice)

info@SonoPath.com