



PATIENT

Chloe Worley

SPECIES

Canine

BREED

Terrier Mix

SEX

FS

AGE

10yr

WEIGHT

19lb

INTERPRETED BY

R. McKenzie Daniel,
DVM, DABVP
(Canine and Feline)

IMAGING PERFORMED BY

Matt Heinlein

HOSPITAL NAME

TLC Animal Hospital

REFERRING VET

Brian Giles

INVOICE

24034

DATE

02/27/2026

PRESENTING CLINICAL SIGNS

P presented for abdominal u/s referral. Per rDVM pre-dental anesthetic BW revealed significant hepatic enzyme elevation. Pre- and post- prandial bile acids elevated. Per O, P eating and drinking well, doing well at home.

Abnormal PE/Chem/CBC/UA Results: ALT: 550 (10-125) ALP: 898 (23-212) GLOB: 5.1 (2.5-4.5)
Bile Acids: Pre 45.2, Post 42.5

ULTRASONOGRAPHIC EXAMINATION OF THE ABDOMEN

Urinary System

The urinary bladder, trigone, cystourethral junction, and visible pelvic urethra to a depth of 3 cm exhibited normal thickness and tone. Anechoic urine was present in the lumen with no evidence of urine/lumen sediment, mineral, or calculi. The ureteral papillae were normal. The ureters were not visible which is normal. No evidence of inflammatory or neoplastic changes was noted.

Normal size and margination were present in the kidneys. A normal 1:3 cortex / medulla ratio was maintained. The medulla and cortices were uniform in texture with some increased echogenicity and mild loss of corticomedullary symmetry and definition expected for the age of the patient. No evidence of pelvic dilation was present. The left kidney measured 4.8 cm in length. The right kidney measured 5.3 cm in length.

The area of the aortic trifurcation was free of pathology.

Adrenal Glands

The left adrenal gland was uniform in size and contour with a uniformly hypoechoic parenchyma. The left adrenal gland measured 0.44 cm width at the caudal pole. The right adrenal gland was uniform in size and contour with a uniformly hypoechoic parenchyma. The right adrenal gland measured 0.44 cm width at the caudal pole.

Spleen

The spleen exhibited a finely textured and homogenous parenchyma which was hyperechoic to the liver and renal cortical parenchyma. The capsule was smooth and regular without apparent expansion. The splenic vasculature at the hilus was normal in volume with no evidence of congestion or thrombosis. Acute to chronic inflammatory, neoplastic, or benign parenchyma changes were not noted.

Liver/Gallbladder

The liver presented mildly enlarged in size. The parenchyma of the liver was subjectively normal in echogenicity compared to the spleen and renal cortices. The liver parenchyma was uniform with a mildly coarse echotexture. The capsule of the liver was symmetrically rounded to mildly swollen in margination. The hepatic and portal vasculature were normal in appearance without signs of congestion. The gallbladder was non-distended in size with mild non-organized debris. The cystic and common bile ducts were normal.

Gastrointestinal



PATIENT

Chloe Worley

SPECIES

Canine

BREED

Terrier Mix

SEX

FS

AGE

10yr

WEIGHT

19lb

The stomach presented intact wall layering with a normal wall layer ratio. The lumen of the stomach was empty with no signs of ileus, obstruction or foreign material.

The small intestine presented intact wall layering with 1:3 muscularis/mucosa ratio. The lumen of the small intestine was empty with no signs of mechanical/metabolic ileus, obstruction or foreign material.

Normal visible colon wall layers were present with apparent formed feces in lumen.

Pancreas

The parenchyma of the left limb, body and right limb of the pancreas presented isoechoic to the adjacent omental fat. A normal curvilinear capsule contour of the pancreas was present. The visible pancreatic duct was normal. No signs of active inflammation or neoplastic disease was evident.

Free Abdomen

No omental masses, overt lymphadenopathy or peritoneal effusion was present.

ULTRASONOGRAPHIC FINDINGS

Primary

- Hepatopathy exhibiting normal vascular volume
- Mild gallbladder debris
- Age related renal changes
- Normal adrenal glands

INTERPRETATION OF THE FINDINGS & FURTHER RECOMMENDATIONS

The appearance of the liver was nonspecific but most consistent with benign hepatopathy. Considerations for the liver may include benign vacuolar hepatopathy, inflammatory/infectious/immune mediated disease, hyperplasia, hematopoiesis, toxic hepatopathy (i.e., copper) or other with neoplasia thought less likely. No overt evidence of intra-hepatic or extra-hepatic macroscopic shunt with portal hypoplasia/microvascular dysplasia not definitively excluded. Ultrasound guided FNA of the liver using a 25-gauge needle and assuming normal coagulation parameters would be warranted for screening cytology. Hepatosupportive medications such as Denamarin or Vitamin E as well as Ursodiol due to its antioxidant and immunomodulatory effects within the liver would be warranted, although these medications may not result in decreased hepatic enzyme levels. Leptospirosis titers / PCR may be considered if clinically indicated. Core or surgical biopsy is likely required for definitive diagnosis. No evidence of adrenal pathology as a contributing factor. Anesthetic risk is likely mild if normal ALB, BUN, CHOL and GLU.

INTERPRETED BY

R. McKenzie Daniel,
DVM, DABVP
(Canine and Feline)

IMAGING PERFORMED BY

Matt Heinlein

HOSPITAL NAME

TLC Animal Hospital

REFERRING VET

Brian Giles

INVOICE

24034

DATE

02/27/2026



PATIENT

Chloe Worley

SPECIES

Canine

BREED

Terrier Mix

SEX

FS

AGE

10yr

WEIGHT

19lb

INTERPRETED BY

R. McKenzie Daniel,
DVM, DABVP
(Canine and Feline)

IMAGING PERFORMED BY

Matt Heinlein

HOSPITAL NAME

TLC Animal Hospital

REFERRING VET

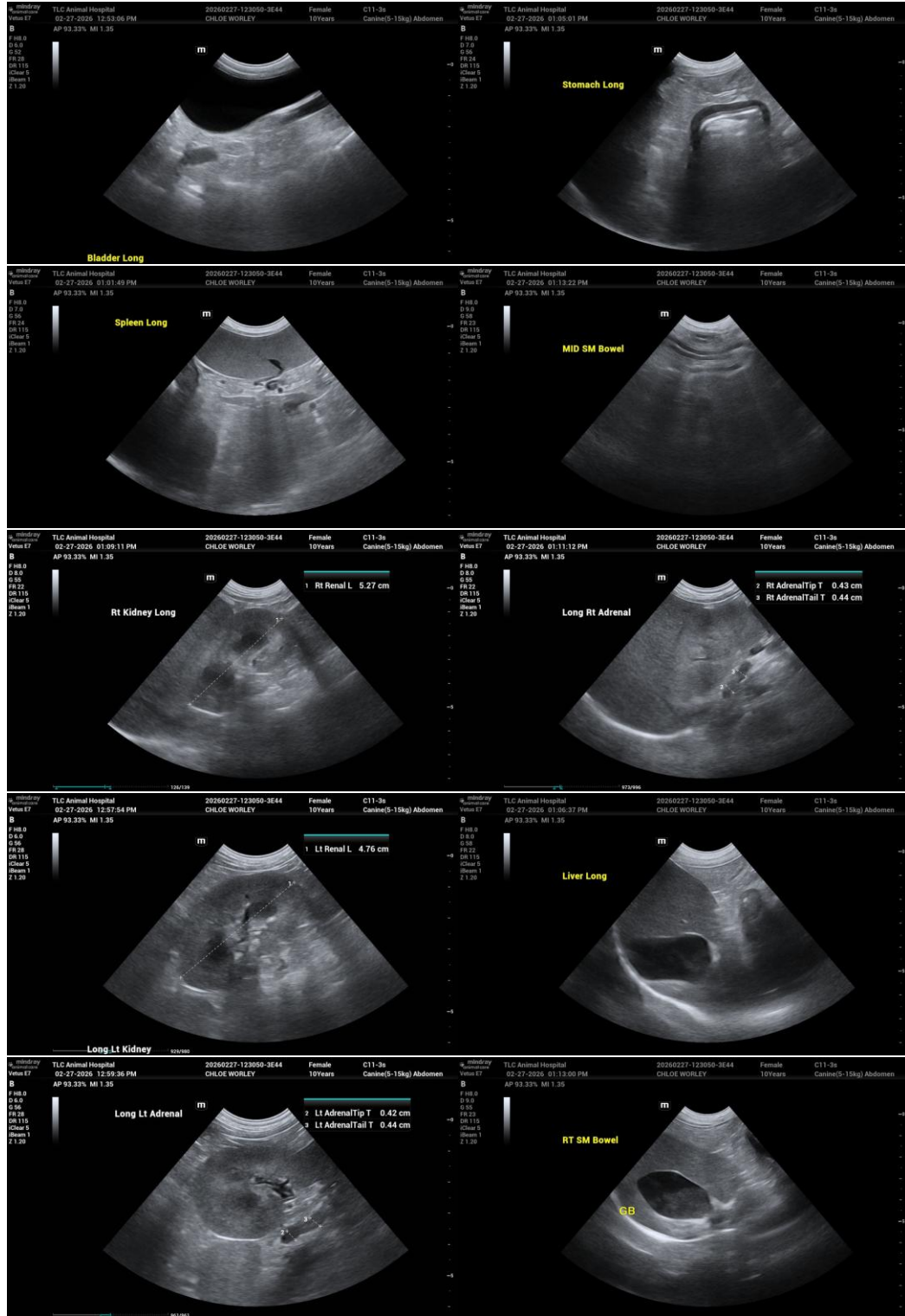
Brian Giles

INVOICE

24034

DATE

02/27/2026



The information and recommendations provided are based on the images presented by the referring



PATIENT

Chloe Worley

veterinarian/sonographer. No evaluation can be communicated regarding pathology that was not visible in the image/video clips provided.

Thank you for this referral. If the clinical or image interpretation does not parallel your findings or if I can be of any further assistance, please contact me.

SPECIES

Canine

R. McKenzie Daniel, DVM, DABVP (Canine/Feline Practice)
info@sonopath.com

BREED

Terrier Mix

SEX

FS

AGE

10yr

WEIGHT

19lb

INTERPRETED BY

R. McKenzie Daniel,
DVM, DABVP
(Canine and Feline)

IMAGING PERFORMED BY

Matt Heinlein

HOSPITAL NAME

TLC Animal Hospital

REFERRING VET

Brian Giles

INVOICE 24034

DATE
02/27/2026