



PATIENT

Reggie Fisher

SPECIES

Feline

BREED

DLH

SEX

Neutered Male

AGE

8

WEIGHT

7.15 kg

INTERPRETED BY

R. McKenzie Daniel,
DVM, DABVP
(Canine and Feline)

IMAGING PERFORMED BY

Dr. Laura de Cordon

HOSPITAL NAME

Mason Dixon Animal
Emergency Hospital

REFERRING VET

Dr. Laura de Cordon

INVOICE

45514

DATE

2/27/23

PRESENTING CLINICAL SIGNS

Abdominal mass Ddx lymphoma vs. carcinoma vs other Febrile Ddx paraneoplastic vs. infection vs. other Icteric/Jaundice Elevated liver values Ddx hepatic lipidosis vs. pancreatitis vs. inflammatory vs. neoplastic vs other Hyporexic Severe weight loss Inappropriate urination Ddx due to illness in general vs. infection vs. cystitis vs other

Abnormal PE/Chem/CBC/UA Results: CBC: WBC 20.03 K, neutrophilia 18.3K, lymphopenia 0.4K, Hct 28 Chem/lytes: Glucose 182, ASLT 223, ALP 506, GGT 30, T> Bili 12.6 T4 wnl, 2.0 PT 24.9 (13-20) aPTT 104.2 (6.5-500) Urinalysis Collected via cystocentesis: SG 1.048, pH 6.0, 1+ glucose, WBC 3-6, no active sediment/bacteria. homogenous mass suspected mid-abdomen.

ULTRASONOGRAPHIC EXAMINATION OF THE ABDOMEN

Urinary System

The urinary bladder was distended with primarily anechoic urine and mild non-dependent particulate sediment, which may indicate cellular debris/protein, crystalline debris, lipid, or mucus. No evidence of inflammatory mural criteria or tumors. The urethra was overtly normal in structure and tone to a depth of 2.0 cm. Anechoic urine was present in the lumen with no uroliths or sediment. The ureteral papillae were normal. The ureters were not visible which is normal. No evidence of inflammatory or neoplastic changes were noted.

The area of the aortic trifurcation was free of pathology.

Normal size and margination were present in the kidneys. A normal 1:3 cortex / medulla ratio and normal corticomedullary definition were maintained. The echogenicity of the cortex was similar to or slightly less than normal liver parenchyma while the medulla echogenicity was hypoechoic to the cortex with no evidence of pelvic dilation. The left kidney measured 4.4 cm. The right kidney measured 4.6 cm.

Adrenal Glands

The left and right adrenal glands were not definitively visualized.

Spleen

The spleen exhibited a finely textured and homogenous parenchyma which was hyperechoic to the liver and renal cortical parenchyma. The capsule was smooth and regular without apparent expansion. A solitary, non-disruptive, non-homogeneous, hyperechoic nodule was noted measuring 0.69 cm in diameter. The overall spleen measured 0.92 cm in width. The splenic vasculature at the hilus was normal in volume with no evidence of congestion or thrombosis.

Liver

The liver was generally enlarged with maintained symmetrical capsule contour. Normal to mildly reduced hepatic parenchyma echogenicity exhibiting moderate coarse echotexture. Normal hepatic vascular volume without congestive criteria. The gallbladder was non-distended in size with thin walls and primarily anechoic luminal content. The cystic and common bile ducts were normal.

Gastrointestinal

The stomach presented intact wall layering with a normal wall layer ratio. The lumen of the stomach was empty with no signs of ileus, obstruction or foreign material.

The small intestine exhibited primarily intact wall layering with mild altered 1:3 muscularis/mucosa ratio owing to propensity for generalized mildly prominent muscularis layer. Within the mid abdomen, an



PATIENT

Reggie Fisher

SPECIES

Feline

BREED

DLH

SEX

Neutered Male

AGE

8

WEIGHT

7.15 kg

INTERPRETED BY

R. McKenzie Daniel,
DVM, DABVP
(Canine and Feline)

IMAGING PERFORMED BY

Dr. Laura de Cordon

HOSPITAL NAME

Mason Dixon Animal
Emergency Hospital

REFERRING VET

Dr. Laura de Cordon

INVOICE

45514

DATE

2/27/23

intestinal mural mass exhibited by mild mural hypertrophy, decreased mural echogenicity, and loss of discernable segmental intestinal wall layering was present. Wall width of the mass measured 0.67 cm. By comparison, intact small intestinal wall layering measured up to 0.30 cm. Probable moderate sized regional mesenteric lymphadenopathy exhibiting abnormal width to length ratio >0.5 and mild non-homogeneous parenchyma. Possibility of extension of the intestinal mural mass considered less likely yet cannot be definitively excluded. Peripheral hyperechoic to mildly non-uniform peri intestinal omentum noted. Probable lymph node measured 4.7 cm x 2.8 cm.

Normal visible colon wall layers were present with apparent formed feces in lumen.

Pancreas

The parenchyma of the left limb, body and right limb of the pancreas presented isoechoic to the adjacent omental fat. A normal curvilinear capsule contour of the pancreas was present. The visible pancreatic duct was normal. No signs of active inflammation or neoplastic disease was evident.

Free Abdomen

Scant to mild volume peritoneal free fluid.

PRIMARY FINDINGS

- Enteropathy with segmental mid abdominal intestinal mural mass, associated probable non-homogeneous mesenteric lymphadenopathy
- Hepatomegaly exhibiting mild non-homogeneous parenchyma, sonographically unremarkable gallbladder – no evidence of post-hepatic obstruction.
- Scant to mild volume peritoneal free fluid
- Distended urinary bladder with mild urinary bladder sediment

SECONDARY FINDINGS

- Normal splenic size with subjective benign nodule – likely consistent with incidental myelolipoma, not overtly consistent with nodular neoplastic criteria.

INTERPRETATION OF THE FINDINGS & FURTHER RECOMMENDATIONS

Although sampling is required for further assessment, primary concern for multicentric neoplasia involving the intestinal tract, mesenteric lymph nodes and liver such as multicentric lymphoma or other is warranted. Non-neoplastic etiologies such as inflammatory hepatopathy, emerging lipidosis, vacuolar hepatic changes, non-obstructive cholestasis, inflammatory intestinal disease, lymphatic hyperplasia, reactive lymphadenitis, dry form FIP possible yet thought less likely. Further assessment may include (assuming normal clotting status and using 25-gauge needle) FNA cytology of probable mesenteric lymph node as well as hepatic cytology with potential for oncology consult.



PATIENT

Reggie Fisher

SPECIES

Feline

BREED

DLH

SEX

Neutered Male

AGE

8

WEIGHT

7.15 kg

INTERPRETED BY

R. McKenzie Daniel,
DVM, DABVP
(Canine and Feline)

IMAGING PERFORMED BY

Dr. Laura de Cordon

HOSPITAL NAME

Mason Dixon Animal
Emergency Hospital

REFERRING VET

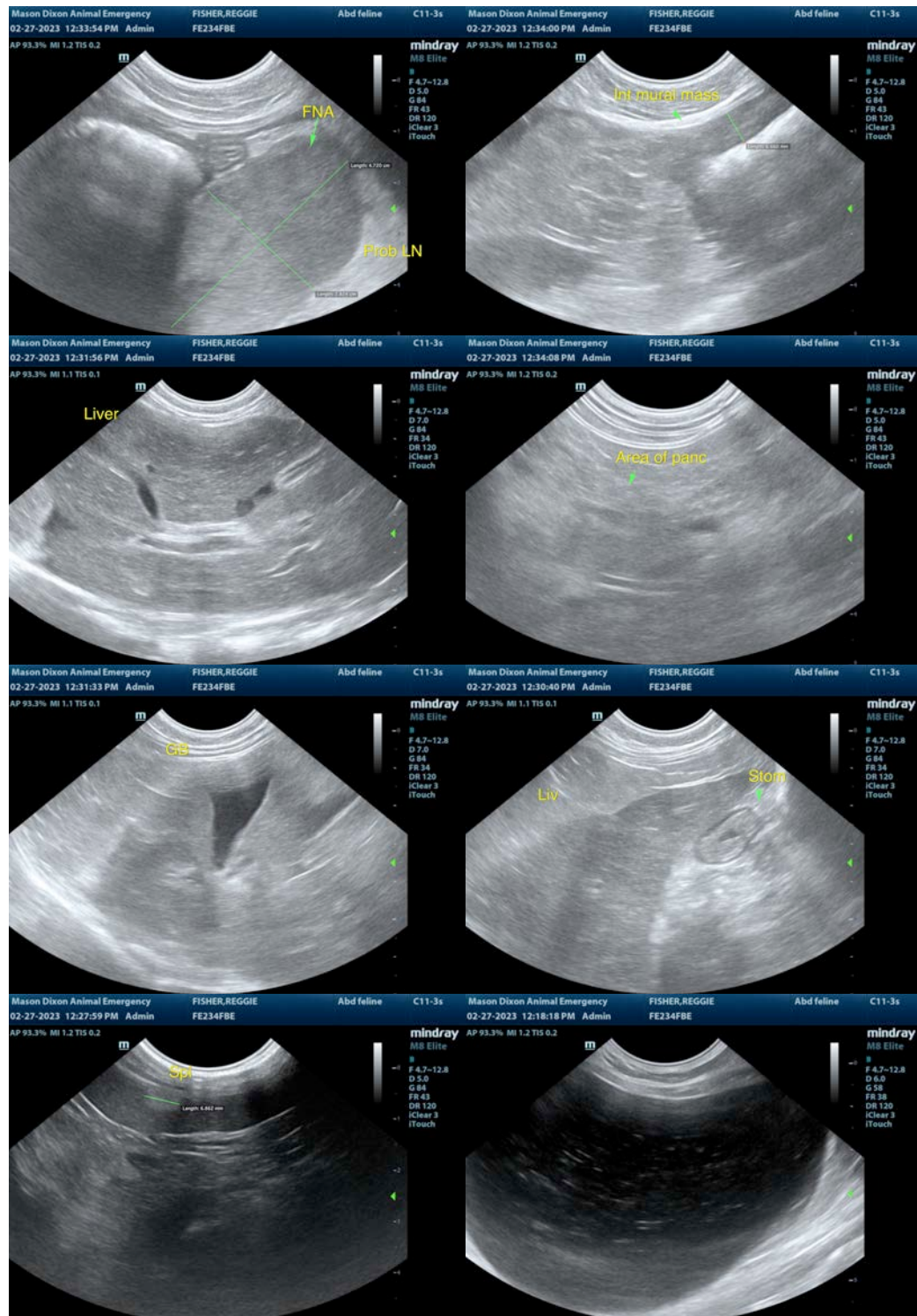
Dr. Laura de Cordon

INVOICE

45514

DATE

2/27/23





PATIENT

Reggie Fisher

SPECIES

Feline

BREED

DLH

SEX

Neutered Male

AGE

8

WEIGHT

7.15 kg

INTERPRETED BY

R. McKenzie Daniel,
DVM, DABVP
(Canine and Feline)

IMAGING PERFORMED BY

Dr. Laura de Cordon

HOSPITAL NAME

Mason Dixon Animal
Emergency Hospital

REFERRING VET

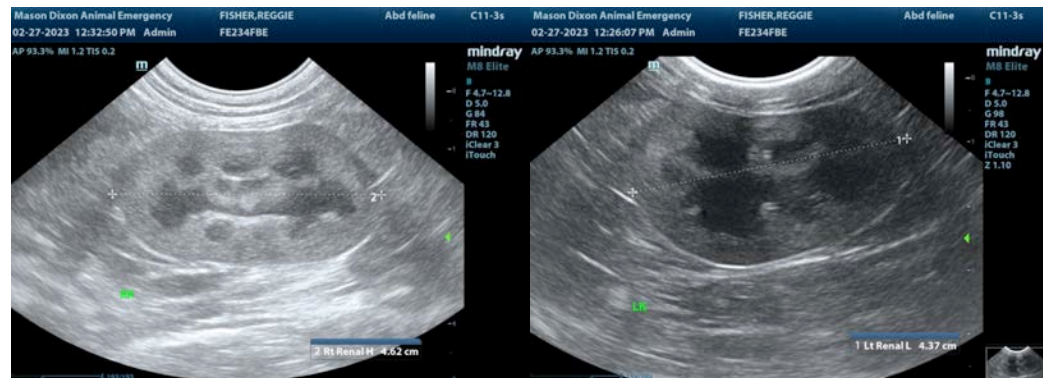
Dr. Laura de Cordon

INVOICE

45514

DATE

2/27/23



The information and recommendations provided are based on the images presented by the referring veterinarian/sonographer. No evaluation can be communicated regarding pathology that was not visible in the image/video clips provided.

Thank you for this referral. If the clinical or image interpretation does not parallel your findings or if I can be of any further assistance please contact me.

R. McKenzie Daniel, DVM, DABVP (Canine / Feline Practice)

info@SonoPath.com