



PATIENT

Pumpkin Cancelliere

SPECIES

Canine

BREED

Terrier X

SEX

Spayed Female

AGE

2

WEIGHT

36.5

INTERPRETED BY

Jenn

IMAGING PERFORMED BY

Jenn

HOSPITAL NAME

Rockaway AH

REFERRING VET

Dr. Maniar

INVOICE

45519

DATE

2/27/23

PRESENTING CLINICAL SIGNS

Recheck prev u/s 12/7 for bloody stool anorexia vomiting showed unremarkable abd, coming in for f/u doing well at home no concerns

ULTRASONOGRAPHIC EXAMINATION OF THE ABDOMEN

Urinary System

The urinary bladder, trigone, cystourethral junction, and visible pelvic urethra to a depth of 3.0 cm exhibited normal thickness and tone. Anechoic urine was present in the lumen with no uroliths or sediment. The ureteral papillae were normal. The ureters were not visible which is normal. No evidence of inflammatory or neoplastic changes were noted.

The area of the aortic trifurcation was free of pathology.

Normal size and margination were present in the kidneys. A normal 1:3 cortex / medulla ratio and normal corticomedullary definition were maintained. The echogenicity of the cortex was similar to or slightly less than normal liver parenchyma while the medulla echogenicity was hypoechoic to the cortex with no evidence of pelvic dilation. The left kidney measured 4.7 cm. The right kidney measured 5.0 cm.

Adrenal Glands

The adrenal glands were uniform in size and contour with a uniformly hypoechoic parenchyma. The left adrenal gland measured 0.49 cm at the caudal pole. The right adrenal gland measured 0.62 cm.

Spleen

The spleen exhibited a finely textured and homogenous parenchyma which was hyperechoic to the liver and renal cortical parenchyma. The capsule was smooth and regular without apparent expansion. The splenic vasculature at the hilus was normal in volume with no evidence of congestion or thrombosis. Acute to chronic inflammatory, neoplastic, or benign parenchyma changes were not noted.

Liver

The liver was subjectively normal in size, structure, and contour. The liver parenchyma was uniform and hypoechoic to the spleen with a mild coarse echotexture. The hepatic and portal vasculature were normal in appearance without signs of congestion. The gallbladder was non-distended in size with thin walls and primarily anechoic luminal content. The cystic and common bile ducts were normal.

Gastrointestinal

The stomach presented intact wall layering with a normal wall layer ratio. The stomach contained a minor amount of retained anechoic fluid. No evidence of retained gastric ingesta, foreign material, or mechanical pyloric outflow obstruction.

The small intestine presented intact wall layering with 1:3 muscularis/mucosa ratio. The lumen of the small intestine was empty with no signs of ileus, obstruction or foreign material.

Normal visible colon wall layers were present with apparent formed feces in lumen.

Pancreas

The parenchyma of the left limb, body and right limb of the pancreas presented isoechoic to the adjacent omental fat. A normal curvilinear capsule contour of the pancreas was present. The visible pancreatic duct was normal. No signs of active inflammation or neoplastic disease was evident.



PATIENT

Free Abdomen

Pumpkin Cancelliere

No overt lymphadenopathy or peritoneal effusion was present.

SPECIES

Canine

ULTRASONOGRAPHIC FINDINGS

- Sonographically unremarkable abdomen
- Minor retained gastric fluid

BREED

Terrier X

INTERPRETATION OF THE FINDINGS & FURTHER RECOMMENDATIONS

SEX

No sonographic evidence of significant visceral pathology, specifically gastroenterocolic pathology. The minor retained gastric fluid is likely incidental if no evidence of vomiting or gastric stasis. Continued as needed gastrointestinal supportive care recommended.

Spayed Female

AGE

2

WEIGHT

36.5

INTERPRETED BY

Jenn

IMAGING PERFORMED BY

Jenn

HOSPITAL NAME

Rockaway AH

REFERRING VET

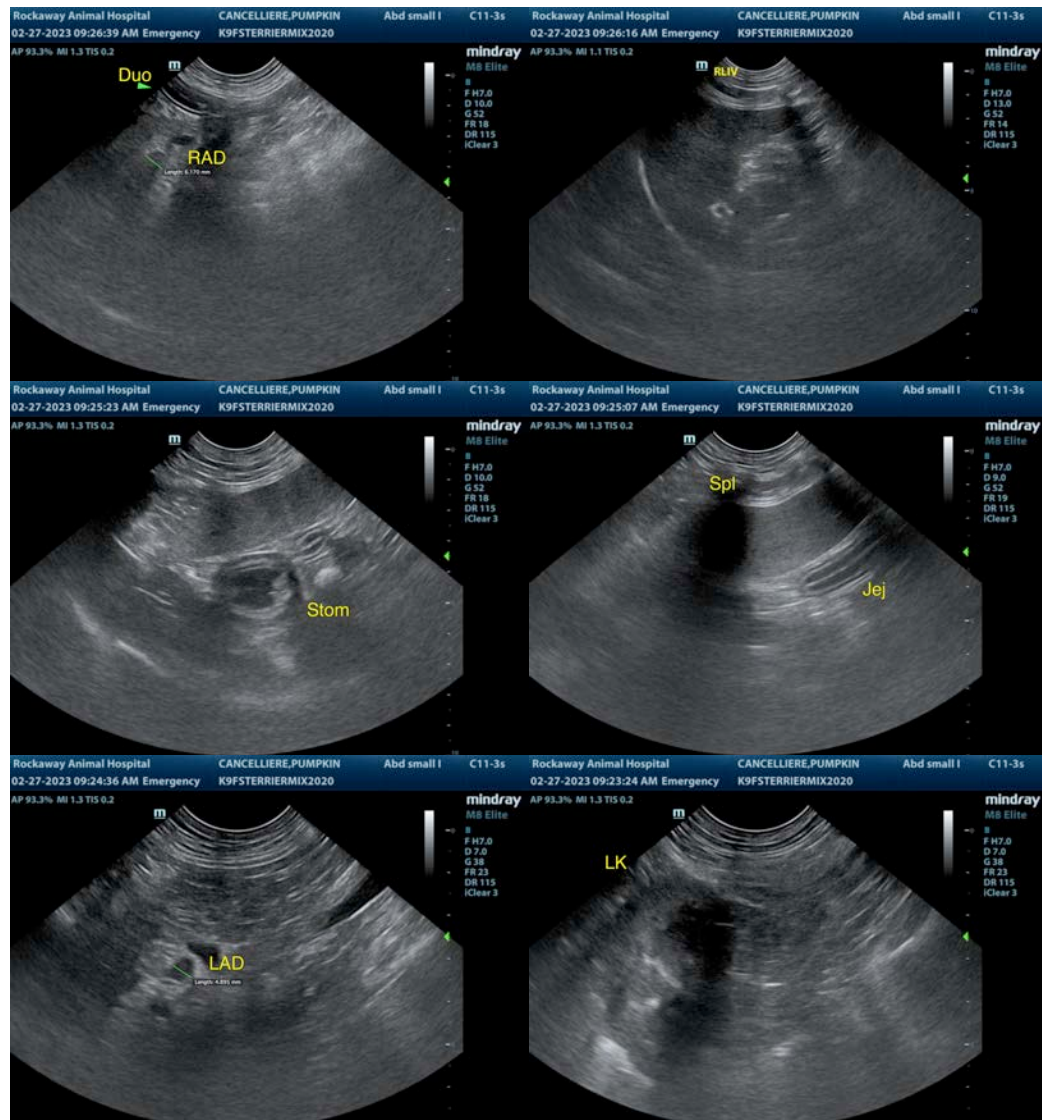
Dr. Maniar

INVOICE

45519

DATE

2/27/23





PATIENT

Pumpkin Cancelliere

SPECIES

Canine

BREED

Terrier X

SEX

Spayed Female

AGE

2

WEIGHT

36.5

INTERPRETED BY

Jenn

IMAGING PERFORMED BY

Jenn

HOSPITAL NAME

Rockaway AH

REFERRING VET

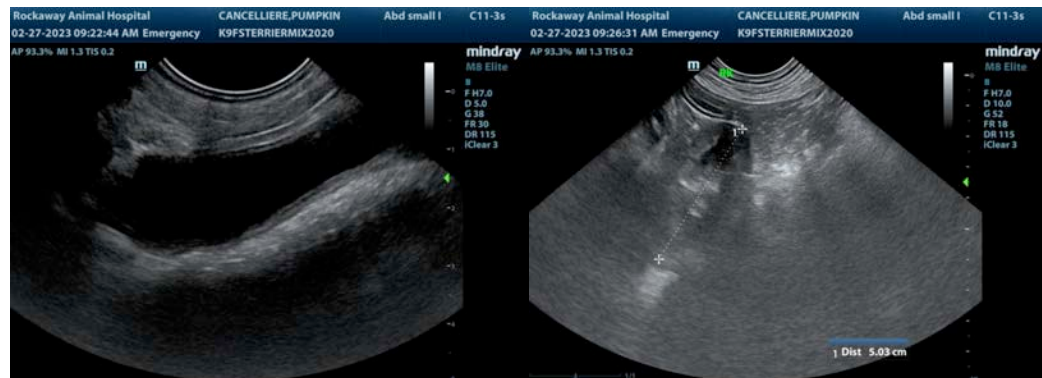
Dr. Maniar

INVOICE

45519

DATE

2/27/23



The information and recommendations provided are based on the images presented by the referring veterinarian/sonographer. No evaluation can be communicated regarding pathology that was not visible in the image/video clips provided.

Thank you for this referral. If the clinical or image interpretation does not parallel your findings or if I can be of any further assistance please contact me.

R. McKenzie Daniel, DVM, DABVP (Canine / Feline Practice)

info@SonoPath.com