



PATIENT	PRESENTING CLINICAL SIGNS
Jameson Sebastian	Recheck had u/s on 2/24 showed gastritis pattern dog is still vomiting.
SPECIES	ULTRASONOGRAPHIC EXAMINATION OF THE ABDOMEN
Canine	Urinary System
BREED	The urinary bladder, trigone, cystourethral junction, and visible pelvic urethra to a depth of – cm exhibited normal thickness and tone. Anechoic urine was present in the lumen with no uroliths or sediment. The ureteral papillae were normal. The ureters were not visible which is normal. No evidence of inflammatory or neoplastic changes were noted.
Mastiff X	
SEX	Normal size and margination was present in the kidneys. A normal 1:3 cortex / medulla ratio was maintained. The medulla and cortices were uniform in texture with some increased echogenicity and loss of corticomedullary symmetry and definition expected for the age of the patient. No evidence of pelvic dilation was present. The left kidney measured 7.0 cm. The right kidney measured 6.6 cm.
Neutered Male	
AGE	Adrenal Glands
9	A mild to discreet non-disruptive hyperechoic nodule was present in the cranial left adrenal gland. The nodule subtly distorted the cranial capsule without significant capsule asymmetry or parenchymal escape. The nodule did not exhibit signs of mineralization or vascular invasion. The nodule measured 1.8 cm x 1.0 cm in diameter. The overall left adrenal gland measured 4.3 cm length x 0.81 cm at the caudal pole.
WEIGHT	The right adrenal gland was borderline prominent in size based on caudal pole width measurement. Mild parenchyma heterogeneity and mild capsule asymmetry was present without suspicion for overt neoplasia. The right adrenal gland measured 3.2 cm length x 1.3 cm at the caudal pole. No evidence of right adrenal neoplastic criteria.
84	
INTERPRETED BY	Spleen
R. McKenzie Daniel, DVM, DABVP (Canine and Feline)	The spleen exhibited a finely textured and homogenous parenchyma which was hyperechoic to the liver and renal cortical parenchyma. The capsule was smooth and regular without apparent expansion. The splenic vasculature at the hilus was normal in volume with no evidence of congestion or thrombosis. Acute to chronic inflammatory, neoplastic, or benign parenchyma changes were not noted.
IMAGING PERFORMED BY	Liver
Jenn	The liver was subjectively normal in size, structure, and contour. The liver parenchyma was mildly nonuniform and hypoechoic to the spleen with a moderate coarse echotexture and subjective mild to benign parenchymal remodeling. The hepatic and portal vasculature were normal in appearance without signs of congestion. The gallbladder was non-distended in size with thin walls and primarily anechoic luminal content. The cystic and common bile ducts were normal.
HOSPITAL NAME	Gastrointestinal
Rockaway AH	The stomach exhibited mild regional ventrally thickened walls with concurrent intact sonographically unremarkable gastric wall layering. Mild retained non-shadowing mildly hyperechoic gastric ingesta present. No overt evidence of mechanical pyloric outflow obstruction or gastric foreign material.
REFERRING VET	The small intestine presented intact wall layering with 1:3 muscularis/mucosa ratio. The lumen of the small intestine was empty with no signs of ileus, obstruction or foreign material.
Dr. Maniar	Normal visible colon wall layers were present with apparent formed feces in lumen.
INVOICE	
45518	
DATE	
2/27/23	



PATIENT

Pancreas

Jameson Sebastian

The parenchyma of the left limb, body and right limb of the pancreas presented isoechoic to the adjacent omental fat. A normal curvilinear capsule contour of the pancreas was present. The visible pancreatic duct was normal. No signs of active inflammation or neoplastic disease was evident.

SPECIES

Canine

Free Abdomen

BREED

Mastiff X

No overt lymphadenopathy or peritoneal effusion was present.

SEX

Neutered Male

AGE

9

ULTRASONOGRAPHIC FINDINGS

- Non-disruptive indistinct cranial left adrenal nodule – suspect adenoma.
- Regional mildly thickened gastric walls with minor retained gastric ingesta
- Sonographically unremarkable small bowel/pancreas
- Minor hepatic parenchymal remodeling – benign.

INTERPRETATION OF THE FINDINGS & FURTHER RECOMMENDATIONS

WEIGHT

84

As in previous study, no overt evidence of gastrointestinal foreign body, with the gastric ingesta noted in the stomach sonographically consistent with food. The mildly thickened gastric walls may suggest inflammatory criteria or infectious disease, while the possibility of emerging infiltrative neoplasia cannot be definitively excluded, given continued vomiting.

INTERPRETED BY

R. McKenzie Daniel,
DVM, DABVP
(Canine and Feline)

Empirically, continued gastritis protocol with coverage for helicobacter and assessment for clinical response would be reasonable. Screening blood pressure recommended to assess for evidence of hypertension, which may allude to more aggressive emerging left adrenal pathology (i.e., pheochromocytoma). Sonographic reassessment of both the stomach wall and left adrenal nodule in 3-4 weeks is recommended. Recheck of the stomach may be considered sooner with potential for endoscopy if persistent vomiting. Spec cPL or PLI could be considered to assess for evidence of low-grade/chronic pancreatitis as a contributing factor.

IMAGING PERFORMED BY

Jenn

HOSPITAL NAME

Rockaway AH

REFERRING VET

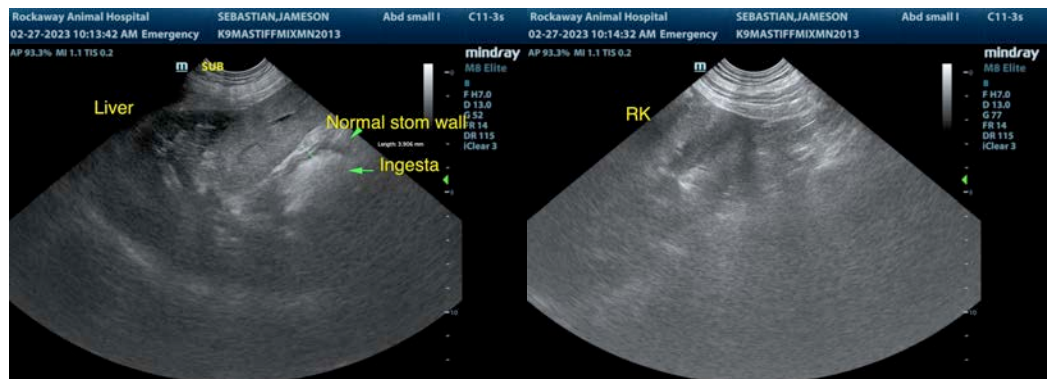
Dr. Maniar

INVOICE

45518

DATE

2/27/23





PATIENT

Jameson Sebastian

SPECIES

Canine

BREED

Mastiff X

SEX

Neutered Male

AGE

9

WEIGHT

84

INTERPRETED BY

R. McKenzie Daniel,
DVM, DABVP
(Canine and Feline)

IMAGING PERFORMED BY

Jenn

HOSPITAL NAME

Rockaway AH

REFERRING VET

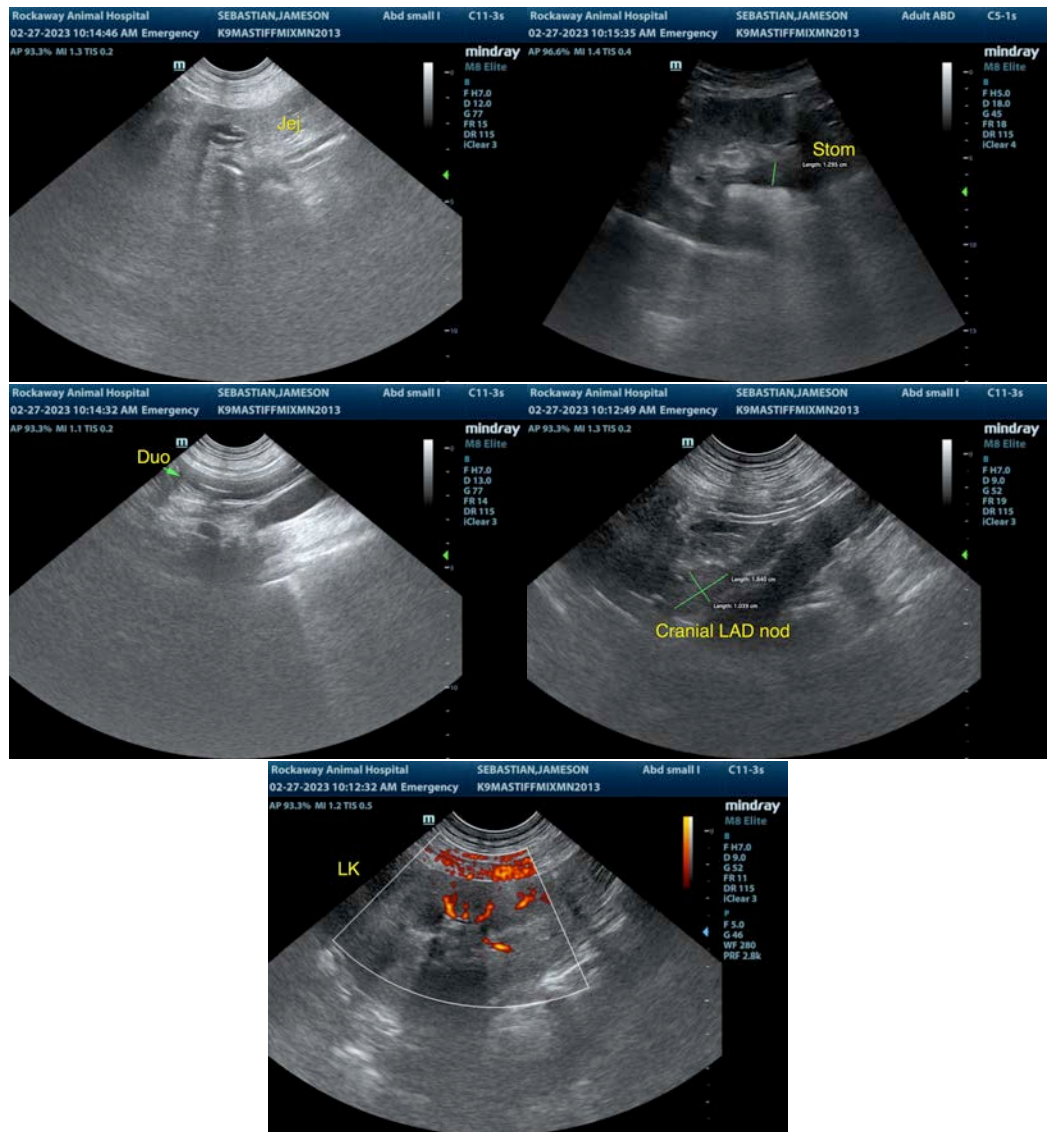
Dr. Maniar

INVOICE

45518

DATE

2/27/23



The information and recommendations provided are based on the images presented by the referring veterinarian/sonographer. No evaluation can be communicated regarding pathology that was not visible in the image/video clips provided.

Thank you for this referral. If the clinical or image interpretation does not parallel your findings or if I can be of any further assistance please contact me.

R. McKenzie Daniel, DVM, DABVP (Canine / Feline Practice)

info@SonoPath.com