



PATIENT PRESENTING CLINICAL SIGNS

Lucy Moore

History:

- Elevated ALT

SPECIES

Canine

Abnormal PE/Chem/CBC/UA Results: ALT 237

BREED

Mixed

ULTRASONOGRAPHIC EXAMINATION OF THE ABDOMEN

SEX

FS

AGE

7 years 8 months

WEIGHT

52 lbs.

INTERPRETED BY

R. McKenzie Daniel,
 DVM, DABVP
 (Canine and Feline)

CANINE CARDIAC PARAMETERS	MR VMAX (m/s)	TR VMAX (m/s)	LA/AO (M-Mode)	LA/AO (Heart Base; Swe)	FS (%)	EF (%)	EPSS (cm)
NORMAL PARAMETER	4.5-5.5	<2.7	1.3	Up to 1.6	28-40	40-100	<0.6
PATIENT	-	-	-	1.1	41	73	0.2
CANINE CARDIAC PARAMETERS	HR (BPM)	AV VMAX (m/s)	PV MAX (m/s)	BODY WEIGHT	LAD LA MAX4 Chamber	LVIDd Avg; 2D and m-mode short axis (cm)	LVIDs Avg; 2D and m-mode short axis (cm)
NORMAL PARAMETER	50-100	0.7-1.7	0.7-1.6				
PATIENT	118	1.5	1.1	52 lbs.	3.8	3.8	-

IMAGING PERFORMED BY

Rebecca Hamilton

HOSPITAL NAME

Marsh AH

REFERRING VET

Dr. Andrew Armani

INVOICE

10660

DATE

2/26/26

Cardiac Presentation

The echocardiogram in this patient demonstrated normal **left atrial** size based on 2 separate methods of LA evaluation. The cranial and caudal **mitral** valve leaflets presented normal linear structure, extension in systole, and union in diastole with normal kinesis. The **left ventricle** presented thicknesses with linear contour and was not dilated nor restricted. The **myocardium** presented normal echogenicity without subjective evidence of significant fibrotic or ischemic disease. **Contractility** of the ventricular walls was adequate and in normal range for this patient evidenced by the fractional shortening measurement and subjective evaluation of the different regions of the myocardium. The **left ventricular outflow** tract demonstrated normal laminar flow and subjective structural integrity. The **right atrium** and auricle revealed normal size, structure and content. No evidence of masses was noted. **Tricuspid** valvular assessment demonstrated adequate linear morphology and kinesis. The **right ventricle** was of normal size (1/3 diameter of LV), chordae structure, myocardial echogenicity and thickness. **Pulmonary outflow** tract assessment revealed normal valve structure, laminar flow, and diameter (approx.1:1 pa/ao ratio). No visible **pericardial** or free pleura fluid was noted. The cranial **mediastinum and pericardial and extra-cardiac regions** were free of masses in the visible window.

Urinary System

The urinary bladder, trigone, cystourethral junction, and visible pelvic urethra to a depth of 2.0 cm exhibited normal thickness and tone. Anechoic urine was present in the lumen with no uroliths or



PATIENT	sediment. No urine mineral or calculi were noted. The ureteral papillae were normal. The ureters were not visible which is normal. No evidence of inflammatory or neoplastic changes were noted.
Lucy Moore	The area of the iliac trifurcation was free of pathology.
SPECIES	Normal size and margination were present in the kidneys. A normal 1:3 cortex / medulla ratio and normal corticomedullary definition were maintained. The echogenicity of the cortex was similar to or slightly less than normal liver parenchyma while the medulla echogenicity was hypoechoic to the cortex with no evidence of pelvic dilation. The left kidney measured 5.8 cm in length. The right kidney measured 6.1 cm in length.
Canine	
BREED	
Mixed	<i>Adrenal Glands</i>
SEX	The left adrenal gland was uniform in size and contour with a uniformly hypoechoic parenchyma. The left adrenal gland measured 0.63 cm width at the caudal pole. The right adrenal gland was uniform in size and contour with a uniformly hypoechoic parenchyma. The right adrenal gland measured 0.55 cm width at the caudal pole.
FS	
AGE	<i>Spleen</i>
7 years 8 months	The spleen exhibited a finely textured and homogenous parenchyma which was hyperechoic to the liver and renal cortical parenchyma. The capsule was smooth and regular without apparent expansion. The splenic vasculature at the hilus was normal in volume with no evidence of congestion or thrombosis. Acute to chronic inflammatory, neoplastic, or benign parenchyma changes were not noted.
WEIGHT	
52 lbs.	<i>Liver/ Gallbladder</i>
INTERPRETED BY	The liver presented mildly enlarged in size. The parenchyma of the liver was subjectively normal in echogenicity compared to the spleen and renal cortices. The liver parenchyma was uniform with a mildly coarse echotexture. The capsule of the liver was symmetrically rounded to mildly swollen in margination. The hepatic and portal vasculature were normal in appearance without signs of congestion. The gallbladder was non-distended in size with thin walls and primarily anechoic luminal content. The cystic and common bile ducts were normal.
R. McKenzie Daniel, DVM, DABVP (Canine and Feline)	<i>Gastrointestinal</i>
IMAGING PERFORMED BY	The stomach presented intact wall layering with a normal wall layer ratio. The lumen of the stomach contained mild nonshadowing ingesta, consistent with food echogenicity without signs of obstruction or foreign material.
Rebecca Hamilton	The small intestine presented intact wall layering with 1:3 muscularis/mucosa ratio. The lumen of the small intestine was empty with no signs of ileus, obstruction, or foreign material.
HOSPITAL NAME	Normal visible colon wall layers were present with formed feces in lumen.
Marsh AH	<i>Pancreas</i>
REFERRING VET	The parenchyma of the left limb, body, and right limb of the pancreas presented isoechoic to the adjacent omental fat. A normal curvilinear capsule contour of the pancreas was present. The visible pancreatic duct was normal. No signs of active inflammation or neoplastic disease were evident.
Dr. Andrew Armani	<i>Free Abdomen</i>
INVOICE	No overt lymphadenopathy or peritoneal effusion was present.
10660	
DATE	
2/26/26	



PATIENT

Lucy Moore

SPECIES

Canine

BREED

Mixed

SEX

FS

AGE

7 years 8 months

WEIGHT

52 lbs.

INTERPRETED BY

R. McKenzie Daniel,
 DVM, DABVP
 (Canine and Feline)

IMAGING PERFORMED BY

Rebecca Hamilton

HOSPITAL NAME

Marsh AH

REFERRING VET

Dr. Andrew Armani

INVOICE

10660

DATE

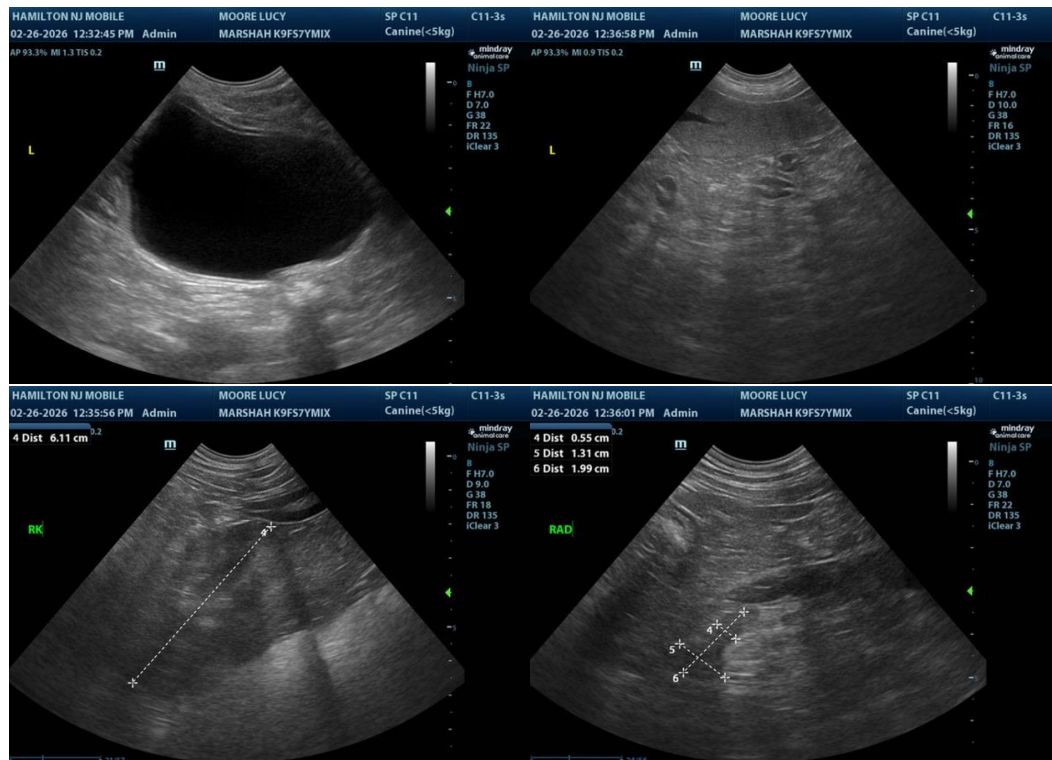
2/26/26

ULTRASONOGRAPHIC FINDINGS

- Normal echocardiogram
- Benign hepatopathy
- Sonographically normal gallbladder

INTERPRETATION OF THE FINDINGS & FURTHER RECOMMENDATIONS

Assuming normal clotting status, hepatic FNA cytology could be considered for initial assessment primarily to evaluate for inflammatory criteria, given ALT elevation. Hepatosupportive medications and monitoring if the patient is nonclinical and given mild hepatic enzyme elevation would be reasonable. Hepatic Biopsies with histopathology for a definitive diagnosis may be considered if progressive hepatopathy is present.





PATIENT

Lucy Moore

SPECIES

Canine

BREED

Mixed

SEX

FS

AGE

7 years 8 months

WEIGHT

52 lbs.

INTERPRETED BY

R. McKenzie Daniel,
 DVM, DABVP
 (Canine and Feline)

IMAGING PERFORMED BY

Rebecca Hamilton

HOSPITAL NAME

Marsh AH

REFERRING VET

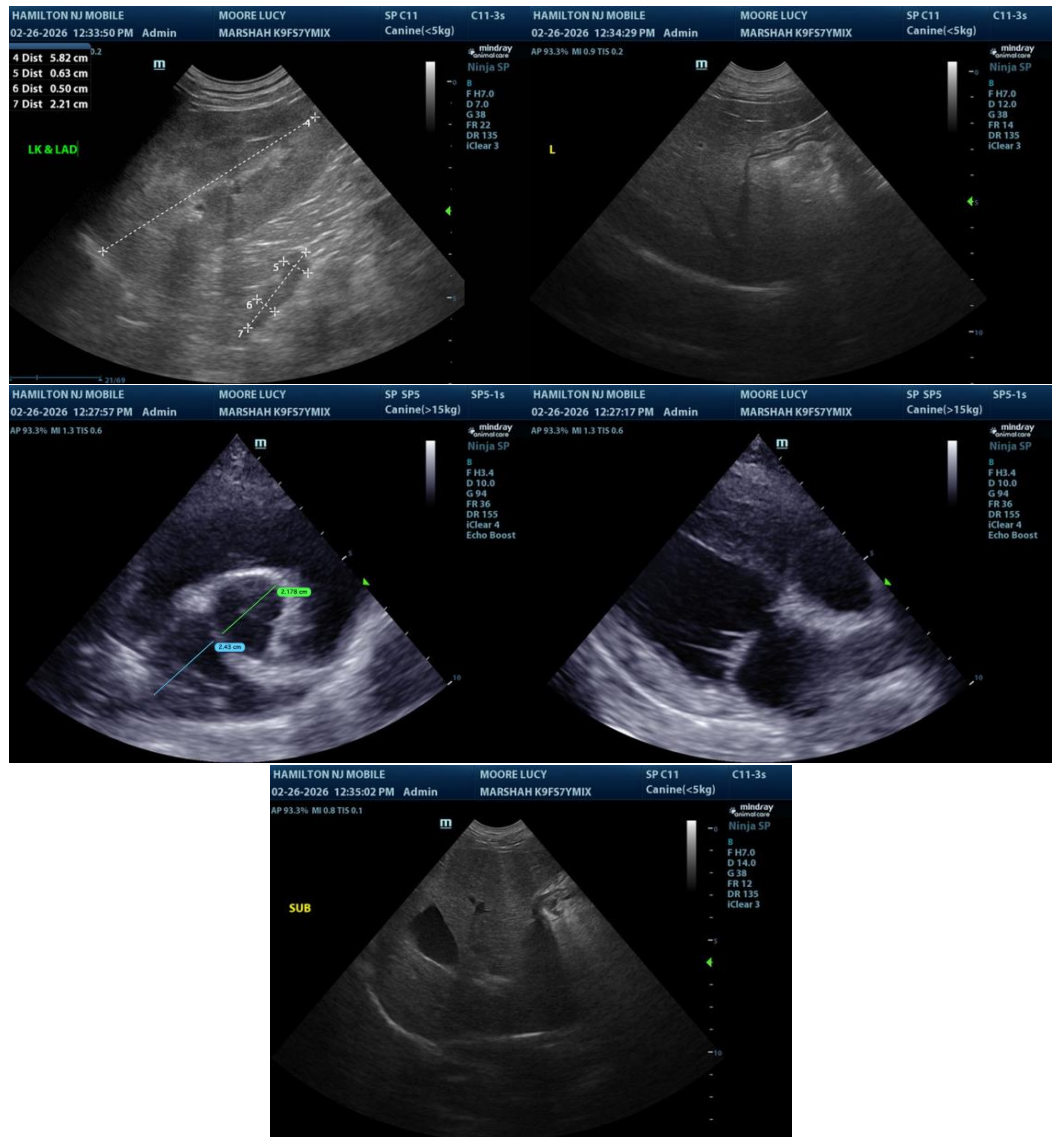
Dr. Andrew Armani

INVOICE

10660

DATE

2/26/26



The information and recommendations provided are based on the images presented by the referring veterinarian/sonographer. No evaluation can be communicated regarding pathology that was not visible in the image/video clips provided.

Thank you for this referral. If the clinical or image interpretation does not parallel your findings or if I can be of any further assistance, please contact me.

R. McKenzie Daniel, DVM, DABVP (Canine/Feline Practice)
info@sonopath.com