



PATIENT

Jase Harrison

SPECIES

Canine

BREED

Dachshund

SEX

Neutered Male

AGE

13 Years 3 Months

WEIGHT

19 pounds

INTERPRETED BY

R. McKenzie Daniel,
DVM, DABVP (Canine
/ Feline Practice)

IMAGING PERFORMED BY

Megan Bray

HOSPITAL NAME

Taylorville Veterinary
Clinic

REFERRING VET

Dr. Elizabeth Stiefvater

INVOICE

13982

DATE

02/26/26

PRESENTING CLINICAL SIGNS

- Jase has Cushing's disease and is managed on Vetoryl, doing well.
- Doctor Stiefvater heard a new heart murmur on 2/20/26, at first sounded like a grade 3/6 but Jase was worked up, he was given Butorphanol and when he calmed down it sounded more like a 1-2/6.
- Jase needs a dental cleaning, and we wanted to evaluate his heart condition prior to anesthesia.

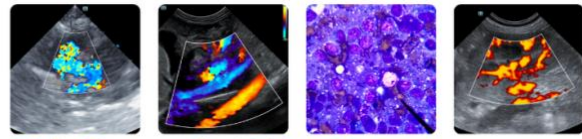
ULTRASONOGRAPHIC EXAMINATION OF THE HEART

CANINE CARDIAC PARAMETERS	MR VMAX (m/s)	TR VMAX (m/s)	LA/AO (M-Mode)	LA/AO (Heart Base; Swe)	FS (%)	EF (%)	EPSS (cm)
NORMAL PARAMETER	4.5-5.5	<2.7	1.3	Up to 1.6	28-40	40-100	<0.6
PATIENT	5.2	--	NM	1.25	48	81	0.2
CANINE CARDIAC PARAMETERS	HR (BPM)	AV VMAX (m/s)	PV MAX (m/s)	BODY WEIGHT (lbs)	LAD LA MAX 4 Chamber	LVIDd Avg; 2D and m-mode short axis (cm)	LVIDs Avg; 2D and m-mode short axis (cm)
NORMAL PARAMETER	50-100	0.7-1.7	0.7-1.6				
PATIENT	NM	1.8	0.9	19.0	2.7	2.6	--

Cardiac Presentation

The echocardiogram in this patient demonstrated normal **left atrial** size based on 3 different LA measurement methods. The cranial and caudal **mitral** valve leaflets presented thickening consistent with endocardiosis. Doppler indicated measurable mild eccentric MR. The **left ventricle** presented thicknesses with linear contour and was not dilated nor restricted. The **myocardium** presented normal echogenicity without subjective evidence of significant fibrotic or ischemic disease. **Contractility** of the ventricular walls was adequate and in normal range for this patient evidenced by the fractional shortening measurement and subjective evaluation of the different regions of the myocardium. The **left ventricular outflow** tract demonstrated normal laminar flow and subjective structural integrity. The **right atrium** and auricle revealed normal size, structure and content. No evidence of masses was noted or chamber overload. **Tricuspid** valvular assessment demonstrated adequate linear morphology. The **right ventricle** was of normal size (1/3 diameter of LV), chordae structure, myocardial echogenicity and thickness. **Pulmonic** tract assessment revealed normal valve structure, laminar flow, and diameter (approx.1:1 pa/ao ratio). No visible **pericardial** or free pleura fluid was noted. No echographically detectable evidence of cardiac / pericardial tumors was visible.

ULTRASONOGRAPHIC FINDINGS



PATIENT

- Chronic mitral valve disease (B1).

Jase Harrison

INTERPRETATION OF THE FINDINGS & FURTHER RECOMMENDATIONS

SPECIES

The cause of the murmur is chronic degenerative valvular changes with secondary eccentric mitral valve insufficiency. The lack of left atrial enlargement implies that the risk of complication secondary to mitral valve insufficiency is low at this time and, without current clinical signs, indicates that medical therapy is not required. Prognosis is considered variable and sonographic monitoring is recommended. Recheck echo cardiogram is suggested in 6-12 months, sooner if clinical signs arise.

Canine

BREED

Dachshund

No anesthetic contraindications. Suggested anesthetic protocol may include opioid or Benzodiazepine pre-med, induction with Propofol or Alfaxalone, and appropriate gas anesthesia with avoidance of alpha 2 agonists.

SEX

Neutered Male

AGE

13 Years 3 Months

WEIGHT

19 pounds

INTERPRETED BY

R. McKenzie Daniel, DVM, DABVP (Canine / Feline Practice)

IMAGING PERFORMED BY

Megan Bray

HOSPITAL NAME

Taylorville Veterinary Clinic

REFERRING VET

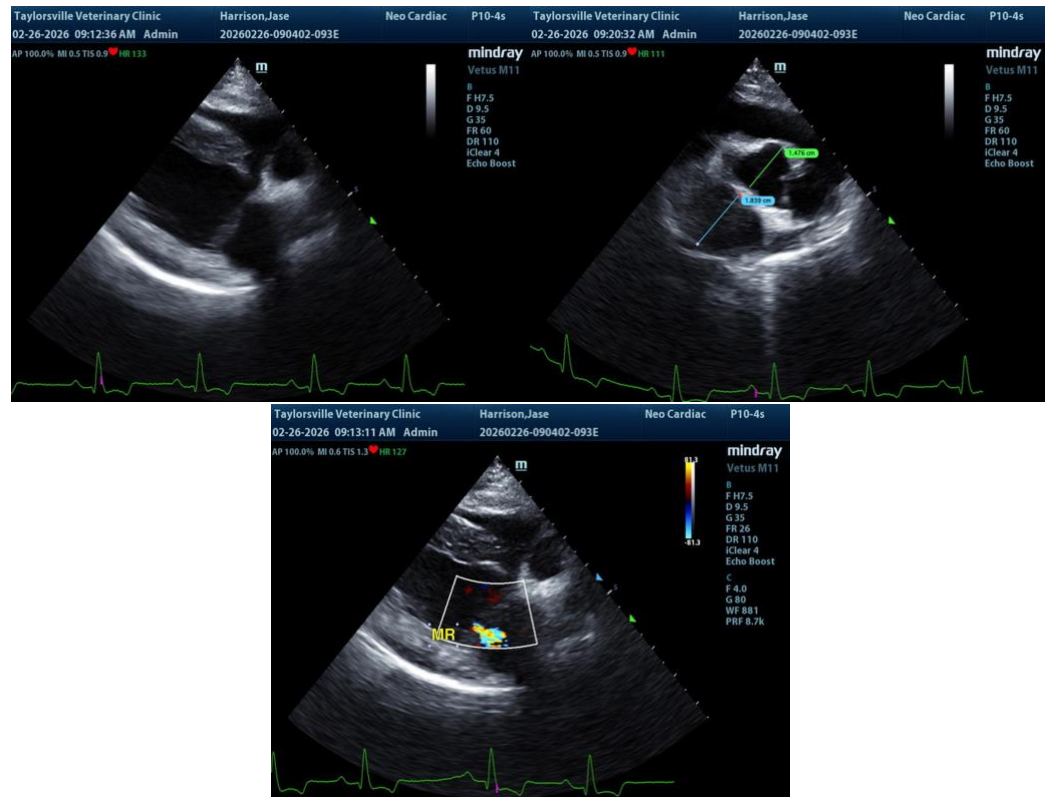
Dr. Elizabeth Stiefvater

INVOICE

13982

DATE

02/26/26

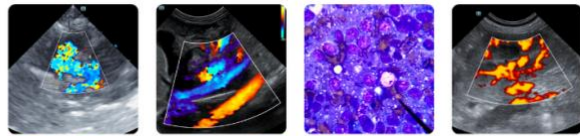


The information and recommendations provided are based on the images presented by the referring veterinarian/sonographer. No evaluation can be communicated regarding pathology that was not visible in the image/video clips provided.

Thank you for this referral. If the clinical or image interpretation does not parallel your findings or if I can be of any further assistance, please contact me.

R. McKenzie Daniel, DVM, DABVP (Canine / Feline Practice)

info@SonoPath.com



PATIENT

Jase Harrison

SPECIES

Canine

BREED

Dachshund

SEX

Neutered Male

AGE

13 Years 3 Months

WEIGHT

19 pounds

INTERPRETED BY

R. McKenzie Daniel,
DVM, DABVP (Canine
/ Feline Practice)

IMAGING PERFORMED BY

Megan Bray

HOSPITAL NAME

Taylorsville Veterinary
Clinic

REFERRING VET

Dr. Elizabeth Stiefvater

INVOICE

13982

DATE

02/26/26