



PATIENT

Dublin Griswold

SPECIES

Canine

BREED

Mix

SEX

Male Neutered

AGE

15y

WEIGHT

Pending

INTERPRETED BY

R. McKenzie Daniel,
DVM, DABVP
(Canine and Feline)

IMAGING PERFORMED BY

Chloe Lowe

HOSPITAL NAME

Magnolia Vet Practice

REFERRING VET

Dr. Goldstein

INVOICE

13238

DATE

2/26/26

PRESENTING CLINICAL SIGNS

History:

- Elevated pli and liver enzymes, vomiting
- Cranial abd pain

Abnormal PE/Chem/CBC/UA Results Hemoconcentrated BUN 31, ALT 472, ALP 1504, GGT 13, Pli 343

ULTRASONOGRAPHIC EXAMINATION OF THE ABDOMEN

Urinary System

The urinary bladder, trigone, cystourethral junction, and visible pelvic urethra to a depth of 2.0 cm exhibited normal thickness and tone. Anechoic urine was present in the lumen with no uroliths or sediment. The ureteral papillae were normal. The ureters were not visible which is normal. No evidence of inflammatory or neoplastic changes were noted.

The area of the residual prostate appeared normal and free of pathology.

The area of the aortic trifurcation was free of pathology.

Normal size and margination was present in the kidneys. A normal 1:3 cortex / medulla ratio was maintained. The medulla and cortices were uniform in texture with some increased echogenicity and mild loss of corticomedullary symmetry and definition expected for the age of the patient. No evidence of pelvic dilation was present. The left kidney measured 5.4 cm in length. The right kidney measured 5.8 cm in length.

Adrenal Glands

The bilateral adrenal glands were normal in size. Mild parenchyma heterogeneity and mild capsule asymmetry was present without suspicion for overt neoplasia. The left adrenal gland measured 0.63 cm width in the caudal pole. The right adrenal gland measured 0.63 cm width in the caudal pole.

Spleen

The spleen exhibited a finely textured and homogenous parenchyma which was hyperechoic to the liver and renal cortical parenchyma. The capsule was smooth and regular without apparent expansion. The splenic vasculature at the hilus was normal in volume with no evidence of congestion or thrombosis. Acute to chronic inflammatory, neoplastic, or benign parenchyma changes were not noted.

Liver

The liver presented mildly enlarged in size. The parenchyma of the liver was subjectively normal in echogenicity compared to the spleen and renal cortices. The liver parenchyma was uniform with a mildly coarse echotexture. The capsule of the liver was symmetrically rounded to mildly swollen in margination. The hepatic and portal vasculature were normal in appearance without signs of congestion. Intermittent, mild, asymmetrical yet well-demarcated, hyperechoic nodules were present with an example measuring 1.1 cm in diameter. The gallbladder was non distended in size with mild,



PATIENT

Dublin Griswold

non-organized, echogenic, nonmineralized biliary sludge. The cystic duct and common bile ducts were normal without evidence of dilation.

SPECIES

Canine

Gastrointestinal

The stomach presented intact wall layering with a normal wall layer ratio. The lumen of the stomach was empty with no signs of ileus, obstruction or foreign material.

BREED

Mix

The small intestine presented intact wall layering with 1:3 muscularis/mucosa ratio. The lumen of the small intestine was empty with no signs of ileus, obstruction or foreign material.

SEX

Male Neutered

Normal visible colon wall layers were present with apparent formed feces in lumen.

Pancreas

The pancreas was normal in size and contour with isoechoic to heterogeneous parenchyma compared to adjacent omentum. No signs of active inflammation or neoplasia.

AGE

15y

Free Abdomen

No overt lymphadenopathy or peritoneal effusion was present.

WEIGHT

Pending

ULTRASONOGRAPHIC FINDINGS

- Hepatopathy exhibiting hyperechoic intraparenchymal nodules – vacuolar/cholestatic hepatopathy, inflammatory changes, areas of hyperechoic nodular hyperplasia or lipogranulomas, potential for emerging to low-grade nodular hepatic neoplasia thought less likely yet not excluded
- Mild gallbladder debris (non-mucocele)
- Mild pancreatic remodeling – chronic pancreatitis possible, potential for benign remodeling owing to age or previous inflammation
- Normal empty gastrointestinal tract
- Age-related renal/adrenal changes

INTERPRETED BY

R. McKenzie Daniel,
DVM, DABVP
(Canine and Feline)

INTERPRETATION OF THE FINDINGS & FURTHER RECOMMENDATIONS

Gastrointestinal support and empirical therapy for chronic pancreatitis is recommended. Concurrent hepato-supportive medications including Denamarin and +/- Ursodiol may prove beneficial. Assuming normal clotting status, hepatic parenchymal inaccessible nodule FNA cytology could be considered for further clarification vs monitoring for evidence of progressive nodular changes or hepatopathy.

**IMAGING
PERFORMED BY**

Chloe Lowe

HOSPITAL NAME

Magnolia Vet Practice

REFERRING VET

Dr. Goldstein

INVOICE

13238

DATE

2/26/26



PATIENT

Dublin Griswold

SPECIES

Canine

BREED

Mix

SEX

Male Neutered

AGE

15y

WEIGHT

Pending

INTERPRETED BY

R. McKenzie Daniel,
 DVM, DABVP
 (Canine and Feline)

IMAGING PERFORMED BY

Chloe Lowe

HOSPITAL NAME

Magnolia Vet Practice

REFERRING VET

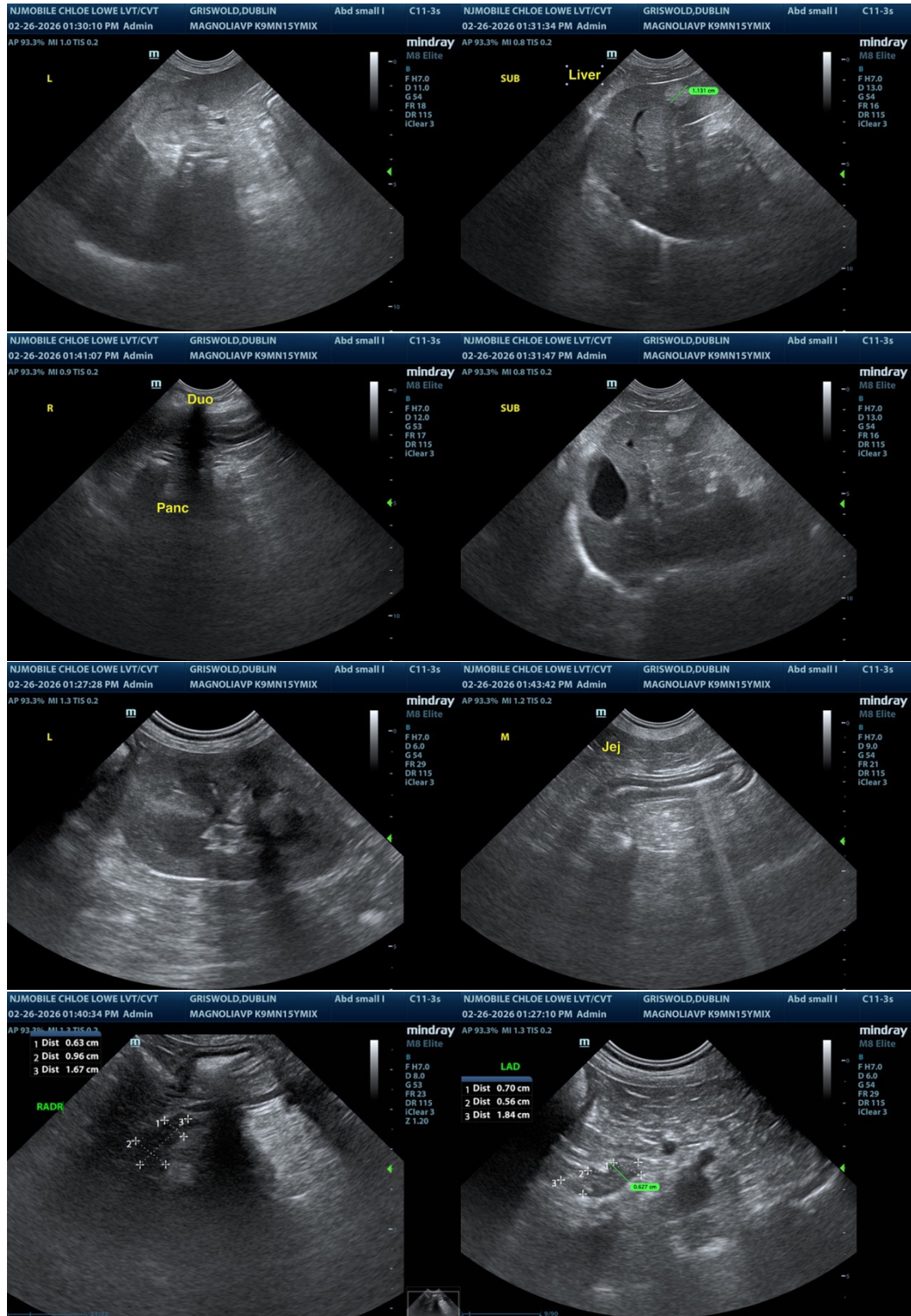
Dr. Goldstein

INVOICE

13238

DATE

2/26/26





PATIENT

Dublin Griswold

SPECIES

Canine

BREED

Mix

SEX

Male Neutered

AGE

15y

WEIGHT

Pending

INTERPRETED BY

R. McKenzie Daniel,
DVM, DABVP
(Canine and Feline)

IMAGING PERFORMED BY

Chloe Lowe

HOSPITAL NAME

Magnolia Vet Practice

REFERRING VET

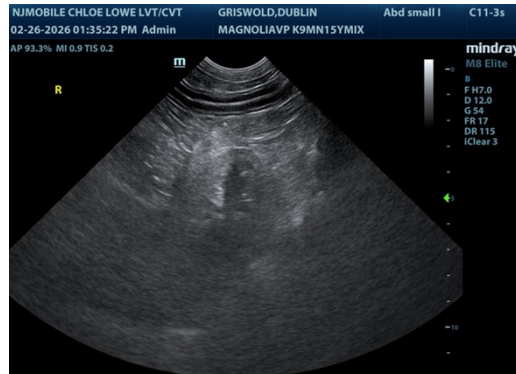Dr. Goldstein

INVOICE

13238

DATE

2/26/26



The information and recommendations provided are based on the images presented by the referring veterinarian/sonographer. No evaluation can be communicated regarding pathology that was not visible in the image/video clips provided.

Thank you for this referral. If the clinical or image interpretation does not parallel your findings or if I can be of any further assistance, please contact me.

R. McKenzie Daniel, DVM, DABVP (Canine / Feline Practice)

info@sonopath.com