

**PATIENT**

CJ Bahl

SPECIES

Canine

BREED

Beagle

SEX

Neutered male

AGE

10 years

WEIGHT

33 pounds

INTERPRETED BYR. McKenzie Daniel,
DVM, DABVP
(Canine and Feline)**IMAGING PERFORMED BY**

Sarah Pender CVT

HOSPITAL NAME

SVS Imaging QC

REFERRING VET

Dr. Phil Olsen

INVOICE

10075ag

DATE

02/25/2022

PRESENTING CLINICAL SIGNS

Abnormal PE/Chem/CBC/UA Results: 12/6/21 UA Protein 500mg/dl, SG1.022, BLD 250Ery/ul, WBC 4/hpf, RBC 46/HPF, nonsquamous 1-2/hpf CBC WNL, CHEM 17 WNL 12/16/21 UA SG 1.013, Protein 30, BLD 250, WBC 2/hpf, RBC 35/hpf Nonsquamous 1-2/hpf 02/18/22 UA SG1.021 Protein500, Bld 250, WBC 45/hpf, RBC>50/hpf Squamous 1/hpf, non-squamous >10/hpf, struvite <1/hpf FNA of prostate and cystocentesis for C/S done at time of scan.

ULTRASONOGRAPHIC EXAMINATION OF THE ABDOMEN**Urinary System**

The urinary bladder, trigone, cystourethral junction, and visible pelvic urethra exhibited normal thickness and tone. Anechoic urine was present in the lumen with very mild nondependent particulate. A focal area of potential dorsal mural hypertrophy measuring 0.5 cm in diameter was present and exhibited similar echogenicity compared to the adjacent urinary bladder wall. Possible accumulated sediment cannot be excluded. The ureteral papillae were normal. The ureters were not visible which is normal.

Normal size and margination was present in the kidneys. A normal 1:3 cortex / medulla ratio was maintained. The medulla and cortices were uniform in texture with some mildly increased echogenicity and mild loss of corticomedullary symmetry and definition expected for the age of the patient. No evidence of pyelectasia was present. The left kidney measured 6.5 cm in length. The right kidney measured 6.5 cm in length.

The residual prostate was enlarged in size. Possible extension of the prostatic parenchyma into the proximal urethra and cystourethral junction is possible. The margins of the gland were indistinct and difficult to differentiate from the surrounding tissue. The prostate measured 3.3 cm x 2.3 cm.

The area of the aortic trifurcation appears normal without evidence of sub lumbar or medial iliac lymphadenopathy.

Adrenal Glands

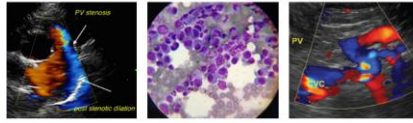
The left adrenal gland was uniform in size and contour with a uniformly hypoechoic parenchyma. The left adrenal gland measured 0.61 cm width at the caudal pole and 0.37 cm width at the cranial pole. The right adrenal gland was uniform in size and contour with a uniformly hypoechoic parenchyma. The right adrenal gland measured 0.44 cm width at the caudal pole and 0.54 cm width at the cranial pole.

Spleen

The spleen exhibited primarily finely textured and homogenous parenchyma which was hyperechoic to the liver and renal cortical parenchyma. A solitary small echogenic nodule in the medial parenchyma adjacent to the hilus. The capsule was smooth and regular without apparent expansion. The splenic vasculature at the hilus was normal in volume with no evidence of congestion or thrombosis. Acute to chronic inflammatory or neoplastic changes were not noted. The echogenic nodules tend to trend benign and are most consistent with benign hyperplasia or myelolipomas.

Liver

The liver presented enlarged in size with generalized parenchymal remodeling. The parenchyma of the liver was subjectively normal in echogenicity compared to the spleen and renal cortices. The capsule of the liver was symmetrically rounded to mildly swollen in margination. The hepatic and portal vasculature were normal in appearance without signs of congestion. The gallbladder was non distended in size with mild dependent to nondependent yet nonorganized and subjectively mobile debris. No evidence of



PATIENT peripheral inflammation was present. The cystic duct and common bile ducts were normal without evidence of dilation.

CJ Bahl

Gastrointestinal

SPECIES

The stomach presented intact wall layering with a normal wall layer ratio. The lumen of the stomach was empty with no signs of ileus, obstruction or foreign material.

Canine

The small intestine presented intact wall layering with 1:3 muscularis/mucosa ratio. The lumen of the small intestine was empty with no signs of ileus, obstruction or foreign material.

BREED

Beagle

Normal visible colon wall layers were present with apparent formed feces in lumen.

Pancreas

SEX

The parenchyma of the pancreas was hyperechoic to adjacent omental fat with diffuse parenchyma remodeling. The capsule of the pancreas was mildly asymmetrical in contour without evidence of peripancreatic inflammation. These changes may suggest chronic inflammation, fibrosis, or saponification if previous history of pancreatitis. No overt signs of pancreatic neoplasia.

Neutered male

AGE

Free Abdomen

10 years

No overt lymphadenopathy or peritoneal effusion was present.

WEIGHT

33 pounds

ULTRASONOGRAPHIC FINDINGS

INTERPRETED BY

R. McKenzie Daniel,
DVM, DABVP
(Canine and Feline)

- Enlarged residual prostate exhibiting nonhomogeneous to mineralized parenchyma.
- Focal dorsal urinary bladder mural hypertrophy, potential for dependent accumulated sediment-focal cystitis. Potential for emerging neoplasia possible.
- Mild age-related renal changes, no overt pyelectasia.
- Mild gallbladder debris (non-mucocele).
- Mild hepatic parenchymal remodeling-subjectively benign.
- Solitary small benign splenic nodule-consistent with probable myelolipoma.
- Chronic pancreatitis/fibrosis pattern.

IMAGING PERFORMED BY

Sarah Pender CVT

HOSPITAL NAME

SVS Imaging QC

INTERPRETATION OF THE FINDINGS & FURTHER RECOMMENDATIONS

The presentation of the residual prostate is consistent with neoplastic criteria such as prostatic or urothelial carcinoma. Concern for potential extension of prostatic parenchyma into the adjacent proximal urethra is warranted. Likewise, potential for focal dorsal urinary bladder wall involvement cannot be excluded. No evidence of regional lymphatic metastasis.

REFERRING VET

Dr. Phil Olsen

Pending prostatic cytology and urine C/S, prostatic biopsy may be required for definitive diagnosis. An oncology consult is recommended if neoplastic process is confirmed.

INVOICE

10075ag

Three view chest radiographs are suggested if not done.

DATE

02/25/2022



PATIENT

CJ Bahl

SPECIES

Canine

BREED

Beagle

SEX

Neutered male

AGE

10 years

WEIGHT

33 pounds

INTERPRETED BY

R. McKenzie Daniel,
DVM, DABVP
(Canine and Feline)

IMAGING PERFORMED BY

Sarah Pender CVT

HOSPITAL NAME

SVS Imaging QC

REFERRING VET

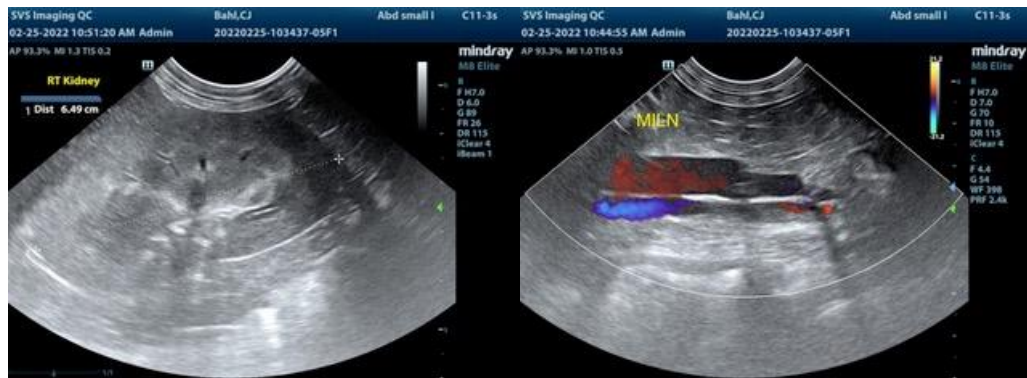
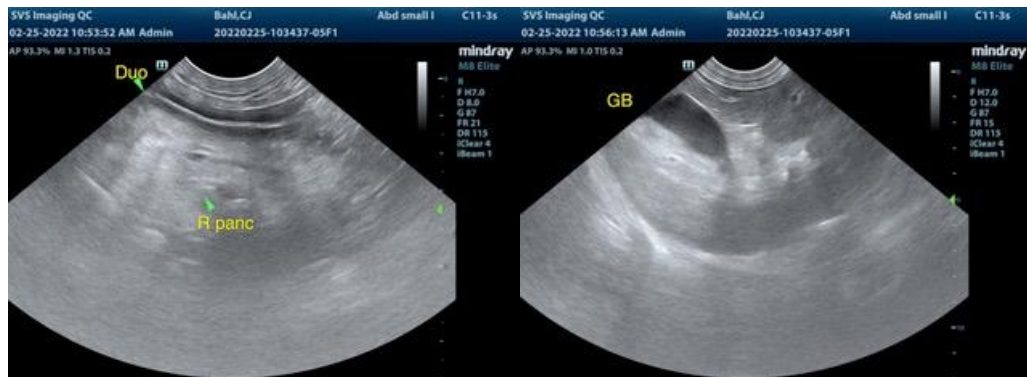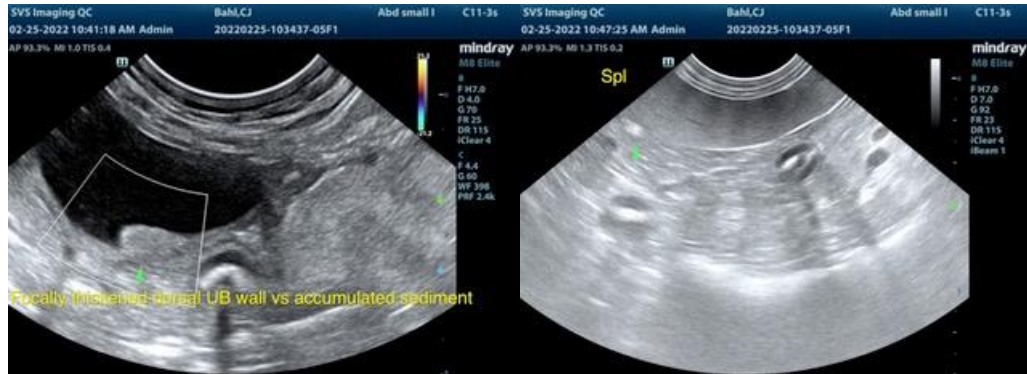Dr. Phil Olsen

INVOICE

10075ag

DATE

02/25/2022





PATIENT

CJ Bahl

SPECIES

Canine

BREED

Beagle

SEX

Neutered male

AGE

10 years

WEIGHT

33 pounds

INTERPRETED BY

R. McKenzie Daniel,
DVM, DABVP
(Canine and Feline)

IMAGING PERFORMED BY

Sarah Pender CVT

HOSPITAL NAME

SVS Imaging QC

REFERRING VET

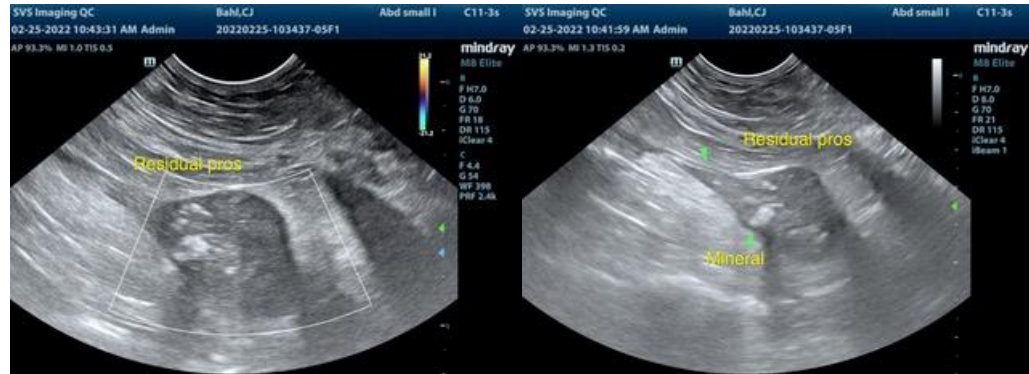Dr. Phil Olsen

INVOICE

10075ag

DATE

02/25/2022



The information and recommendations provided are based on the images presented by the referring veterinarian/sonographer. No evaluation can be communicated regarding pathology that was not visible in the image/video clips provided.

Thank you for this referral. If the clinical or image interpretation does not parallel your findings or if I can be of any further assistance please contact me.

R. McKenzie Daniel, DVM, DABVP (Canine / Feline Practice)

info@SonoPath.com