

**PATIENT**

Chopper Schaffer

SPECIES

Canine

BREED

Pit Bull

SEX

Intact Male

AGE

10 years

WEIGHT

91 lbs.

INTERPRETED BYR. McKenzie Daniel,
DVM, DABVP
(Canine and Feline)**IMAGING
PERFORMED BY**

Sarah Pender, CVT

HOSPITAL NAME

SVS Imaging QC

REFERRING VET

Dr. Hitzhusen

INVOICE

13428

DATE

2/25/22

PRESENTING CLINICAL SIGNS

Wednesday vomited food twice, had a couple episodes of what appeared to be tremors. Temp 105 Thursday. Has continued to have episodes of tremors. Seems ataxic and unable to walk. Seems incontinent. Decreased appetite

Abnormal PE/Chem/CBC/UA Results: T101.8, mild Jaundice, painful abdomen, Rads: possible abdominal mass WBC 19, neut 18, lymph 0.58, HCT 41%, TP 7.7, Glob 3.7, GGT 47, Tbil 2.4

ULTRASONOGRAPHIC EXAMINATION OF THE ABDOMEN**Urinary System**

The urinary bladder, trigone, and cystourethral junction exhibited normal thickness and tone. Anechoic urine was present in the lumen with no uroliths or sediment. The ureteral papillae were normal. The ureters were not visible which is normal. No evidence of inflammatory or neoplastic changes was noted.

The prostate was mildly enlarged in size with intact, symmetrical capsule contour. The margins of the gland were intact and able to be differentiated from the surrounding tissue. The prostatic parenchyma was mildly echogenic to heteroechoic without parenchymal mineralization. The prostate measured 4.4 cm x 2.6 cm.

Multiple medial iliac lymph nodes were present. These lymph nodes were mildly prominent in size, homogenous, mildly hypoechoic and smoothly marginated. A normal width: length ratio was maintained (<0.5). Evidence of perilymphatic inflammation was evident. An example of lymph nodes size was 2.5 cm x 1.0 cm.

The left kidney was enlarged in size with complete loss of discernable corticomedullary architecture and parenchyma. The left kidney parenchyma was replaced by significantly cellular fluid. Suspect nonhomogeneous to mixed echogenic mass at the level of the renal hilus measuring approximately 3.6 cm in diameter was present. Possible unspecified nonhomogeneous mass was present in the area of the left retroperitoneal space subjectively caudal to the left kidney measuring approximately 7.0-8.0 cm in length. Concurrent retroperitonitis was present.

Normal size and margination were present in the right kidney. A normal 1:3 cortex / medulla ratio was maintained. The medulla and cortices were uniform in texture with some increased echogenicity and mild to moderate loss of corticomedullary symmetry and definition expected for the age of the patient. No evidence of pelvic dilation was present. The right kidney measured 8.4 cm in length.

Adrenal Glands

The left adrenal gland was uniform in size and contour with a uniformly hypoechoic parenchyma. The left adrenal gland measured 0.52 cm width at the caudal pole and 0.45 cm width at the cranial pole. The right adrenal gland was uniform in size and contour with a uniformly hypoechoic parenchyma. The right adrenal gland measured 0.35 cm width at the caudal pole and 0.72 cm width at the cranial pole.

Spleen

The spleen exhibited primarily finely textured parenchyma which was hyperechoic to the liver and renal cortical parenchyma. Mild generalized parenchyma heterogeneity was present without evidence

**PATIENT**

Chopper Schaffer

SPECIES

Canine

BREED

Pit Bull

SEX

Intact Male

AGE

10 years

WEIGHT

91 lbs.

INTERPRETED BYR. McKenzie Daniel,
DVM, DABVP
(Canine and Feline)**IMAGING
PERFORMED BY**

Sarah Pender, CVT

HOSPITAL NAME

SVS Imaging QC

REFERRING VET

Dr. Hitzhusen

INVOICE

13428

DATE

2/25/22

of nodular changes. The capsule was smooth and regular without apparent expansion. The splenic vasculature at the hilus was normal in volume with no evidence of congestion or thrombosis. The parenchymal heterogeneity is likely consistent with benign changes such as extramedullary hematopoiesis or age-related remodeling with minor potential for inflammatory or neoplastic disease.

Liver/ Gallbladder

The liver was subjectively normal in size, structure, and contour. The liver parenchyma was mildly nonuniform and hypoechoic to the spleen with a moderate coarse echotexture and subjective mild to benign parenchymal remodeling. The hepatic and portal vasculature were normal in appearance without signs of congestion. The gallbladder was non-distended in size with mild congealed yet nonorganized, nonmineralized gallbladder debris. The cystic and common bile ducts were normal.

Gastrointestinal

The stomach presented intact wall layering with a normal wall layer ratio. The lumen of the stomach contained echogenic, nonshadowing ingesta most consistent with post prandial presentation without signs of ileus, obstruction or foreign material.

The small intestine presented intact wall layering with 1:3 muscularis/mucosa ratio. The lumen of the small intestine was empty with no signs of ileus, obstruction, or foreign material.

Normal visible colon wall layers were present with apparent formed feces in lumen.

Pancreas

The parenchyma of the left limb, body, and right limb of the pancreas presented isoechoic to the adjacent omental fat. A normal curvilinear capsule contour of the pancreas was present. The visible pancreatic duct was normal. No signs of active inflammation or neoplastic disease were evident.

Free Abdomen

Concurrent mild to moderate volume peritoneal free fluid exhibiting potential for cellular component was present. Mild generalized reactive mesentery was present. No overt evidence of significant mesenteric lymphadenopathy was noted.

ULTRASONOGRAPHIC FINDINGS***Primary Findings***

- Left kidney hydronephrosis / pyonephrosis with suspect mass lesion at level of left kidney hilus
- Possible unspecified left retroperitoneal mass or potential abscess with concurrent retroperitonitis
- Concurrent mild to moderate volume potentially cellular peritoneal free fluid

Secondary Findings

- Right kidney mild to moderate chronic renal changes
- Mild gallbladder debris (non-mucocele)



PATIENT

Chopper Schaffer

- Gastroenteritis pattern with mild gastric ingesta
- Mild benign prostatic hyperplasia

SPECIES

Canine

BREED

Pit Bull

SEX

Intact Male

AGE

10 years

WEIGHT

91 lbs.

INTERPRETED BY

R. McKenzie Daniel,
DVM, DABVP
(Canine and Feline)

IMAGING PERFORMED BY

Sarah Pender, CVT

HOSPITAL NAME

SVS Imaging QC

REFERRING VET

Dr. Hitzhusen

INVOICE

13428

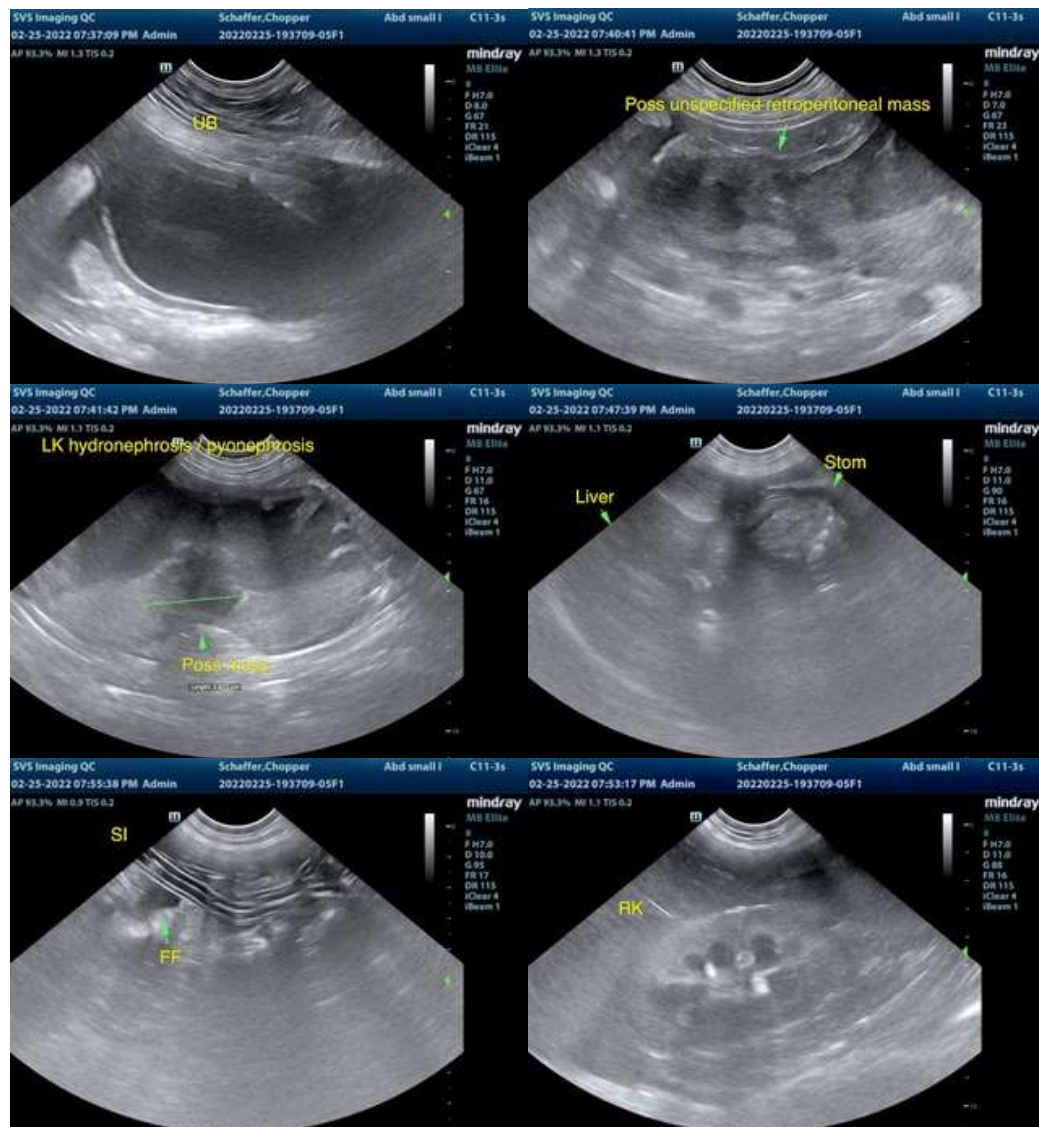
DATE

2/25/22

INTERPRETATION OF THE FINDINGS & FURTHER RECOMMENDATIONS

Under sedation or anesthesia, ultrasound-guided centesis of the left kidney for fluid analysis, cytology, culture and sensitivity, as well as FNA of the possible unspecified retroperitoneal mass for cytology, could be considered. Concurrent peritoneal effusion analysis, cytology +/- culture and sensitivity for correlation would be appropriate.

CT is likely ideal for further assessment, as well as potential for surgical planning if surgical options are a potential in this case, if possible. Three view chest radiographs to rule out occult thoracic pathology and empirical gastrointestinal support are recommended. A very guarded prognosis is warranted.





PATIENT

Chopper Schaffer

SPECIES

Canine

BREED

Pit Bull

SEX

Intact Male

AGE

10 years

WEIGHT

91 lbs.

INTERPRETED BY

R. McKenzie Daniel, DVM, DABVP (Canine and Feline)

IMAGING PERFORMED BY

Sarah Pender, CVT

HOSPITAL NAME

SVS Imaging QC

REFERRING VET

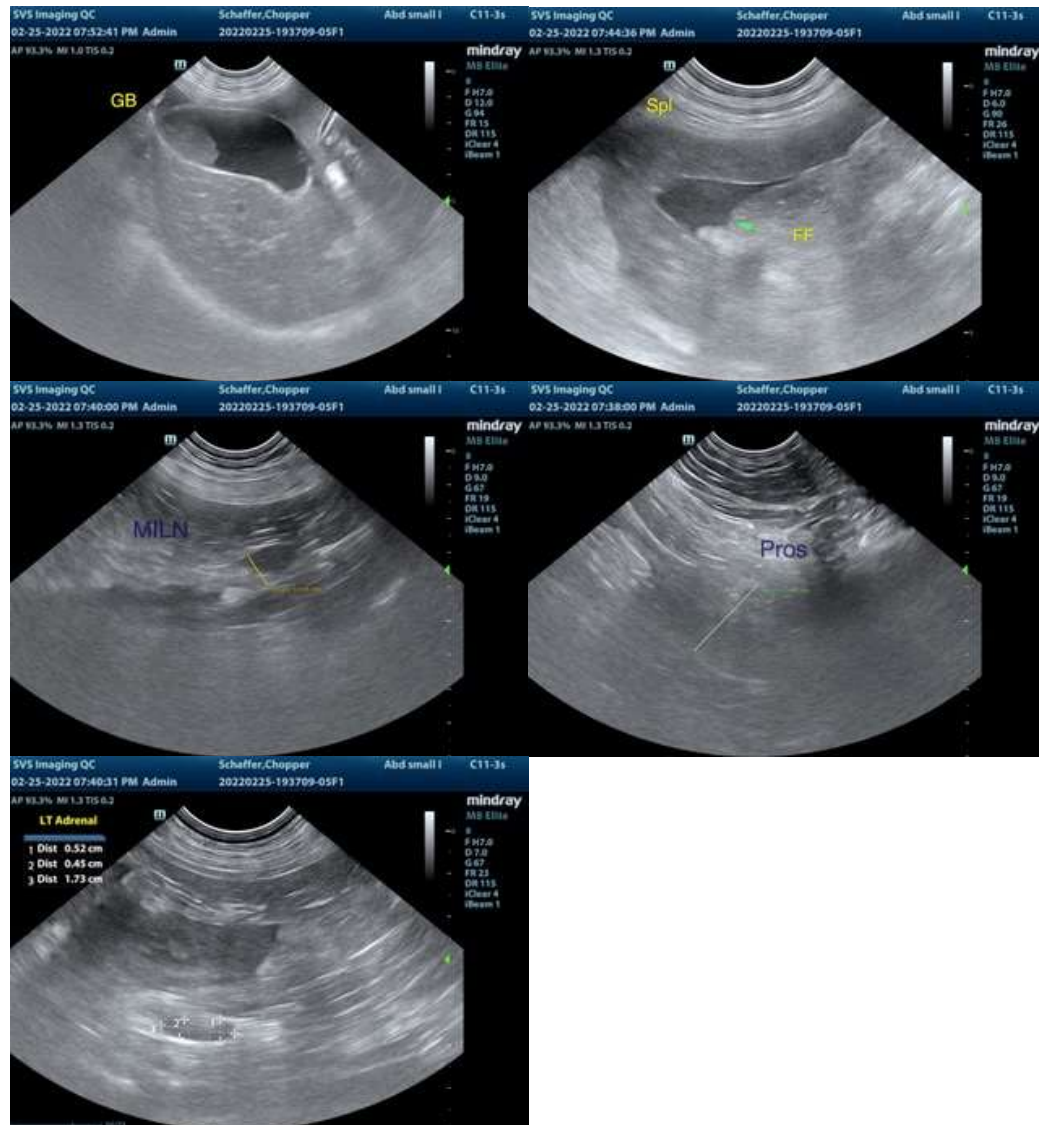
Dr. Hitzhusen

INVOICE

13428

DATE

2/25/22



The information and recommendations provided are based on the images presented by the referring veterinarian/sonographer. No evaluation can be communicated regarding pathology that was not visible in the image/video clips provided.

Thank you for this referral. If the clinical or image interpretation does not parallel your findings or if I can be of any further assistance please contact me.

R. McKenzie Daniel, DVM, DABVP (Canine / Feline Practice)
info@SonoPath.com