

PATIENT

Mochi Lancy

SPECIES

Feline

BREED

DSH

SEX

Female Spayed

AGE

8y

WEIGHT

9 lbs

INTERPRETED BY

R. McKenzie Daniel,
 DVM, DABVP
 (Canine and Feline)

IMAGING PERFORMED BY

Sara Hansen

HOSPITAL NAME

Cascade AC

REFERRING VET

Dr. Maczygemba

INVOICE

13224

DATE

2/24/26

PRESENTING CLINICAL SIGNS

History:

- VOMITING every few days, right after eating, undigested kibble followed by bile with blood tinge.
- Gastroenteritis suspected- has been occurring since new younger cat moved in. They do not get along.
- ABNORMAL Lab work Values
- Bloodwork came back within normal limits on 1/30/26
- Current Medications: Cerenia 16mg (1/2 tab once daily as needed for vomiting)

ULTRASONOGRAPHIC EXAMINATION OF THE ABDOMEN

Urinary System

The urinary bladder, trigone, cystourethral junction, and visible pelvic urethra to a depth of 2.0 cm exhibited normal thickness and tone. Primarily anechoic urine was present in the lumen. Minor, echogenic to particulate non-dependent sediment was present without evidence of calculus formation. The ureteral papillae were normal. The ureters were not visible which is normal. No evidence of inflammatory or neoplastic mural changes were noted.

Normal size and margination was present in the kidneys. A normal 1:3 cortex / medulla ratio and normal corticomedullary definition were maintained. The echogenicity of the cortex was similar to or slightly less than normal liver parenchyma while the medulla echogenicity was hypoechoic to the cortex with no evidence of pelvic dilation. The right kidney measured 4.5 cm in length. The left kidney was subnormal in size with capsule asymmetry and non-homogeneous, variably echogenic to focally hyperechoic cortex. Subjective cortical infarcts noted. The left kidney measured 3.0 cm in length.

Adrenal Glands

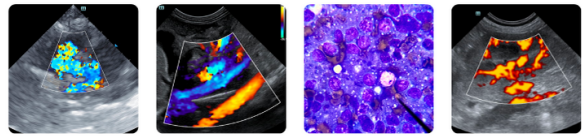
The left adrenal gland was uniform in size and contour with a uniformly hypoechoic parenchyma. The left adrenal gland measured 0.48 cm. No obvious pathology in the area of the right adrenal gland.

Spleen

The spleen exhibited a finely textured and homogenous parenchyma which was hyperechoic to the liver and renal cortical parenchyma. The capsule was smooth and regular without apparent expansion. The splenic vasculature at the hilus was normal in volume with no evidence of congestion or thrombosis. Acute to chronic inflammatory, neoplastic, or benign parenchyma changes were not noted.

Liver

The liver was subjectively normal in size, structure, and contour. The liver parenchyma was uniform and hypoechoic to the spleen with a mild coarse echotexture. The hepatic and portal vasculature were normal in appearance without signs of congestion. The gallbladder was non distended in size with mild, echogenic, nonmineralized biliary sludge. The cystic duct and common bile ducts were normal without evidence of dilation.



PATIENT

Mochi Lancy

SPECIES

Feline

BREED

DSH

SEX

Female Spayed

AGE

8y

WEIGHT

9 lbs

INTERPRETED BY

R. McKenzie Daniel,
DVM, DABVP
(Canine and Feline)

IMAGING PERFORMED BY

Sara Hansen

HOSPITAL NAME

Cascade AC

REFERRING VET

Dr. Maczygemba

INVOICE

13224

DATE

2/24/26

Gastrointestinal

The stomach presented intact wall layering with a normal wall layer ratio. The lumen of the stomach contained mild retained anechoic to mildly echogenic fluid. No evidence of shadowing content or obstruction to pyloric outflow.

The small intestine presented intact wall layering with 1:3 muscularis/mucosa ratio. The lumen of the small intestine was empty with no signs of ileus, obstruction or foreign material. Duodenum wall measured 0.23 cm and jejunum wall measured 0.21 cm.

Normal visible colon wall layers were present with apparent formed feces in lumen.

Pancreas

The parenchyma of the left limb, body and right limb of the pancreas presented isoechoic to the adjacent omental fat. A normal curvilinear capsule contour of the pancreas was present. The visible pancreatic duct was normal. No signs of active inflammation or neoplastic disease was evident.

Free Abdomen

No overt lymphadenopathy or peritoneal effusion was present.

ULTRASONOGRAPHIC FINDINGS

- Sonographically normal gastrointestinal tract with mild, non-obstructive hypomotile stomach
- Normal area of pancreas
- Left kidney subnormal size exhibiting chronic renal changes and cortical infarcts, sonographically normal right kidney
- Mild gallbladder debris (non-mucocele)

INTERPRETATION OF THE FINDINGS & FURTHER RECOMMENDATIONS

No evidence of significant gastrointestinal mural pathology. The stomach is most suggestive of mild hypomotile gastritis criteria. A spec fPL could be considered to assess for non-obvious pancreatitis which may present sonographically normal. Gastrointestinal support which may include dietary therapy and as needed gastro protectants should prove beneficial. Sonographic reassessment or monitoring indicated if persistent or progressive vomiting. Urinalysis recommended if not recently done. Assessment of systemic BP and coagulation profile given left kidney cortical infarcts may be considered.



PATIENT

Mochi Lancy

SPECIES

Feline

BREED

DSH

SEX

Female Spayed

AGE

8y

WEIGHT

9 lbs

INTERPRETED BY

R. McKenzie Daniel,
 DVM, DABVP
 (Canine and Feline)

IMAGING PERFORMED BY

Sara Hansen

HOSPITAL NAME

Cascade AC

REFERRING VET

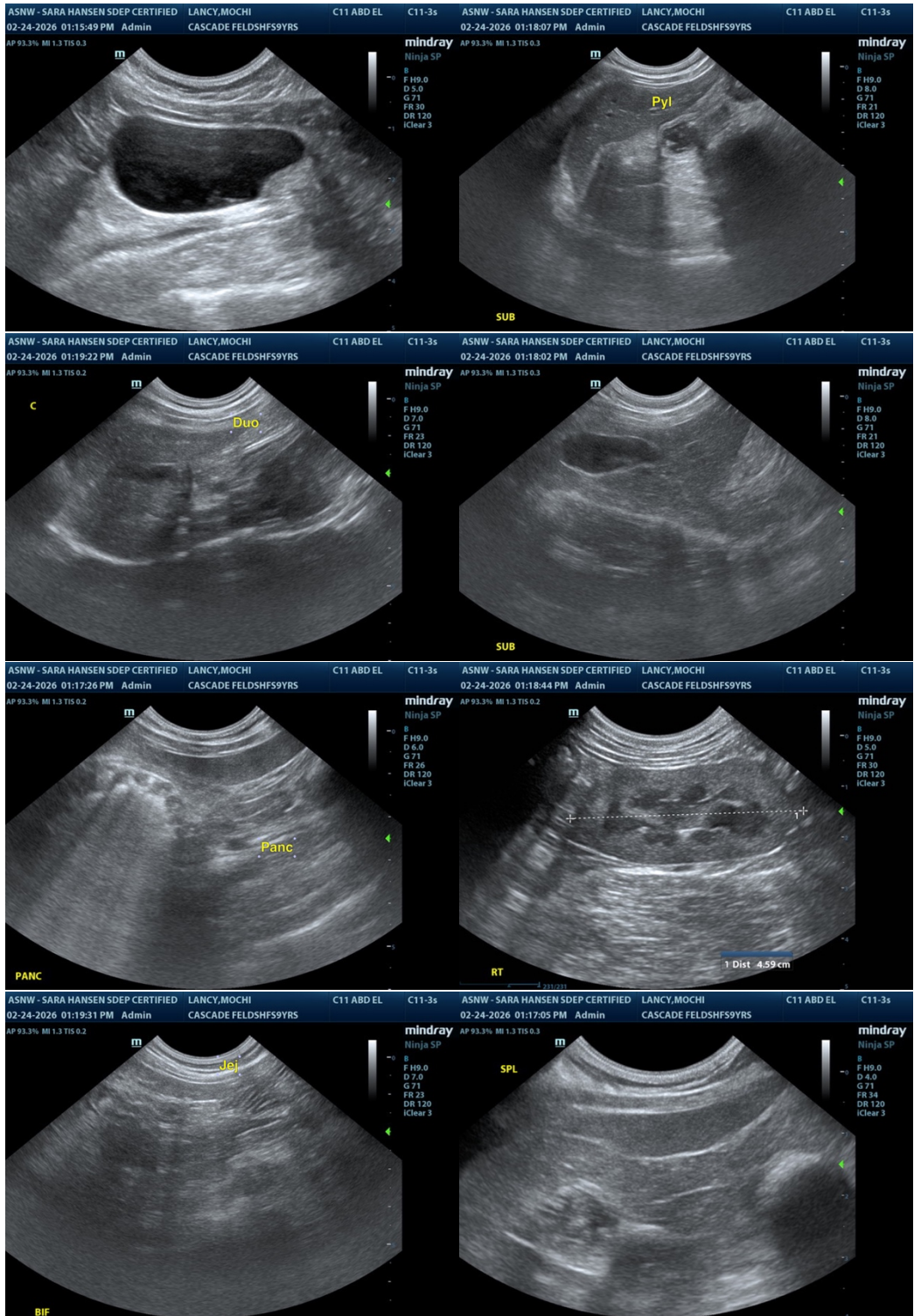
Dr. Maczygamba

INVOICE

13224

DATE

2/24/26





PATIENT

Mochi Lancy

SPECIES

Feline

BREED

DSH

SEX

Female Spayed

AGE

8y

WEIGHT

9 lbs

INTERPRETED BY

R. McKenzie Daniel,
DVM, DABVP
(Canine and Feline)

IMAGING PERFORMED BY

Sara Hansen

HOSPITAL NAME

Cascade AC

REFERRING VET

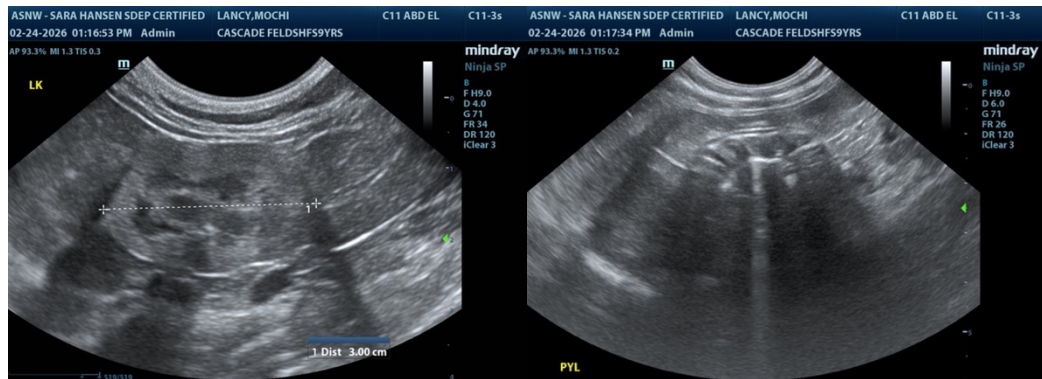
Dr. Maczygemba

INVOICE

13224

DATE

2/24/26



The information and recommendations provided are based on the images presented by the referring veterinarian/sonographer. No evaluation can be communicated regarding pathology that was not visible in the image/video clips provided.

Thank you for this referral. If the clinical or image interpretation does not parallel your findings or if I can be of any further assistance, please contact me.

R. McKenzie Daniel, DVM, DABVP (Canine / Feline Practice)

info@SonoPath.com