



PATIENT

Tundra SPCA

SPECIES

Canine

BREED

Lab X

SEX

Female

AGE

20 Weeks

WEIGHT

9 kg

INTERPRETED BY

R. McKenzie Daniel,
DVM, DABVP
(Canine and Feline)

**IMAGING
PERFORMED BY**

Donna Markland, DVM

HOSPITAL NAME

Island Mobile Paws VS

REFERRING VET

Island AH

INVOICE

21239

DATE

2/22/23

PRESENTING CLINICAL SIGNS

History: Tundra has one littermate with a confirmed ectopic ureter and another with a suspected one. Tundra drinks a lot of water and has been leaking urine. She is not responding to treatment for an E.Coli UTI in spite of appropriate antibiotic therapy based on a culture and sensitivity (cystocentesis sample).

Abnormal PE/Chem/CBC/UA Results: February 4, 2023 E.Coli UTI usg=1.016 Bloodwork from today is pending.

LIMITED ULTRASONOGRAPHIC EXAMINATION

The urinary bladder was normal in size and tone. Mild to moderate nondependent particulate sediment was present, which may indicate cellular debris/protein, crystalline debris, or mucus. No evidence of macrocalculi was noted. Subjective borderline prominent generalized urinary bladder walls were present, exhibiting normal mural echogenicity. A small to indistinct tubular structure was present, appearing to bypass the level of the trigone and urinary bladder neck, extending into the area of the proximal urethra. The tubular structure measured approximately 0.8 cm – 1.0 mm.

Both kidneys were overtly normal in size with subtle asymmetrical renal margination. Indistinct corticomedullary border demarcation was noted with maintained 1:3 cortex to medulla ratio. Mild left kidney pyelectasia was noted. The left kidney measured 6.7 cm. The right kidney measured 6.5 cm.

ULTRASONOGRAPHIC FINDINGS

- Urinary bladder sediment with suspect mild cystitis
- Suspect small tubular structure appearing to bypass the level of the ureteral papilla and urinary bladder neck into the area of the proximal urethra- strongly suggestive of ectopic ureter
- Subjective mild dystrophic renal changes with mild left kidney pyelectasia

INTERPRETATION OF THE FINDINGS & FURTHER RECOMMENDATIONS

Suspect small left ectopic ureter in conjunction with mild left kidney pyelectasia. Continued UTI protocol is recommended. Ideally, further assessment may include cystoscopy or gold standard CT with contrast for definitive diagnosis and/or surgical planning.



PATIENT

Tundra SPCA

SPECIES

Canine

BREED

Lab X

SEX

Female

AGE

20 Weeks

WEIGHT

9 kg

INTERPRETED BY

R. McKenzie Daniel,
DVM, DABVP
(Canine and Feline)

**IMAGING
PERFORMED BY**

Donna Markland, DVM

HOSPITAL NAME

Island Mobile Paws VS

REFERRING VET

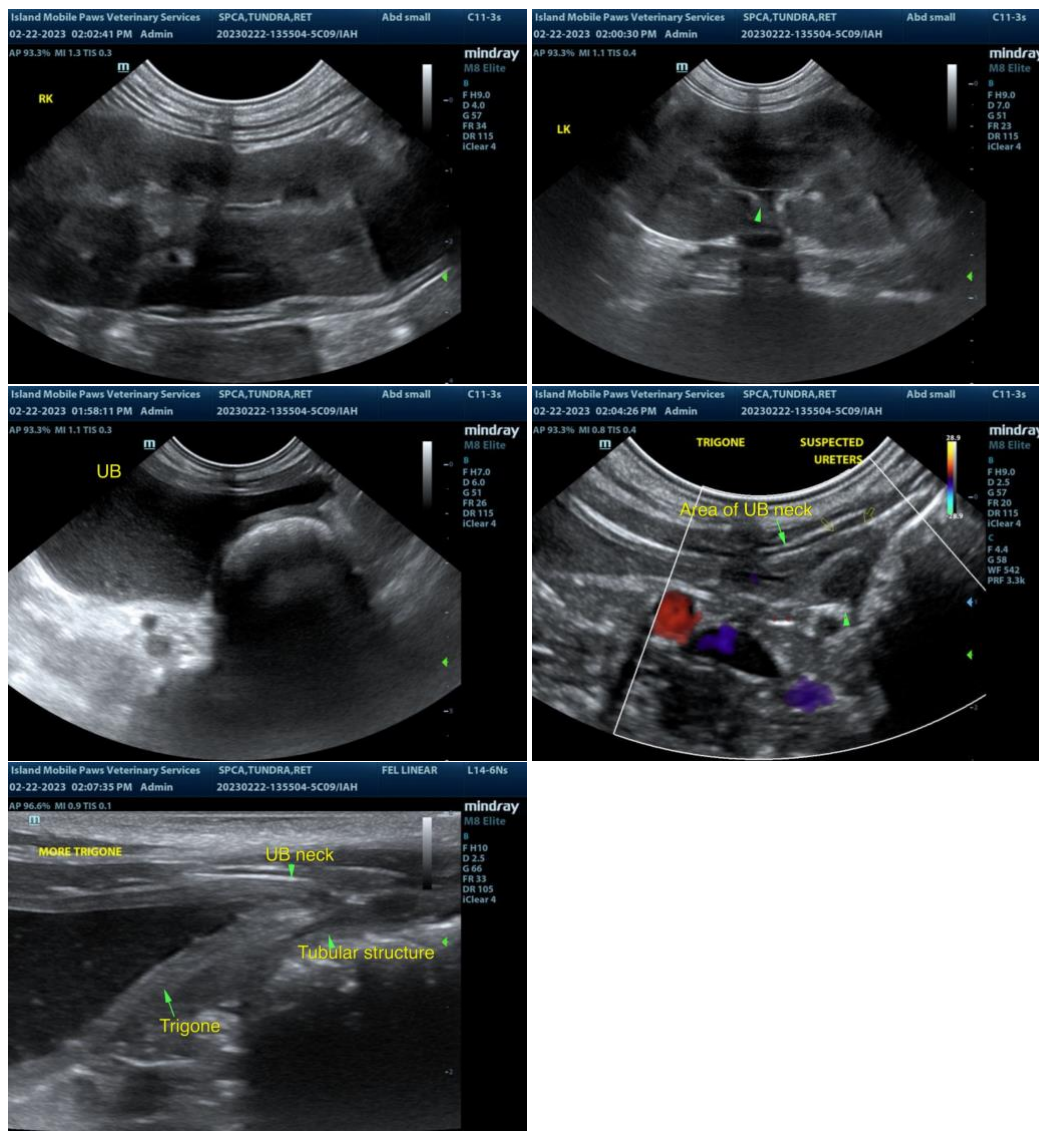
Island AH

INVOICE

21239

DATE

2/22/23



The information and recommendations provided are based on the images presented by the referring veterinarian. No evaluation can be communicated regarding pathology that was not visible in the image/video clips provided.

Thank you for this referral. If the clinical or image interpretation does not parallel your findings or if I can be of any further assistance please contact me.

R. McKenzie Daniel, DVM, DABVP (Canine / Feline Practice)
info@SonoPath.com