



PATIENT

Cleo Heckert

SPECIES

Feline

BREED

DLH

SEX

FS

AGE

7

WEIGHT

10

INTERPRETED BY

R. McKenzie Daniel,
DVM, DABVP
(Canine and Feline)

IMAGING PERFORMED BY

Tasha

HOSPITAL NAME

Dillsburg VC

REFERRING VET

Dr. Crow

INVOICE

16301

DATE

2/23/23

PRESENTING CLINICAL SIGNS

3/6 murmur; pre-op for dental procedure

ULTRASONOGRAPHIC EXAMINATION OF THE HEART

FELINE CARDIAC PARAMETERS	BODY WEIGHT (kg)	HR (BPM)	IVSd (cm)	LVIDd (cm)	LVWd (cm)	FS (%)	EF (%)
NORMAL PARAMETER	-----	150-240	0.3-0.6	1.0-2.1	0.25-0.6	35-67	80-100
PATIENT		NM	0.47	1.3	0.42	50	85
FELINE CARDIAC PARAMETERS	LA/AO (Boon)	LA/AO HEART BASE (Sisson)	LA 2D 4-chamber long axis AS to FW (Sisson) (cm)	LVOT VEL. (m/s)	RVOT VEL. (m/s)	IVRT (m/)	
NORMAL PARAMETER	<1.5	0.88-1.79	0.7-1.7	<1.6	<1.3	40-60	
PATIENT		1.4	1.2	NM	NM	NM	
Adapted from June Boon, Veterinary Echocardiography, 1998 Sisson D et al. JVIM 1991; 5: 232, Jacobs et al. Am J Vet Res 1985; 46:1705							

Cardiac Presentation

The echocardiogram in this patient demonstrated normal **left atrial** size based on 3 separate LA measurements. The cranial and caudal **mitral** valve leaflets presented normal linear structure and kinetics. The **left ventricle** presented normal thicknesses with linear contour and was not dilated nor restricted. The **myocardium** presented normal echogenicity without subjective evidence of significant fibrotic or ischemic disease. **Contractility** of the ventricular walls was adequate and in normal range for this patient evidenced by the fractional shortening measurement and subjective evaluation of the different regions and angles of the myocardium. The **left ventricular outflow** tract demonstrated normal laminar flow and subjective structural integrity. The **right atrium** and auricle revealed normal size, structure and content. No evidence of masses was noted or chamber overload. **Tricuspid** valvular assessment demonstrated adequate linear morphology and kinetics. The **right ventricle** was of normal size (1/3 diameter of LV), chordae structure, myocardial echogenicity and thickness. **Pulmonic** tract assessment revealed normal valve structure, laminar flow, and diameter (approx. 1:1 pa/ao ratio). No visible **pericardial** or free pleura fluid was noted or extra cardiac pathology in the visible planes. The cranial **mediastinum and pericardial regions** were free of masses in the visible window. No overt arrhythmia was noted.

ULTRASONOGRAPHIC FINDINGS

- Overtly normal cardiac structure and function



PATIENT

Cleo Heckert

SPECIES

Feline

BREED

DLH

SEX

FS

AGE

7

WEIGHT

10

INTERPRETED BY

R. McKenzie Daniel,
DVM, DABVP
(Canine and Feline)

IMAGING PERFORMED BY

Tasha

HOSPITAL NAME

Dillsburg VC

REFERRING VET

Dr. Crow

INVOICE

16301

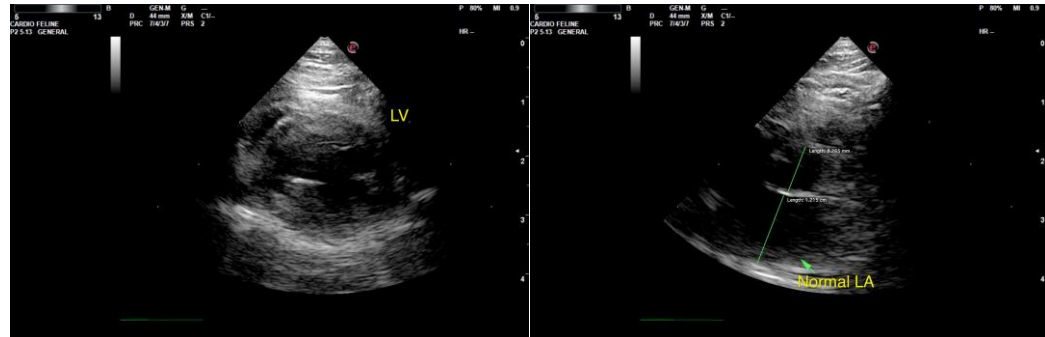
DATE

2/23/23

INTERPRETATION OF THE FINDINGS & FURTHER RECOMMENDATIONS

A definitive cause of the murmur was not obvious. Assuming no evidence of volume changes or dehydration, considerations may include benign flow murmur, although the possibility of a non-visualized valvular insufficiency, stenotic disease, or small shunt cannot be definitively excluded. Given the lack of left or right heart chamber enlargement, the hemodynamic effects of the murmur appear to be minimal to low. No overt indication for cardiac medications. No obvious anesthetic contraindications, assuming the patient is nonclinical with normal systemic BP and T4 levels. The following anesthetic protocol may be considered. Recheck echocardiogram is recommended in 6-12 months, sooner if murmur intensity increases or if clinical signs consistent with heart disease arise.

Suggested anesthetic protocol may include opioid or Benzodiazepine pre-med, induction with Propofol or Alfaxalone, and appropriate gas anesthesia with avoidance of alpha 2 agonists.



The information and recommendations provided are based on the images presented by the referring veterinarian/sonographer. No evaluation can be communicated regarding pathology that was not visible in the image/video clips provided.

Thank you for this referral. If the clinical or image interpretation does not parallel your findings or if I can be of any further assistance please contact me.

R. McKenzie Daniel, DVM, DABVP (Canine / Feline Practice)
info@SonoPath.com