


PATIENT PRESENTING CLINICAL SIGNS

Tessa Laffoley History: elevated liver enzymes on routine BW

SPECIES ULTRASONOGRAPHIC EXAMINATION OF THE ABDOMEN
Canine Urinary System

Canine

The urinary bladder, trigone, cystourethral junction, and visible pelvic urethra to a depth of 3.0 cm exhibited normal thickness and tone. Anechoic urine was present in the lumen with no uroliths, sediment, or calculi. The ureteral papillae were normal. The ureters were not visible which is normal. No evidence of inflammatory or neoplastic changes was noted.

BREED

Cairn Terrier

The area of the aortic trifurcation was free of pathology.

SEX

Spayed Female

Normal size and margination were present in the kidneys. A normal 1:3 cortex / medulla ratio was maintained. The medulla and cortices were uniform in texture with some increased echogenicity and mild loss of corticomedullary symmetry and definition expected for the age of the patient. No evidence of pelvic dilation was present. The left kidney measured 4.1 cm in length. The right kidney measured 4.6 cm in length.

AGE

12 Years

Adrenal Glands
WEIGHT

18 Lbs.

The bilateral adrenal glands were normal in size. Mild parenchyma heterogeneity and mild capsule asymmetry was present without suspicion for overt neoplasia. The left adrenal gland measured 1.7 cm length x 0.38 cm width in the caudal pole. The right adrenal gland measured 2.1 cm length x 0.54 cm width in the caudal pole.

INTERPRETED BY
Spleen

R. McKenzie Daniel, DVM,
 DABVP (Canine and
 Feline)

The spleen exhibited primarily finely textured parenchyma which was hyperechoic to the liver and renal cortical parenchyma. Mild generalized parenchyma heterogeneity was present without evidence of nodular changes. The capsule was smooth and regular without apparent expansion. The splenic vasculature at the hilus was normal in volume with no evidence of congestion or thrombosis. The parenchymal heterogeneity is likely consistent with benign changes such as extramedullary hematopoiesis or age-related remodeling with minor potential for inflammatory or neoplastic disease.

IMAGING
PERFORMED BY

Kelly Reschny

Liver/ Gallbladder
HOSPITAL NAME

Maples AH

The liver exhibited mild generalized enlargement and moderate generalized parenchymal remodeling exhibiting moderate coarse echotexture. Intermittent variably echogenic intraparenchymal nodules were present. An example of a discreetly hypoechoic nodule measured 1.5 cm in diameter in the midventral parenchyma. Subjective areas of ventral lobar swelling and asymmetrical hepatic contour were present with the midventral area of lobar swelling measuring approximately 6.5 cm in diameter subjectively extending to the level of and potentially caudal to the gastric axis. The gallbladder was non-distended in size with thin walls and primarily anechoic luminal content. The cystic and common bile ducts were normal.

REFERRING VET

Kazienko

INVOICE

13382

Gastrointestinal
DATE

2/22/22

The stomach presented intact wall layering with a normal wall layer ratio. Minor retained nonshadowing ingesta /chyme was present.



PATIENT

Tessa Laffoley

The small intestine presented intact wall layering with 1:3 muscularis/mucosa ratio. The lumen of the small intestine was empty with no signs of ileus, obstruction, or foreign material.

Normal visible colon wall layers were present with apparent formed feces in lumen.

SPECIES

Canine

Pancreas

The parenchyma of the left limb, body, and right limb of the pancreas presented isoechoic to the adjacent omental fat. A normal curvilinear capsule contour of the pancreas was present. The visible pancreatic duct was normal. No signs of active inflammation or neoplastic disease were evident.

BREED

Cairn Terrier

Free Abdomen

No overt lymphadenopathy or peritoneal effusion was present.

SEX

Spayed Female

ULTRASONOGRAPHIC FINDINGS

Primary Findings

AGE

12 Years

- Hepatopathy exhibiting generalized remodeled to focally nodular parenchyma, subjective mid ventral lobar swelling to potential indistinct mass effect
- Mild chronic renal changes

WEIGHT

18 Lbs.

INTERPRETATION OF THE FINDINGS & FURTHER RECOMMENDATIONS

Considerations for the heterogeneous nodular to regionally irregular liver may include vacuolar hepatopathy, nodular hyperplasia, inflammatory / immune-mediated disease, early fibrosis, cirrhosis, focal areas of nodular to regenerative hyperplasia, hematopoiesis, lipogranulomas, neoplasia, or other hepatopathies.

INTERPRETED BY

R. McKenzie Daniel, DVM,
DABVP (Canine and
Feline)

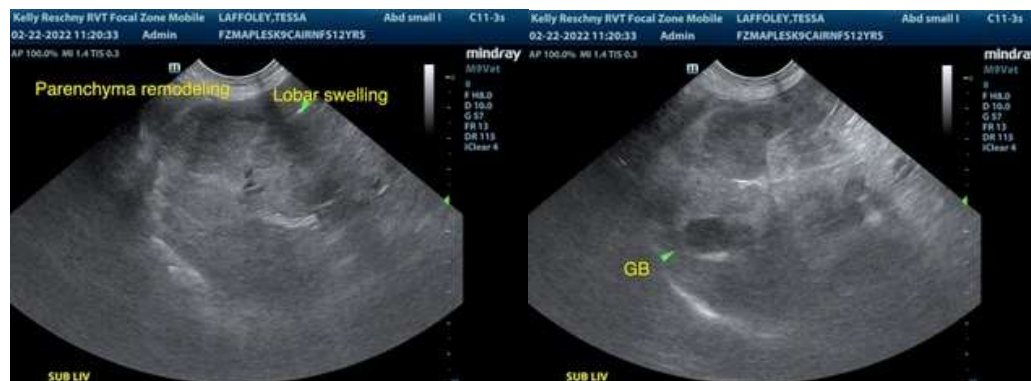Assuming normal clotting status, ultrasound guided FNA of the hepatic parenchyma specifically in the area of midventral lobar swelling to potential indistinct mass effect for screening cytology is warranted. Hepatosupportive medications including Denamarin and Ursodiol with recheck sonogram in 4 weeks to assess for progressive hepatic changes would be a more conservative approach.

IMAGING PERFORMED BY

Kelly Reschny

HOSPITAL NAME

Maples AH



REFERRING VET

Kazienko

INVOICE

13382

DATE

2/22/22



PATIENT

Tessa Laffoley

SPECIES

Canine

BREED

Cairn Terrier

SEX

Spayed Female

AGE

12 Years

WEIGHT

18 Lbs.

INTERPRETED BY

R. McKenzie Daniel, DVM,
DABVP (Canine and
Feline)

**IMAGING
PERFORMED BY**

Kelly Reschny

HOSPITAL NAME

Maples AH

REFERRING VET

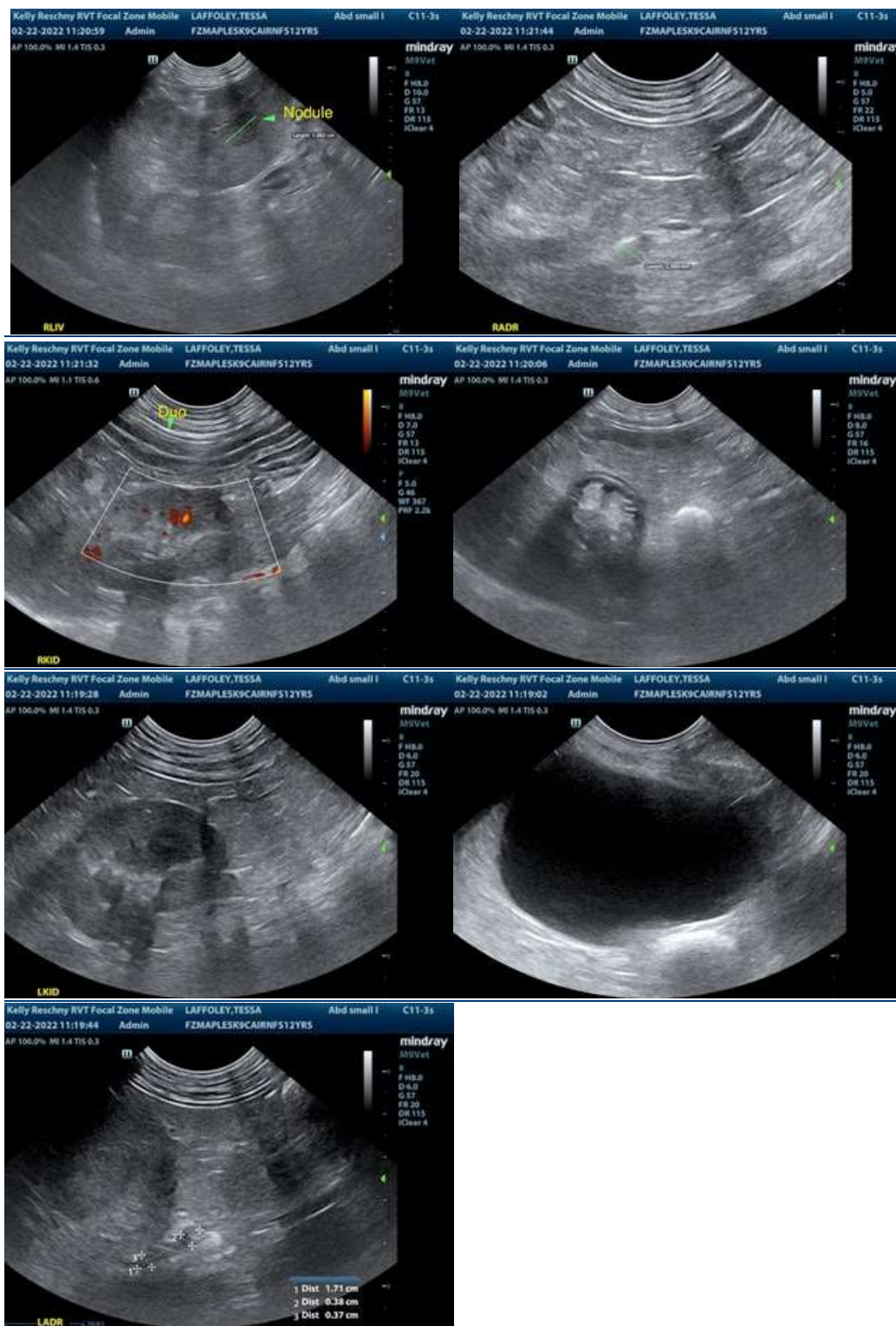
Kazienko

INVOICE

13382

DATE

2/22/22





PATIENT

Tessa Laffoley

The information and recommendations provided are based on the images presented by the referring veterinarian. No evaluation can be communicated regarding pathology that was not visible in the image/video clips provided.

SPECIES

Canine

Thank you for this referral. If the clinical or image interpretation does not parallel your findings or if I can be of any further assistance please contact me.

BREED

Cairn Terrier

R. McKenzie Daniel, DVM, DABVP (Canine / Feline Practice)
info@SonoPath.com

SEX

Spayed Female

AGE

12 Years

WEIGHT

18 Lbs.

INTERPRETED BY

R. McKenzie Daniel, DVM,
DABVP (Canine and
Feline)

**IMAGING
PERFORMED BY**

Kelly Reschny

HOSPITAL NAME

Maples AH

REFERRING VET

Kazienko

INVOICE

13382

DATE

2/22/22