



PATIENT	PRESENTING CLINICAL SIGNS
Phoebe Knutzen	Mass near liver/spleen (radiographs), non regen. anemia. No current meds. Abnormal PE/Chem/CBC/UA Results: Regen Anemia, BUN 4, Crea1.7, ALKP 182, Amyl 1355
SPECIES	ULTRASONOGRAPHIC EXAMINATION OF THE ABDOMEN
Canine	Urinary System
BREED	The urinary bladder, trigone, cystourethral junction, and visible pelvic urethra to a depth of 4.0 cm exhibited normal thickness and tone. Anechoic urine was present in the lumen with no uroliths or sediment. The ureteral papillae were normal. The ureters were not visible which is normal. No evidence of inflammatory or neoplastic changes were noted.
Lab X	
SEX	Normal size and margination were present in the kidneys. A normal 1:3 cortex / medulla ratio was maintained. The medulla and cortices were uniform in texture with some increased echogenicity and loss of corticomedullary symmetry and definition expected for the age of the patient. No evidence of pelvic dilation was present. The left kidney measured 6.5 cm. The right kidney measured 6.7 cm.
Spayed Female	
AGE	The area of the aortic trifurcation was free of pathology.
11 Years	Adrenal Glands
WEIGHT	The adrenal glands were not definitively visualized owing to patient size as well as regional perirenal omental artifact.
85 Pounds	Spleen
INTERPRETED BY	The spleen exhibited generalized enlargement with heterogeneous to hypoechoic, nodular parenchyma. Example of hypoechoic splenic nodule measured 2.2 cm diameter. A large, expansive, non-homogeneous to mixed echogenic mass subjectively in the area of and likely arising from the mid cranial spleen was present, measuring approximately 14 cm in diameter. The mass appeared to extend into the right cranial abdomen and was noted directly caudal to the right lateral to caudate liver. Associated perisplenic increased omental echogenicity noted.
R. McKenzie Daniel, DVM, DABVP (Canine and Feline)	
IMAGING PERFORMED BY	Liver
Jessica Miller	The liver was subjectively normal in size, structure, and contour. The liver parenchyma was mildly nonuniform and hypoechoic to the spleen with a moderate coarse echotexture and subjective mild to benign parenchymal remodeling. The hepatic and portal vasculature were normal in appearance without signs of congestion. The gallbladder was non-distended in size with thin walls and primarily anechoic luminal content. The cystic and common bile ducts were normal.
HOSPITAL NAME	Gastrointestinal
Brenda King Vet	The stomach presented intact wall layering with a normal wall layer ratio. The lumen of the stomach was empty with no signs of ileus, obstruction or foreign material.
REFERRING VET	The small intestine presented intact wall layering with 1:3 muscularis/mucosa ratio. The lumen of the small intestine was empty with no signs of ileus, obstruction or foreign material.
Dr. King	
INVOICE	Normal visible colon wall layers were present with apparent formed feces in lumen.
35782	
DATE	
2/22/22	



PATIENT

Pancreas

Phoebe Knutzen

The pancreas was not definitively visualized owing to increased peripancreatic omental echogenicity. Overt pathology associated with the pancreas was not definitively evident. No overt lymphadenopathy.

SPECIES

Free Abdomen

Canine

Moderate volume free fluid was present exhibiting mild cellular component.

Rapid view of the heart revealed no evidence of pericardial masses or effusion in the visible window.

BREED

ULTRASONOGRAPHIC FINDINGS

Lab X

- Infiltrative spleen with probable large to expansive non-homogeneous mass
- Concurrent moderate volume free fluid – probable hemoabdomen
- Associated perisplenic reactive mesentery – potential for adhesions possible
- Hepatic parenchymal remodeling
- Mild age related kidneys

AGE

INTERPRETATION OF THE FINDINGS & FURTHER RECOMMENDATIONS

11 Years

The generalized spleen and probable expansive cranial splenic mass are consistent with neoplastic criteria with considerations including sarcoma, round cell neoplasia, or other. Potential for benign etiologies, yet thought less likely. Overt sonographic evidence of major organ metastasis was not definitively evident, yet potential for regional perisplenic omental seeding or non-sonographically evident metastasis/micrometastasis to adjacent organs or to the heart cannot be definitively excluded.

WEIGHT

85 Pounds

If no evidence of thoracic pathology/metastasis on 3-view chest radiographs, exploratory laparotomy with expectation towards splenectomy, gross inspection of the perisplenic omentum and liver could be considered. However, very guarded to potentially unfavorable long-term prognosis, given the potential for aggressive neoplasia (i.e., hemangiosarcoma) is indicated.

INTERPRETED BY

R. McKenzie Daniel,
DVM, DABVP
(Canine and Feline)

IMAGING PERFORMED BY

Jessica Miller

HOSPITAL NAME

Brenda King Vet

REFERRING VET

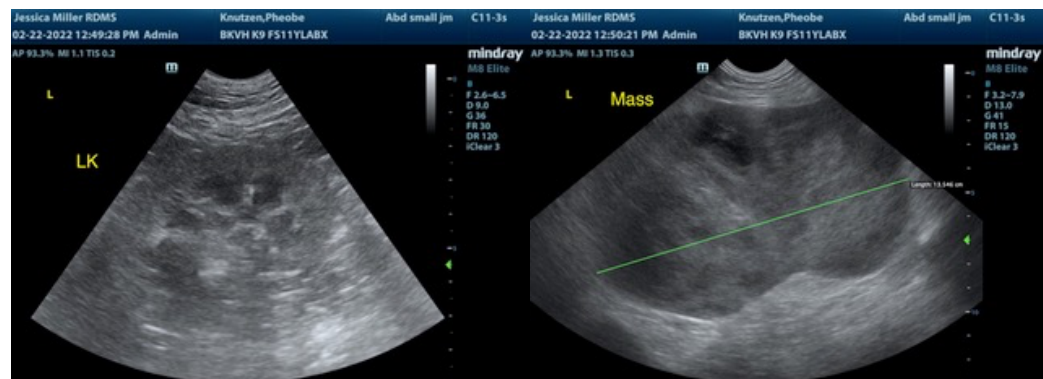
Dr. King

INVOICE

35782

DATE

2/22/22





PATIENT

Phoebe Knutzen

SPECIES

Canine

BREED

Lab X

SEX

Spayed Female

AGE

11 Years

WEIGHT

85 Pounds

INTERPRETED BY

R. McKenzie Daniel,
DVM, DABVP
(Canine and Feline)

IMAGING PERFORMED BY

Jessica Miller

HOSPITAL NAME

Brenda King Vet

REFERRING VET

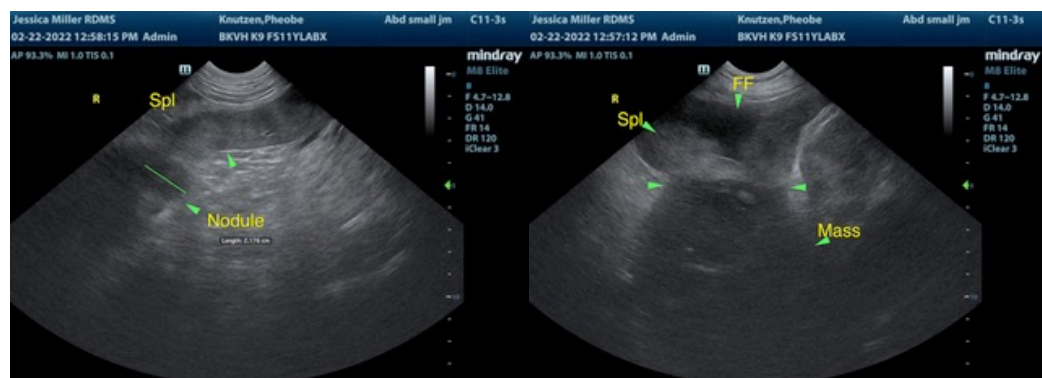
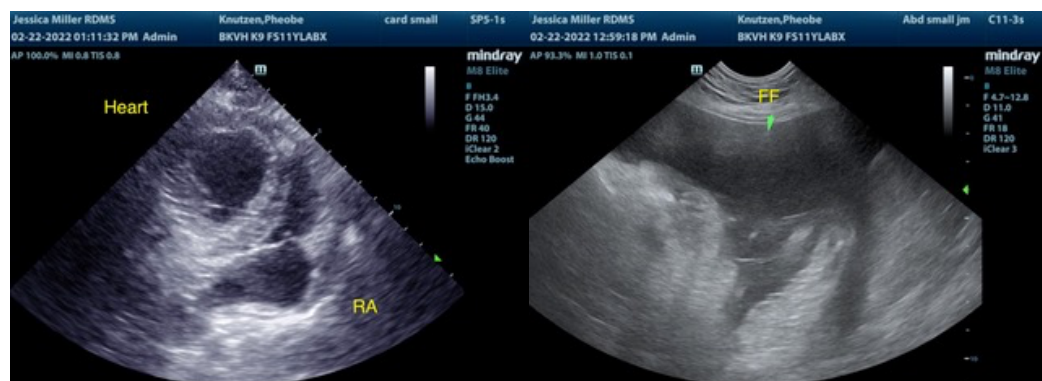
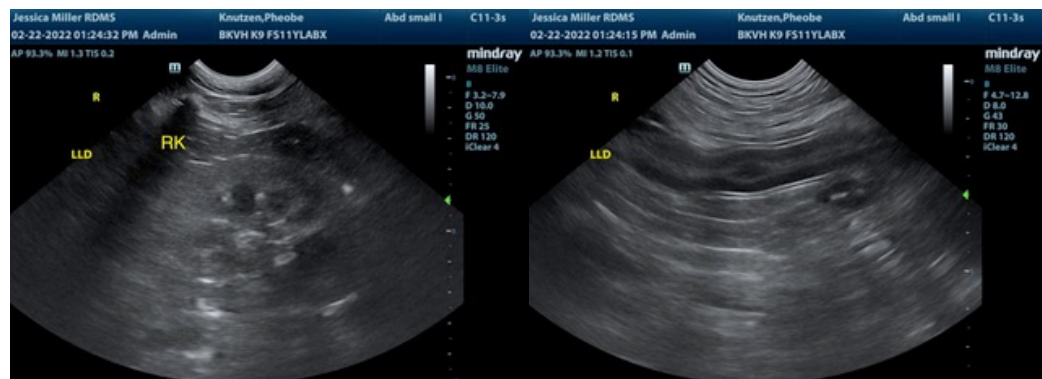
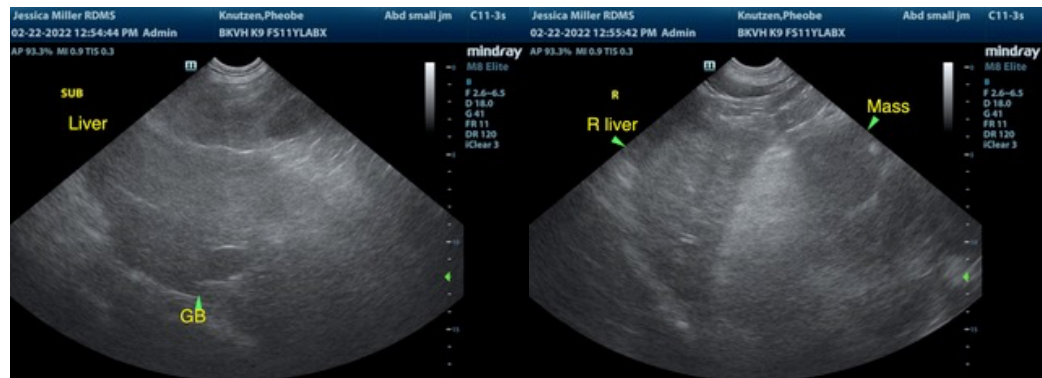
Dr. King

INVOICE

35782

DATE

2/22/22





PATIENT

Phoebe Knutzen

The information and recommendations provided are based on the images presented by the referring veterinarian/sonographer. No evaluation can be communicated regarding pathology that was not visible in the image/video clips provided.

SPECIES

Canine

Thank you for this referral. If the clinical or image interpretation does not parallel your findings or if I can be of any further assistance please contact me.

R. McKenzie Daniel, DVM, DABVP (Canine / Feline Practice)

BREED

Lab X

info@SonoPath.com

SEX

Spayed Female

AGE

11 Years

WEIGHT

85 Pounds

INTERPRETED BY

R. McKenzie Daniel,
DVM, DABVP
(Canine and Feline)

IMAGING PERFORMED BY

Jessica Miller

HOSPITAL NAME

Brenda King Vet

REFERRING VET

Dr. King

INVOICE

35782

DATE

2/22/22