



PATIENT PRESENTING CLINICAL SIGNS

Spunky Dittrich History: Cough, severe dental disease, mass noted on radiographs.

SPECIES ULTRASONOGRAPHIC EXAMINATION OF THE THORAX

Feline Overtly normal cardiac structure and function, without sonographic or subjective evidence of left or right heart chamber enlargement. Pericardial effusion and cardiac tumors were noted. Subjective normal LV function was present. A nonhomogenous, mildly irregular mass lesion was noted adjacent to the heart within the mid right to caudal thorax. The mass appeared to be adjacent to or directly efface the right diaphragm, without evidence of diaphragmatic compromise or invasion. The mass exhibited mild mixed echogenic to hypoechoic parenchyma with potential areas of minor air entrapment or possible emerging mineralization. Very scant pocket of regional pleural effusion was noted.

BREED

DSH

SEX

Neutered Male

ULTRASONOGRAPHIC FINDINGS

- Right mid to caudal pulmonary mass lesion
- Overtly normal cardiac structure and function
- Very scant regional pleural free fluid

AGE

2011

WEIGHT INTERPRETATION OF THE FINDINGS & FURTHER RECOMMENDATIONS

17.7 General considerations for the confirmed pulmonary mass lesion may include consolidation, inflammation/infection, granuloma, neoplasia, or other with neoplasia favored. If neoplastic process is confirmed, correlation with pending cytology and potential oncology consult is recommended.

INTERPRETED BY

R. McKenzie Daniel,
DVM, DABVP
(Canine and Feline)

IMAGING PERFORMED BY

Rebekah Jakum, CVT
ARDMS/RVT

HOSPITAL NAME

The Village
Veterinarian

REFERRING VET

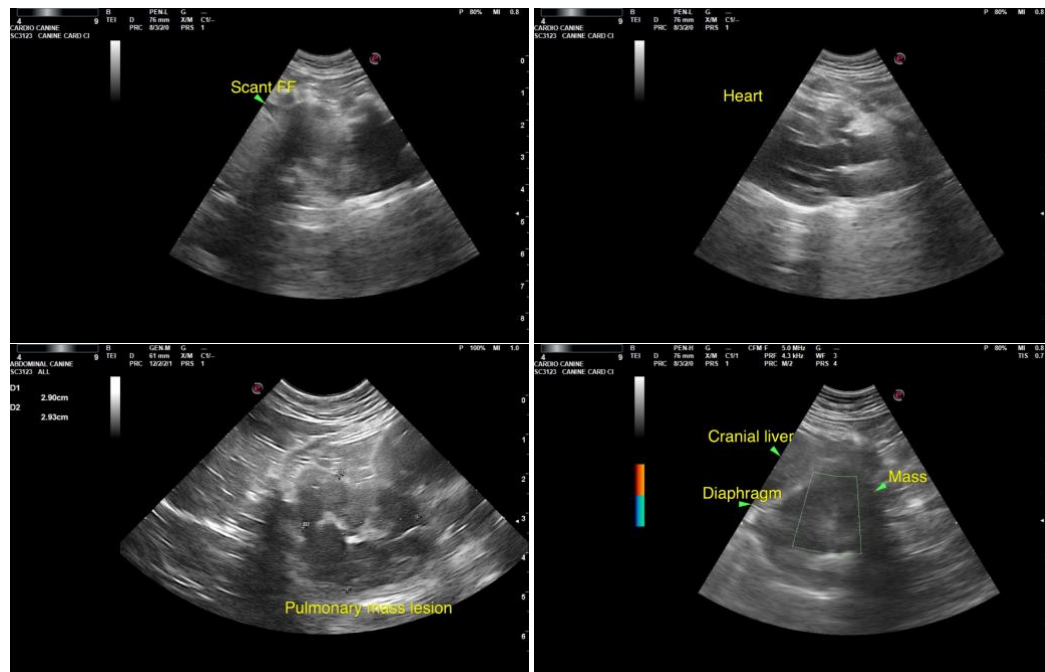
Dr. Longenecker

INVOICE

20926

DATE

2/2/23





PATIENT

Spunky Dittrich

The information and recommendations provided are based on the images presented by the referring veterinarian. No evaluation can be communicated regarding pathology that was not visible in the image/video clips provided.

SPECIES

Feline

Thank you for this referral. If the clinical or image interpretation does not parallel your findings or if I can be of any further assistance please contact me.

BREED

DSH

R. McKenzie Daniel, DVM, DABVP (Canine / Feline Practice)
info@SonoPath.com

SEX

Neutered Male

AGE

2011

WEIGHT

17.7

INTERPRETED BY

R. McKenzie Daniel,
DVM, DABVP
(Canine and Feline)

**IMAGING
PERFORMED BY**

Rebekah Jakum, CVT
ARDMS/RVT

HOSPITAL NAME

The Village
Veterinarian

REFERRING VET

Dr. Longenecker

INVOICE

20926

DATE

2/2/23