



PATIENT PRESENTING CLINICAL SIGNS

Vanilla Harria
History: Gradual weight loss, acute anorexia and lethargy
Medication: Vetprofen

SPECIES
Canine
HCT 36.3, WBC 15.7, BUN 5, Na/K ratio 33, Unremarkable liver enzymes

BREED ULTRASONOGRAPHIC EXAMINATION OF THE ABDOMEN

Pitbull **Urinary System**

SEX
FS
The urinary bladder presented uniformly thickened urinary bladder wall isoechoic to the adjacent normal urinary bladder wall. The luminal margin of the thickened urinary bladder wall was mildly asymmetrical in contour. The apical urinary bladder wall thickness measured 0.85 cm width. Mineralization or echogenic foci within the thickened areas of urinary bladder wall was not present. The urinary bladder, trigone, cystourethral junction, and visible pelvic urethra exhibited normal tone to a depth of 3.0 cm. Anechoic urine was present in the lumen with no uroliths or sediment. The ureteral papillae were normal. The ureters were not visible which is normal.

AGE
9 years
The area of the aortic trifurcation was free of pathology.

WEIGHT
84 Pounds
Normal size and margination were present in the kidneys. A normal 1:3 cortex / medulla ratio and normal corticomedullary definition were maintained. The echogenicity of the cortex was similar to or slightly less than normal liver parenchyma while the medulla echogenicity was hypoechoic to the cortex with no evidence of pelvic dilation. The left kidney measured 7.7 cm in length. The right kidney measured 8.6 cm in length.

INTERPRETED BY

R. McKenzie Daniel,
DVM, DABVP
(Canine and Feline)

Adrenal Glands

The left adrenal gland was uniform in size and contour with a uniformly hypoechoic parenchyma. The left adrenal gland measured 0.82 cm width at the caudal pole and 0.67 cm width at the cranial pole. The right adrenal gland was uniform in size and contour with a uniformly hypoechoic parenchyma. The right adrenal gland measured 0.68 cm width at the caudal pole and 0.59 cm width at the cranial pole.

IMAGING PERFORMED BY

Rebekah Jakum, CVT
ARDMS/RVT

HOSPITAL NAME

Little Gap AH

Spleen

The spleen exhibited a finely textured and homogenous parenchyma which was hyperechoic to the liver and renal cortical parenchyma. The capsule was smooth and regular without apparent expansion. The splenic vasculature at the hilus was normal in volume with no evidence of congestion or thrombosis. Acute to chronic inflammatory, neoplastic, or benign parenchyma changes were not noted.

REFERRING VET

Dr. Shelly

INVOICE Liver/ Gallbladder

13141
The liver exhibited subjective potential for mild subnormal size. The hepatic parenchyma revealed diffuse reduced echogenicity compared to the spleen and renal cortical parenchyma with a mild

DATE

2.2.2022



PATIENT

Vanilla Harria

coarse echotexture. Increased portal vein prominence was evident. The capsule of the liver was normal in margination. Distinct masses or nodules were not evident. The hepatic and portal vasculature were normal in appearance. The gallbladder was non-distended in size with primarily anechoic luminal content. The cystic and common bile ducts were normal.

SPECIES

Canine

Gastrointestinal

The stomach presented intact wall layering with a normal wall layer ratio. The lumen of the stomach contained moderate, retained, variably echogenic yet nonshadowing ingesta and chyme along with luminal gas. No overt evidence of mechanical pyloric outflow obstruction was noted. The pylorus wall width measured 0.58 cm.

BREED

Pitbull

The visualized segments of small intestine exhibited intact wall layering and subjective maintained a 1:3 muscularis/mucosa ratio. Segmental to generalized increased intestinal gas pattern was present without overt evidence of fluid dilation, mechanical obstruction, loss of intestinal wall layering, or overt small intestinal foreign material.

SEX

FS

Normal visible colon wall layers were present with apparent formed feces in lumen.

AGE

9 years

Pancreas

The parenchyma of the left limb, body, and right limb of the pancreas presented isoechoic to the adjacent omental fat. A normal curvilinear capsule contour of the pancreas was present. The visible pancreatic duct was normal. No signs of active inflammation or neoplastic disease were evident.

WEIGHT

84 Pounds

Free Abdomen

INTERPRETED BY

R. McKenzie Daniel,
DVM, DABVP
(Canine and Feline)

No overt lymphadenopathy or peritoneal effusion was present.

ULTRASONOGRAPHIC FINDINGS

Primary Findings

- Moderate retained gastric ingesta / chyme
- Overtly normal visualized small bowel with increased gas pattern
- Subjective mild subnormal liver size - nonspecific, potential patient variant given lack of elevated liver enzymes or significant parenchymal pathology
- Cystitis pattern

IMAGING PERFORMED BY

Rebekah Jakum, CVT
ARDMS/RVT

HOSPITAL NAME

Little Gap AH

REFERRING VET

Dr. Shelly

INTERPRETATION OF THE FINDINGS & FURTHER RECOMMENDATIONS

Overall, an obvious cause of the patient's weight loss was not definitively evident. The presence of moderate retained gastric ingesta may indicate post prandial presentation. However, given the reported anorexia in this patient, gastric stasis or delayed gastric emptying is suspected. This may be metabolic in nature potentially owing to nonspecific inflammatory gastrointestinal process or other structurally insignificant gastroenteropathy. The potential for nonobvious mechanical obstruction to

INVOICE

13141

DATE

2.2.2022



PATIENT

Vanilla Harria

gastric outflow is considered less likely, yet cannot be definitively excluded given gastric and overall gastrointestinal gas artifact.

SPECIES

Canine

Further assessment may include a GI panel to include PLI/TLI/Cobalamin/Folate to assess for occult pancreatic or gastrointestinal disease. Three view chest radiographs are suggested if not done to rule out occult thoracic pathology as a potential contributing factor to weight loss. Resting cortisol to screen for occult Addison's Disease may be considered.

BREED

Pitbull

Hospitalization with monitoring for gastric emptying and/or improvement in the overall gastrointestinal gas pattern would be appropriate. If persistent evidence of retained gastric ingesta, additional imaging or assessment of the upper gastrointestinal tract may be required. Urinalysis is suggested if not recently done to assess for evidence of inflammatory cells.

SEX

FS

AGE

9 years

WEIGHT

84 Pounds

INTERPRETED BY

R. McKenzie Daniel,
DVM, DABVP
(Canine and Feline)

IMAGING PERFORMED BY

Rebekah Jakum, CVT
ARDMS/RVT

HOSPITAL NAME

Little Gap AH

REFERRING VET

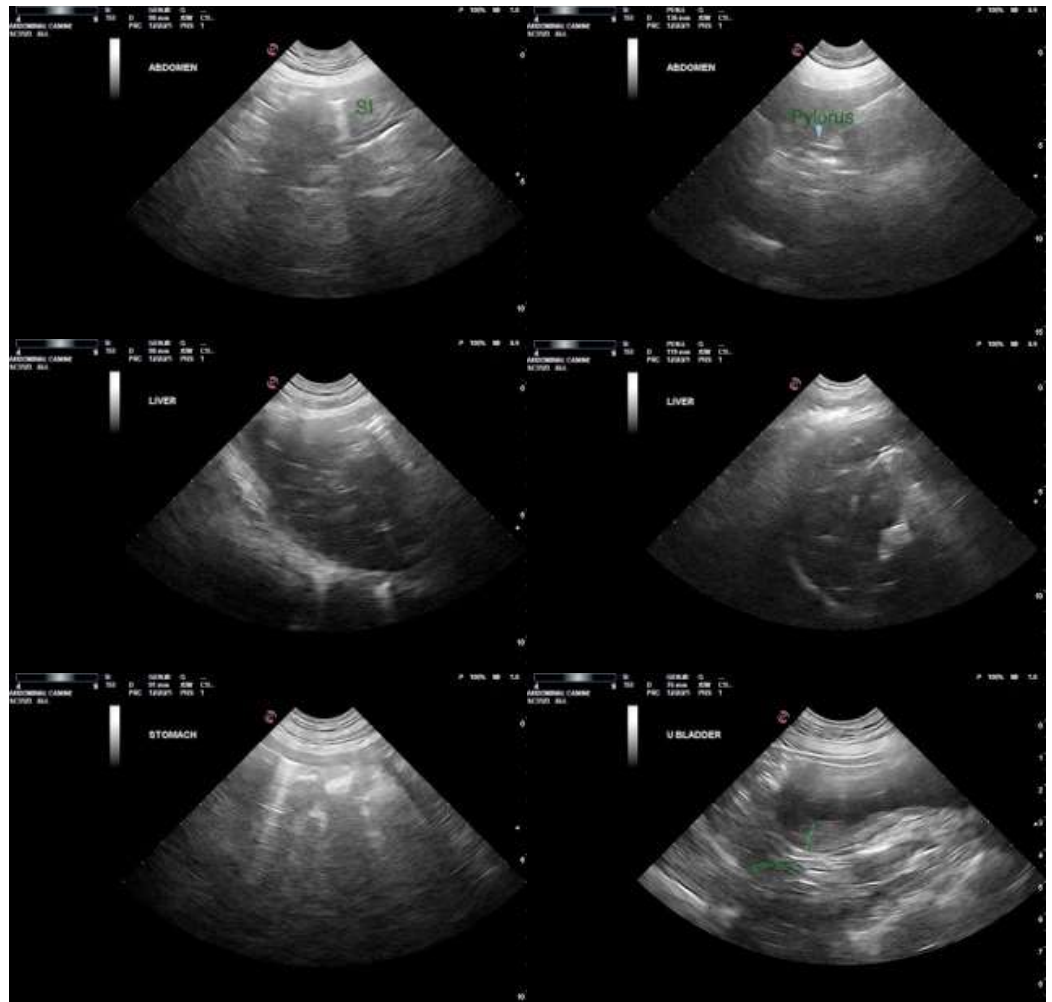
Dr. Shelly

INVOICE

13141

DATE

2.2.2022





PATIENT

Vanilla Harria

SPECIES

Canine

BREED

Pitbull

SEX

FS

AGE

9 years

WEIGHT

84 Pounds

INTERPRETED BY

R. McKenzie Daniel,
DVM, DABVP
(Canine and Feline)

**IMAGING
PERFORMED BY**

Rebekah Jakum, CVT
ARDMS/RVT

HOSPITAL NAME

Little Gap AH

REFERRING VET

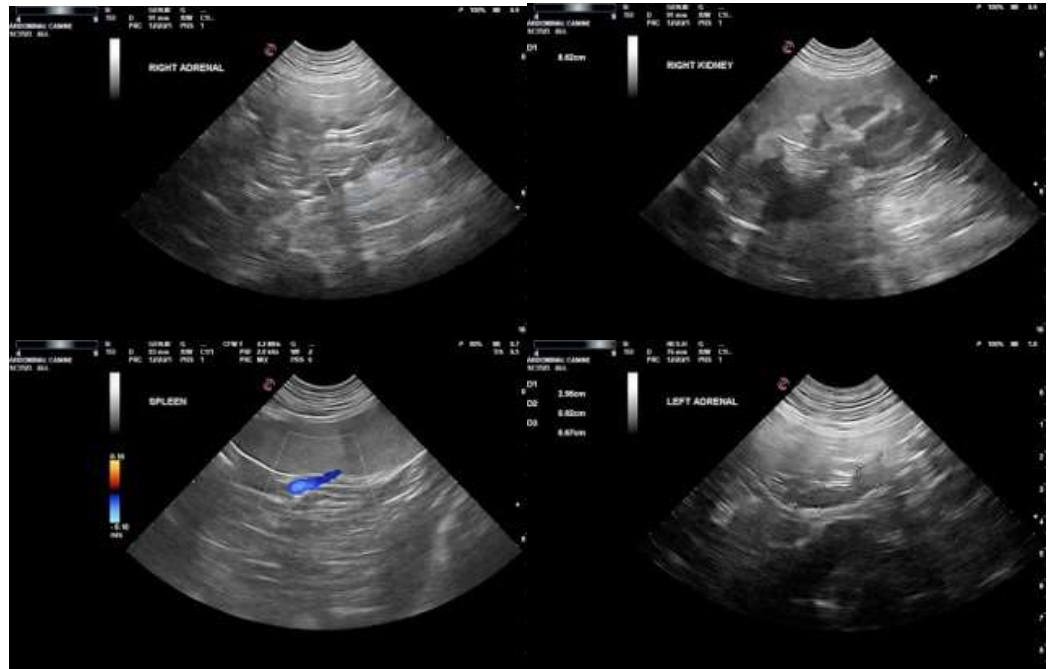
Dr. Shelly

INVOICE

13141

DATE

2.2.2022



The information and recommendations provided are based on the images presented by the referring veterinarian. No evaluation can be communicated regarding pathology that was not visible in the image/video clips provided.

Thank you for this referral. If the clinical or image interpretation does not parallel your findings or if I can be of any further assistance please contact me.

R. McKenzie Daniel, DVM, DABVP (Canine/Feline Practice)
mac.daniel@sonopath.com