



**PATIENT**

Shiro Krisanda

**PRESENTING CLINICAL SIGNS**

LARGE abdomen, "shadowing" on radiograph per RDVM

**SPECIES**

Canine

**ULTRASONOGRAPHIC EXAMINATION OF THE ABDOMEN**

The urinary bladder was of normal size and tone containing anechoic urine without evidence of sediment or calculi. No overt urinary bladder tumors.

**BREED**

Mix

The area of the iliac trifurcation was free of pathology including no evidence of medial, iliac or sublumbar lymphadenopathy.

**SEX**

Male

The visualized liver exhibited potential for mild hepatomegaly exhibiting symmetrical capsule contour and normal parenchyma echogenicity with a mild coarse echotexture.

The visualized segments of small intestine presented intact wall layering with 1:3 muscularis/mucosa ratio. The lumen of the small intestine contained mild segmental non-shadowing ingesta with no signs of ileus, obstruction or foreign material.

**AGE**

13yr

Significant volume peritoneal effusion exhibiting mild echogenic changes suggestive of mild fluid cellularity was present. No overt or visualized intra-abdominal masses or evidence of significant lymphadenopathy. Generalized mild uniform increased omental echogenicity was present.

**ULTRASONOGRAPHIC FINDINGS**

- Significant volume mildly echogenic peritoneal effusion

**WEIGHT**

117

**INTERPRETATION OF THE FINDINGS & FURTHER RECOMMENDATIONS**

A definitive cause of the peritoneal effusion was not obvious. The effusion may indicate non-septic (increased vascular permeability, decreased hydrostatic pressure), septic effusion, hemorrhage or neoplastic effusion i.e., carcinomatosis, lymphomatosis or similar.

Effusion analysis cytology +/- C/S if evidence of inflammatory cells as well as a full CBC/Chem/UA is recommended. Three view chest radiographs are recommended if not done to assess for occult thoracic pathology or cardiomegaly as a potential contributing factor. An extremely guarded prognosis indicated pending effusion analysis.

**INTERPRETED BY**

R. McKenzie Daniel,  
DVM, DABVP  
(Canine and Feline)

**IMAGING PERFORMED BY**

Hope Brossman

**HOSPITAL NAME**

Animal Mansion  
Veterinary Hospital

**REFERRING VET**

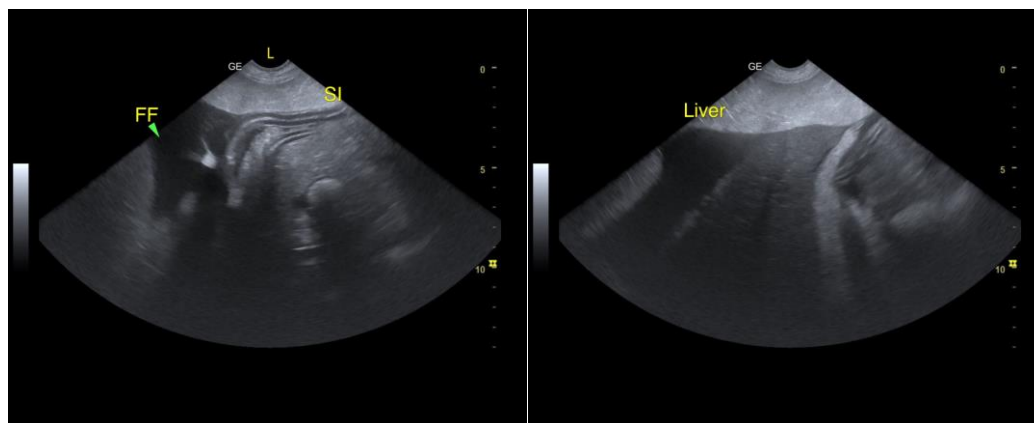
Dr. Parker

**INVOICE**

13015ag

**DATE**

02/19/2023





**PATIENT**

Shiro Krisanda

**SPECIES**

Canine

**BREED**

Mix

**SEX**

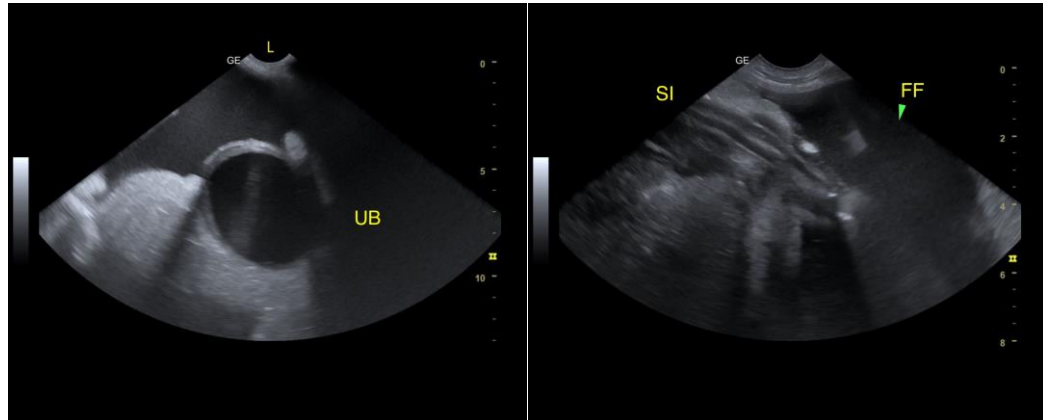
Male

**AGE**

13yr

**WEIGHT**

117



The information and recommendations provided are based on the images presented by the referring veterinarian/sonographer. No evaluation can be communicated regarding pathology that was not visible in the image/video clips provided.

Thank you for this referral. If the clinical or image interpretation does not parallel your findings or if I can be of any further assistance, please contact me.

R. McKenzie Daniel, DVM, DABVP (Canine/Feline Practice)  
[mac.daniel@sonopath.com](mailto:mac.daniel@sonopath.com)

**INTERPRETED BY**

R. McKenzie Daniel,  
DVM, DABVP  
(Canine and Feline)

**IMAGING PERFORMED BY**

Hope Brossman

**HOSPITAL NAME**

Animal Mansion  
Veterinary Hospital

**REFERRING VET**

Dr. Parker

**INVOICE**

13015ag

**DATE**

02/19/2023