



## PATIENT

Rudolf Slack

## SPECIES

Feline

## BREED

DLH

## SEX

Male Neutered

## AGE

8y

## WEIGHT

12.8 lbs

## INTERPRETED BY

R. McKenzie Daniel,  
DVM, DABVP  
(Canine and Feline)

## IMAGING PERFORMED BY

Rodriguez

## HOSPITAL NAME

Foxfield VS

## REFERRING VET

Rodriguez

## INVOICE

13219

## DATE

2/18/26

## PRESENTING CLINICAL SIGNS

History:

- 2/6 heart murmur. Echo prior to dental cleaning

Abnormal PE/Chem/CBC/UA Results: T4: 3.2, Free T4: 49.8. Otherwise WNI.

## ULTRASONOGRAPHIC EXAMINATION OF THE HEART

FELINE CARDIAC PARAMETERS	BODY WEIGHT (kg)	HR (BPM)	IVSd (cm)	LVIDd (cm)	LVWd (cm)	FS (%)	EF (%)
NORMAL PARAMETER	-----	150-240	0.3-0.6	1.0-2.1	0.25-0.6	35-67	80-100
PATIENT	--	NM	0.56	1.4	0.56	55	86
FELINE CARDIAC PARAMETERS	LA/AO (M-mode)	LA/AO HEART BASE (Sisson)	LAD LA MAX 4 Chamber		LVOT VEL. (m/s)	RVOT VEL. (m/s)	IVRT (m/)
NORMAL PARAMETER	<1.5	1.6	0.7-1.7		<1.6	<1.3	40-60
PATIENT	1.1	1.3	1.4		--	1.2	--
Adapted from June Boon, Veterinary Echocardiography, 1998							
Sisson D et al. JVIM 1991; 5: 232, Jacobs et al. Am J Vet Res 1985; 46:1705							

## Cardiac Presentation

The echocardiogram in this patient demonstrated normal **left atrial** size based on 3 separate LA measurements. The cranial and caudal **mitral** valve leaflets presented normal linear structure and kinetics. No overt significant MR noted on doppler. The **left ventricle** presented normal thicknesses with linear contour and was not dilated nor restricted. The **myocardium** presented normal echogenicity without subjective evidence of significant fibrotic or ischemic disease. **Contractility** of the ventricular walls was adequate and in normal range for this patient evidenced by the fractional shortening measurement and subjective evaluation of the different regions and angles of the myocardium. The **left ventricular outflow** tract demonstrated normal laminar flow and subjective structural integrity. The **right atrium** and auricle revealed normal size, structure and content. No evidence of masses was noted or chamber overload. **Tricuspid** valvular assessment demonstrated adequate linear morphology and kinetics. No overt significant TR noted on doppler. The **right ventricle** was of normal size (1/3 diameter of LV), chordae structure, myocardial echogenicity and thickness. **Pulmonic** tract assessment revealed normal valve structure, laminar flow, and diameter (approx. 1:1 pa/ao ratio). Normal measured RVOT velocity noted. No visible **pericardial** or free pleura fluid was noted or extra cardiac pathology in the visible planes. The cranial **mediastinum and pericardial regions** were free of masses in the visible window.

## ULTRASONOGRAPHIC FINDINGS

- Normal cardiac structure/function



## PATIENT

Rudolf Slack

## SPECIES

Feline

## BREED

DLH

## SEX

Male Neutered

## AGE

8y

## WEIGHT

12.8 lbs

## INTERPRETED BY

R. McKenzie Daniel,  
DVM, DABVP  
(Canine and Feline)

## IMAGING PERFORMED BY

Rodriguez

## HOSPITAL NAME

Foxfield VS

## REFERRING VET

Rodriguez

## INVOICE

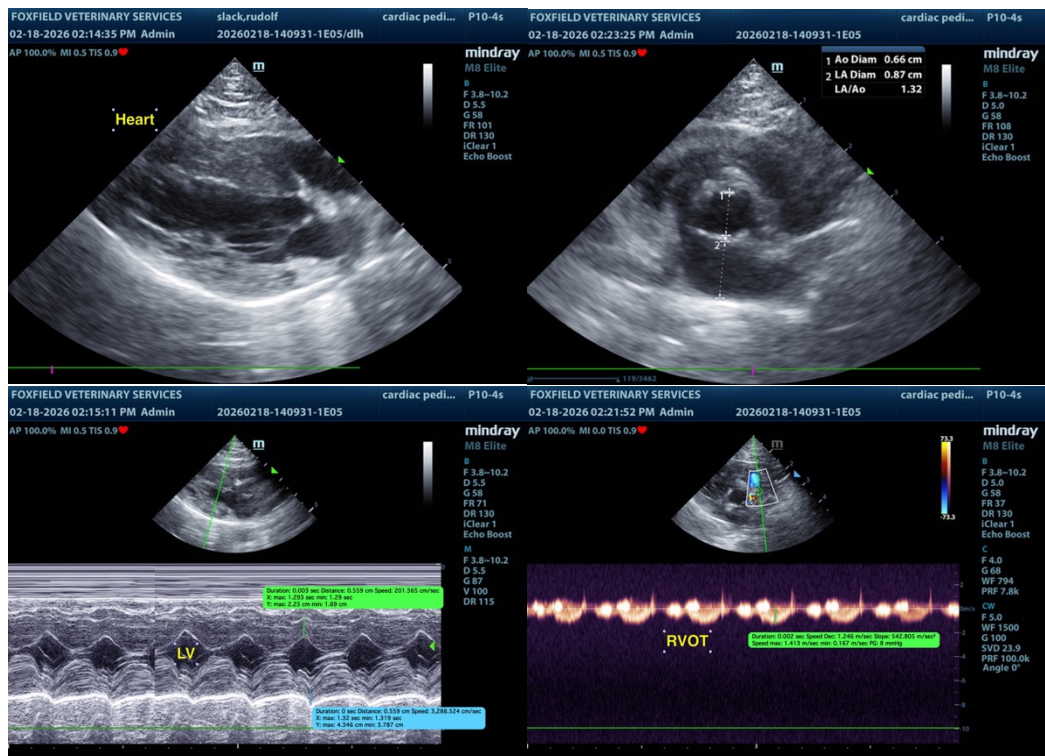
13219

## DATE

2/18/26

## INTERPRETATION OF THE FINDINGS & FURTHER RECOMMENDATIONS

No evidence of clinical issues such as left or right heart chamber enlargement, LV systolic dysfunction, HCM criteria or other structural cardiomyopathy. A definitive cause of the murmur was not identified. Assuming no volume changes such as dehydration or anemia, a benign flow murmur is probable. A small non-visualized flow abnormality is not excluded. Regardless of classification, the hemodynamic effects of the murmur are low. Monitoring of the heart murmur is recommended without indication for cardiac medications. Recheck echocardiogram is recommended in 6-12 months, sooner if murmur intensity increases or clinical signs arise. no anesthetic contraindications. Suggested anesthetic protocol may include opioid or Benzodiazepine pre-med, induction with Propofol or Alfaxalone, and appropriate gas anesthesia with avoidance of alpha 2 agonists.



The information and recommendations provided are based on the images presented by the referring veterinarian/sonographer. No evaluation can be communicated regarding pathology that was not visible in the image/video clips provided.

Thank you for this referral. If the clinical or image interpretation does not parallel your findings or if I can be of any further assistance, please contact me.

R. McKenzie Daniel, DVM, DABVP (Canine / Feline Practice)

[info@sonopath.com](mailto:info@sonopath.com)



## PATIENT

Rudolf Slack

## SPECIES

Feline

## BREED

DLH

## SEX

Male Neutered

## AGE

8y

## WEIGHT

12.8 lbs

## INTERPRETED BY

R. McKenzie Daniel,  
DVM, DABVP  
(Canine and Feline)

## IMAGING PERFORMED BY

Rodriguez

## HOSPITAL NAME

Foxfield VS

## REFERRING VET

Rodriguez

## INVOICE

13219

## DATE

2/18/26