



PATIENT PRESENTING CLINICAL SIGNS

Salem Lesoine History:

SPECIES

Feline

BREED

DSH

SEX

Male Neutered

AGE

7y 6m

WEIGHT

20 lbs

- Hematuria
- Hx of urinary obstruction w/PU sx 2/2025
- Possible urachal remnant on rads
- Persistant urinary bladder calculi.
- Current Meds: Receiving RCVD SO + Chia seed, Welactin (Gabapentin)

Abnormal PE/Chem/CBC/UA Results: Hypercalcemia 11.7 (H 10.8); Ionized Ca 1.47 (H 1.34); Lynphs 1102 (L 1200) UA: Struvites 0-1; CaOx 4-10; Ca monohydrate 0-4; PH 6; trace protein. USG 1.047

ULTRASONOGRAPHIC EXAMINATION OF THE ABDOMEN

Urinary System

The urinary bladder was normal in size and tone. Mildly thickened primarily ventral apical to dorsal apical urinary bladder wall with mild asymmetrical luminal surface contour. Dependent lumen to ventral apically lumen surface adhered mineral along with mild, non-dependent particulate sediment and mineral. No evidence of apical wall pathology such as urachal remnant or evidence of trigone/cystourethral junction pathology. The visible proximal urethra to a depth of 3.0 cm exhibited normal structure and tone.

The kidneys exhibited adequate size with primarily symmetrical margination. Mild cortex and increased cortex echogenicity with mild indistinct corticomedullary border demarcation. Areas of bilateral medullary mineral was present with nonspecific right kidney medullary rim. The kidney measured 3.9 cm in length. The left kidney measured 4.2 cm in length.

Adrenal Glands

The left adrenal gland was uniform in size and contour with a uniformly hypoechoic parenchyma. The left adrenal gland measured 0.5 cm. The right adrenal gland was uniform in size and contour with a uniformly hypoechoic parenchyma. The right adrenal gland measured 0.4 cm.

Spleen

The spleen exhibited a finely textured and homogenous parenchyma which was hyperechoic to the liver and renal cortical parenchyma. The capsule was smooth and regular without apparent expansion. The splenic vasculature at the hilus was normal in volume with no evidence of congestion or thrombosis. Acute to chronic inflammatory, neoplastic, or benign parenchyma changes were not noted.

Liver

The liver was subjectively normal in size, structure, and contour. The liver parenchyma was uniform and hypoechoic to the spleen with a mild coarse echotexture. The hepatic and portal vasculature were normal in appearance without signs of congestion. The gallbladder was non-distended in size with thin walls and primarily anechoic luminal content. The cystic and common bile ducts were normal.

INTERPRETED BY

R. McKenzie Daniel, DVM, DABVP (Canine and Feline)

IMAGING PERFORMED BY

Shari Reffi, CVT

HOSPITAL NAME

VCA AVH AH

REFERRING VET

Dr. Case

INVOICE

13208

DATE

2/17/26



PATIENT

Salem Lesoine

SPECIES

Feline

BREED

DSH

SEX

Male Neutered

AGE

7y 6m

WEIGHT

20 lbs

INTERPRETED BY

R. McKenzie Daniel,
 DVM, DABVP
 (Canine and Feline)

IMAGING PERFORMED BY

Shari Reffi, CVT

HOSPITAL NAME

VCA AVH AH

REFERRING VET

Dr. Case

INVOICE

13208

DATE

2/17/26

Gastrointestinal

The stomach presented intact wall layering with a normal wall layer ratio. The lumen of the stomach was empty with no signs of ileus, obstruction or foreign material.

The small intestine presented intact wall layering with 1:3 muscularis/mucosa ratio. The lumen of the small intestine was empty with no signs of ileus, obstruction or foreign material.

Normal visible colon wall layers were present with apparent formed feces in lumen.

Pancreas

The parenchyma of the left limb, body and right limb of the pancreas presented isoechoic to the adjacent omental fat. A normal curvilinear capsule contour of the pancreas was present. The visible pancreatic duct was normal. No signs of active inflammation or neoplastic disease was evident.

Free Abdomen

Intermittent, mild colic lymph nodes were present. These lymph nodes were homogenous, mildly hypoechoic and smoothly marginated. A normal width: length ratio was maintained (<0.5). Mild perilymphatic to peri ileocolic hyperechoic omentum. No evidence of peritoneal effusion present.

PRIMARY FINDINGS

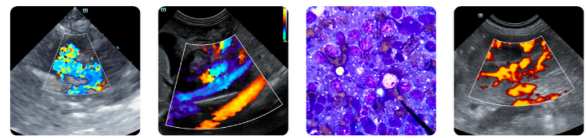
- Mild cystitis with dependent lumen to ventral apically adhered mineral and non-dependent particulate urine sediment
- Nonspecific mild hyperechoic corticomedullary echogenicity, mild medullary mineral and right kidney medullary rim

SECONDARY FINDINGS

- Mild colic lymphadenopathy – consistent with benign criteria, i.e. mild incidental hyperplasia probable

INTERPRETATION OF THE FINDINGS & FURTHER RECOMMENDATIONS

No overt evidence of urinary bladder congenital abnormality, i.e. urachal remnant. Urine C/S on sterile urine sample suggested to assess for or rule out infection if not recently done. Assuming no infection, continued empirical therapy for cystitis including urinary diet would be reasonable. Renal parenchymal changes and mild mineralization potentially secondary to nonspecific hypercalcemia possible. Further workup for hypercalcemia may be considered. No overt evidence of intraabdominal neoplastic criteria.



PATIENT

Salem Lesoine

SPECIES

Feline

BREED

DSH

SEX

Male Neutered

AGE

7y 6m

WEIGHT

20 lbs

INTERPRETED BY

R. McKenzie Daniel,
 DVM, DABVP
 (Canine and Feline)

IMAGING PERFORMED BY

Shari Reffi, CVT

HOSPITAL NAME

VCA AVH AH

REFERRING VET

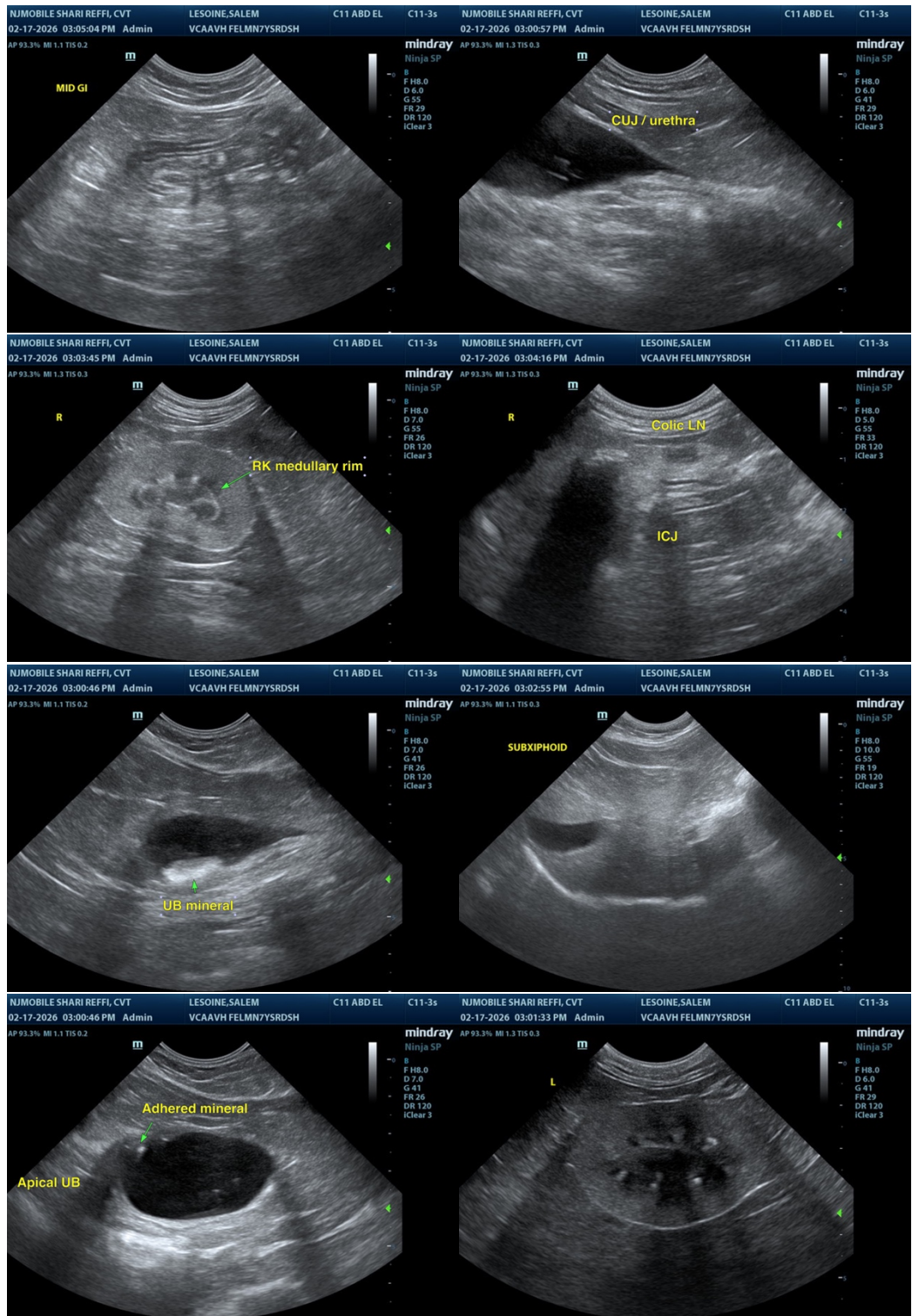
Dr. Case

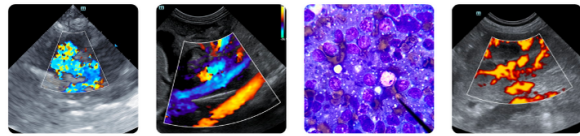
INVOICE

13208

DATE

2/17/26





PATIENT

Salem Lesoine

SPECIES

Feline

BREED

DSH

SEX

Male Neutered

AGE

7y 6m

WEIGHT

20 lbs

INTERPRETED BY

R. McKenzie Daniel,
DVM, DABVP
(Canine and Feline)

IMAGING PERFORMED BY

Shari Reffi, CVT

HOSPITAL NAME

VCA AVH AH

REFERRING VET

Dr. Case

INVOICE

13208

DATE

2/17/26

The information and recommendations provided are based on the images presented by the referring veterinarian/sonographer. No evaluation can be communicated regarding pathology that was not visible in the image/video clips provided.

Thank you for this referral. If the clinical or image interpretation does not parallel your findings or if I can be of any further assistance, please contact me.

R. McKenzie Daniel, DVM, DABVP (Canine / Feline Practice)

info@sonopath.com