



PATIENT

Mischa Rork

SPECIES

Canine

BREED

Rottweiler

SEX

Neutered Male

AGE

4 Years

WEIGHT

44.5 kg

INTERPRETED BY

R. McKenzie Daniel,
DVM, DABVP (Canine
/ Feline Practice)

IMAGING PERFORMED BY

Natalia Franco

HOSPITAL NAME

Eagleson Veterinary
Clinic

REFERRING VET

Dr. Karissa Romans

INVOICE

13857

DATE

02/17/26

PRESENTING CLINICAL SIGNS

- Presented for a recheck of persistent gastrointestinal signs. He was seen 4 days prior for a 2-day history of diarrhea and one episode of vomiting. His signs have since worsened, with increased frequency of diarrhea (requiring him to go out every 30 minutes at night), inappetence, and lethargy. He returned later the same day after showing no interest in food and developing pacing, drooling, and blood in his stool. Hasn't eaten for almost 24 hours.
- Current medications: Sucralfate, Fenbendazole, Provable
- GI panel and Fecal profile pending

Abnormal PE/Chem/CBC/UA Results: Vitals WNL, tense on abdominal palpation, hypersalivation, burping. BW and UA performed a week ago WNL.

ULTRASONOGRAPHIC EXAMINATION OF THE ABDOMEN

Urinary System

The urinary bladder, trigone, cystourethral junction, and visible pelvic urethra exhibited normal thickness and tone. Anechoic urine was present in the lumen with no uroliths or sediment. The ureteral papillae were normal. The ureters were not visible which is normal. No evidence of inflammatory or neoplastic change were noted.

Normal size and margination was present in the kidneys. A normal 1:3 cortex / medulla ratio and normal corticomedullary definition were maintained. The echogenicity of the cortex was similar to or slightly less than normal liver parenchyma while the medulla echogenicity was hypoechoic to the cortex with no evidence of pelvic dilation. The left kidney measured 7.4 cm in length. The right kidney measured 8.2 cm in length.

Adrenal Glands

The bilateral adrenal glands were borderline subnormal in size given the patient's breed and body weight with symmetrical contour and homogenous parenchyma. The left adrenal gland measured 0.44 cm width at the caudal pole. The right adrenal gland measured 0.44 cm width at the caudal pole.

Spleen

The spleen exhibited a finely textured and homogenous parenchyma which was hyperechoic to the liver and renal cortical parenchyma. The capsule was smooth and regular without apparent expansion. The splenic vasculature at the hilus was normal in volume with no evidence of congestion or thrombosis. Acute to chronic inflammatory, neoplastic, or benign parenchyma changes were not noted.

Liver & Gallbladder

The liver was subjectively normal in size, structure, and contour. The liver parenchyma was uniform and hypoechoic to the spleen with a mild coarse echotexture. The hepatic and portal vasculature were normal in appearance without signs of congestion.

The gallbladder was non-distended in size with thin walls and primarily anechoic luminal content. The cystic and common bile ducts were normal.

Gastrointestinal



PATIENT

Mischa Rork

SPECIES

Canine

BREED

Rottweiler

SEX

Neutered Male

AGE

4 Years

WEIGHT

44.5 kg

INTERPRETED BY

R. McKenzie Daniel,
DVM, DABVP (Canine
/ Feline Practice)

IMAGING PERFORMED BY

Natalia Franco

HOSPITAL NAME

Eagleson Veterinary
Clinic

REFERRING VET

Dr. Karissa Romans

INVOICE

13857

DATE

02/17/26

The stomach presented intact wall layering with a normal wall layer ratio. The lumen of the stomach contained mild to moderate hyperechoic ingesta exhibiting mild dirty distal acoustic shadowing along with mild retained nonshadowing ingesta and mildly echogenic fluid/lumen gas. No overt obstruction to pyloric outflow.

The small intestine presented intact wall layering with 1:3 muscularis/mucosa ratio. The lumen of the small intestine was empty to the level of the colon. Borderline prominent intestinal wall width. The duodenum wall measured 0.60 cm wall width. The jejunum wall measured 0.50 cm wall width.

The visualized colon exhibited overtly normal intact wall. The colon was nondistended containing soft to nonformed fecal matter and lumen gas.

Pancreas

The parenchyma of the left limb, body and right limb of the pancreas presented isoechoic to the adjacent omental fat. A normal curvilinear capsule contour of the pancreas was present. The visible pancreatic duct was normal. No signs of active inflammation or neoplastic disease was evident.

Free Abdomen

Intermittent mesenteric nodes were present. The lymph nodes were essentially isoechoic to adjacent omentum without evidence of peripheral inflammation and maintaining a normal width: length ratio (<0.5). No evidence of peritoneal effusion.

ULTRASONOGRAPHIC FINDINGS

- Hypomotile stomach with retained nonspecific ingesta and fluid.
- Nonspecific enterocolonopathy exhibiting borderline thickened empty small intestine and soft to nonformed fecal matter in colon.
- Normal area of the pancreas.
- Subjective borderline subnormal bilateral adrenal glands.

INTERPRETATION OF THE FINDINGS & FURTHER RECOMMENDATIONS

The stomach may indicate metabolic or functional gastric ileus with retained ingesta and fluid. Non-obstructive partial fluid absorbing gastric material i.e. fabric stuffing or similar are not definitively excluded. No evidence of small intestinal obstructive pattern or visualized foreign material.

Considerations for the GI tract and colon include dietary intolerance / food hypersensitivity, infectious disease, dysbiosis, enterotoxin, inflammatory bowel disease, mild pancreatitis, occult parasitism, occult Addison's Disease, occult neoplasia, or other. Monitoring for gastric emptying versus persistent retained gastric ingesta fluid with upper gastrointestinal endoscopy if available is likely ideal for further assessment of the gastric interior and potential for biopsies.

Empirically, a limited antigen or hydrolyzed diet trial with potential long term dietary therapy, prophylactic deworming (Panacur 50 mg/kg SID x 5 consecutive days with repeat protocol in 3 weeks even if fecal testing is negative), high colony count probiotic (Provable or Visbiome), and as needed gastroprotectants is suggested with clinical monitoring. Note that recent research has shown that indiscriminate use of antibiotics may actually cause harm.



PATIENT

Mischa Rork

SPECIES

Canine

BREED

Rottweiler

SEX

Neutered Male

AGE

4 Years

WEIGHT

44.5 kg

INTERPRETED BY

R. McKenzie Daniel,
DVM, DABVP (Canine
/ Feline Practice)

IMAGING PERFORMED BY

Natalia Franco

HOSPITAL NAME

Eagleson Veterinary
Clinic

REFERRING VET

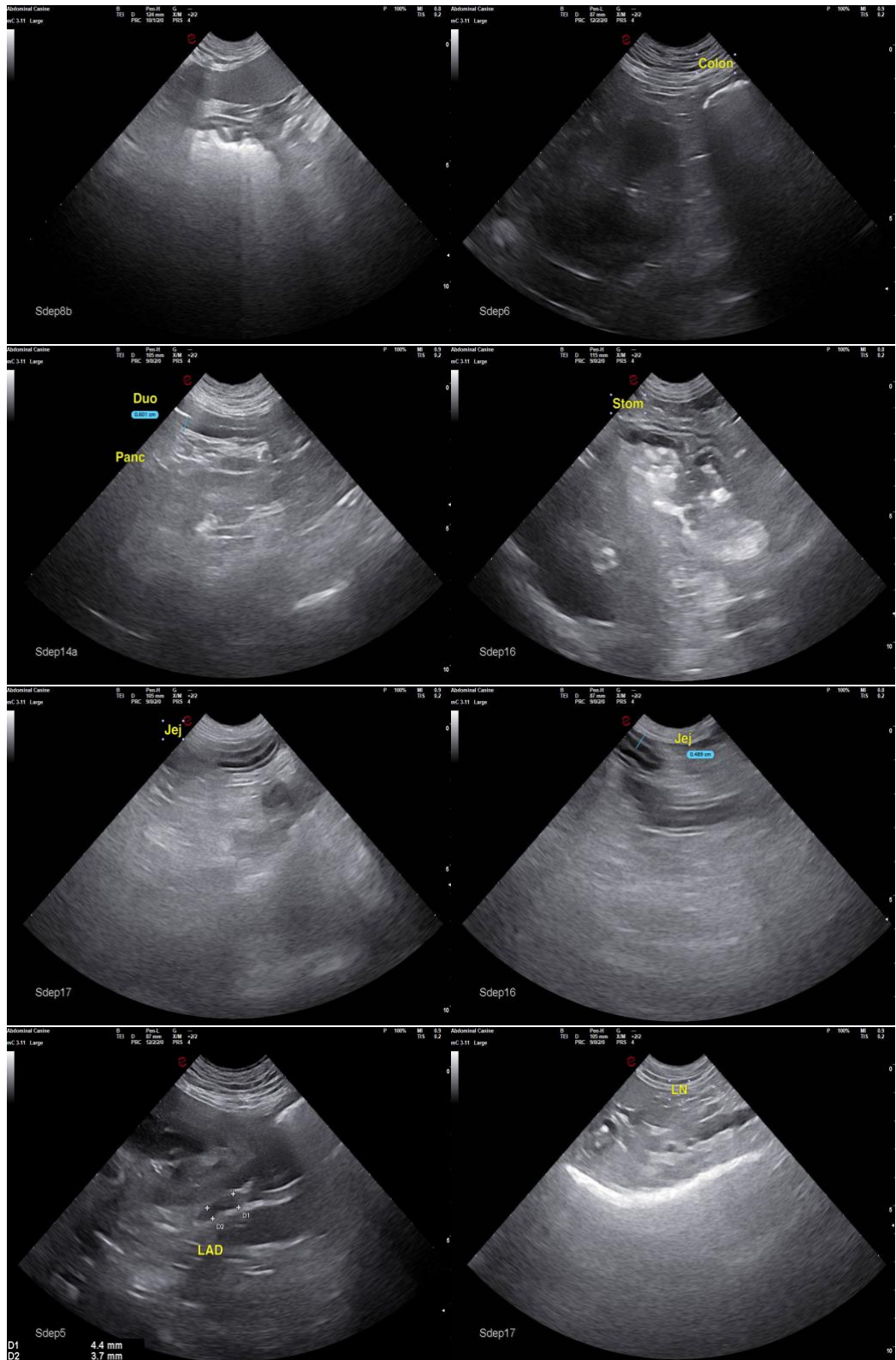
Dr. Karissa Romans

INVOICE

13857

DATE

02/17/26





PATIENT

Mischa Rork

SPECIES

Canine

BREED

Rottweiler

SEX

Neutered Male

AGE

4 Years

WEIGHT

44.5 kg

INTERPRETED BY

R. McKenzie Daniel,
DVM, DABVP (Canine
/ Feline Practice)

IMAGING PERFORMED BY

Natalia Franco

HOSPITAL NAME

Eagleson Veterinary
Clinic

REFERRING VET

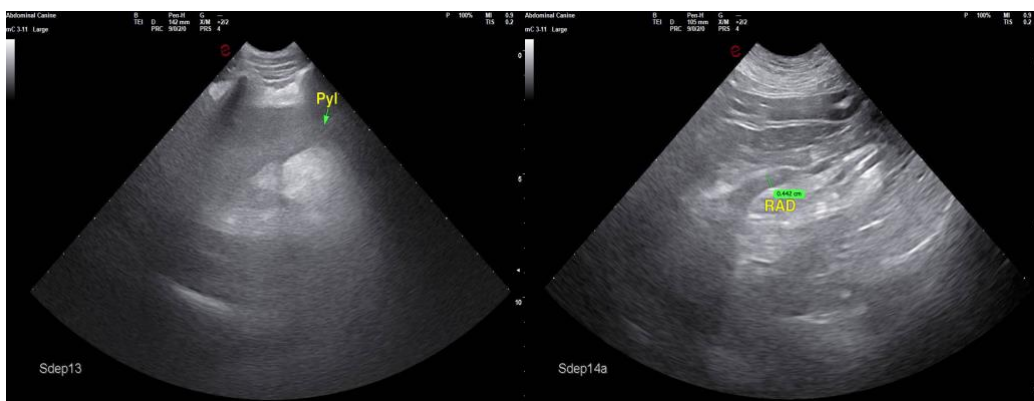
Dr. Karissa Romans

INVOICE

13857

DATE

02/17/26



The information and recommendations provided are based on the images presented by the referring veterinarian/sonographer. No evaluation can be communicated regarding pathology that was not visible in the image/video clips provided.

Thank you for this referral. If the clinical or image interpretation does not parallel your findings or if I can be of any further assistance, please contact me.

R. McKenzie Daniel, DVM, DABVP (Canine / Feline Practice)

info@SonoPath.com