



<b>PATIENT</b>	<b>PRESENTING CLINICAL SIGNS</b>
Rufus Massie	History of elevated liver values
<b>SPECIES</b>	<b>ULTRASONOGRAPHIC EXAMINATION OF THE ABDOMEN</b>
Canine	<b>Urinary System</b>
<b>BREED</b>	The urinary bladder, trigone, cystourethral junction, and visible pelvic urethra exhibited normal thickness and tone. Anechoic urine was present in the lumen with no uroliths or sediment. The ureteral papillae were normal. The ureters were not visible which is normal. No evidence of inflammatory or neoplastic changes were noted.
Poodle	Normal size and margination were present in the kidneys. A normal 1:3 cortex / medulla ratio was maintained. The medulla and cortices were uniform in texture with some increased echogenicity and mild loss of corticomedullary symmetry and definition expected for the age of the patient. No evidence of pelvic dilation was present. A caudal left kidney thinly walled cyst containing anechoic fluid was present measuring ~ 4.0 cm in diameter. The left kidney measured 7.1 cm in length. The right kidney measured 6.4 cm in length.
<b>SEX</b>	The area of the aortic trifurcation was free of pathology.
MN	The area of the residual prostate appeared normal and free of pathology.
<b>AGE</b>	<b>Adrenal Glands</b>
13yr	The left adrenal gland was uniform in size and contour with a uniformly hypoechoic parenchyma. The left adrenal gland measured 0.58 cm width at the caudal pole. The right adrenal gland was uniform in size and contour with a uniformly hypoechoic parenchyma. The right adrenal gland measured 0.62 cm width at the caudal pole.
<b>WEIGHT</b>	<b>Spleen</b>
60	The spleen exhibited a finely textured and homogenous parenchyma which was hyperechoic to the liver and renal cortical parenchyma. The capsule was smooth and regular without apparent expansion. The splenic vasculature at the hilus was normal in volume with no evidence of congestion or thrombosis. Acute to chronic inflammatory, neoplastic, or benign parenchyma changes were not noted.
<b>INTERPRETED BY</b>	<b>Liver/Gallbladder</b>
R. McKenzie Daniel, DVM, DABVP (Canine and Feline)	The liver presented mildly enlarged in size. The parenchyma of the liver was subjectively normal in echogenicity compared to the spleen and renal cortices. The liver parenchyma was uniform with a mildly coarse echotexture. The capsule of the liver was symmetrically rounded to mildly swollen in margination. The hepatic and portal vasculature were normal in appearance without signs of congestion. The gallbladder was non-distended in size with primarily anechoic luminal content. The cystic and common bile ducts were normal.
<b>IMAGING PERFORMED BY</b>	<b>Gastrointestinal</b>
Hope Brossman	The stomach presented intact wall layering with a normal wall layer ratio. The lumen of the stomach was empty with no signs of ileus, obstruction or foreign material.
<b>HOSPITAL NAME</b>	The small intestine presented intact wall layering with 1:3 muscularis/mucosa ratio. The lumen of the small intestine was empty with no signs of ileus, obstruction or foreign material.
Animal Mansion VH	Normal visible colon wall layers were present with apparent formed feces in lumen.
<b>REFERRING VET</b>	
Dr. Parker	
<b>INVOICE</b>	
12990ag	
<b>DATE</b>	
02/17/2023	



**PATIENT**

**Pancreas**

Rufus Massie

The parenchyma of the left limb, body and right limb of the pancreas presented isoechoic to the adjacent omental fat. A normal curvilinear capsule contour of the pancreas was present. The visible pancreatic duct was normal. No signs of active inflammation or neoplastic disease was evident.

**SPECIES**

Canine

**Free Abdomen**

No omental masses, overt lymphadenopathy or peritoneal effusion was present.

**BREED**

Poodle

**ULTRASONOGRAPHIC FINDINGS**

- Mild chronic renal changes with left kidney cyst
- Benign hepatopathy
- Sonographically normal gallbladder

**SEX**

MN

**INTERPRETATION OF THE FINDINGS & FURTHER RECOMMENDATIONS**

Overall, largely a geriatric abdomen with no overt evidence of significant abdominal visceral specifically hepatobiliary pathology. Assuming normal clotting status a hepatic FNA for screening cytology could be considered for further assessment. Hepatosupportive medications such as Denamarin and +/- Ursodiol due to its antioxidant and immunomodulatory effects within the liver would be warranted, although these medications may not result in decreased hepatic enzyme levels. Monitoring of liver enzymes going forward is suggested.

**AGE**

13yr

**WEIGHT**

60

**INTERPRETED BY**

R. McKenzie Daniel,  
DVM, DABVP  
(Canine and Feline)

**IMAGING PERFORMED BY**

Hope Brossman

**HOSPITAL NAME**

Animal Mansion VH

**REFERRING VET**

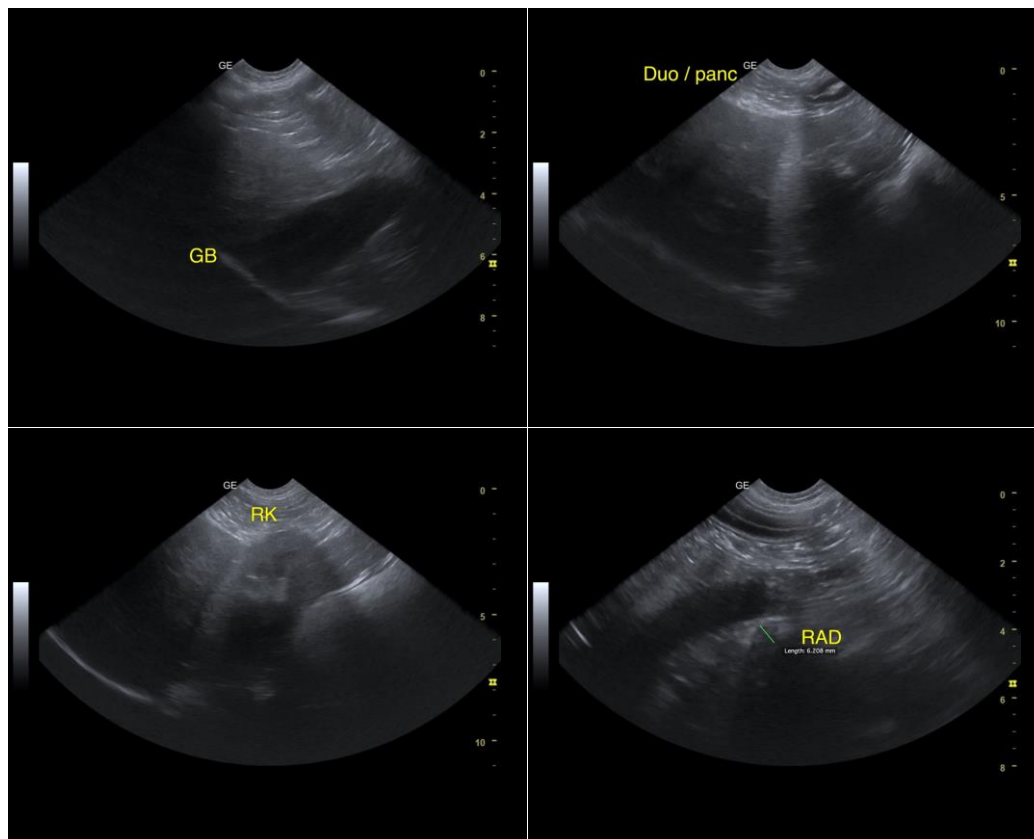
Dr. Parker

**INVOICE**

12990ag

**DATE**

02/17/2023





**PATIENT**

Rufus Massie

**SPECIES**

Canine

**BREED**

Poodle

**SEX**

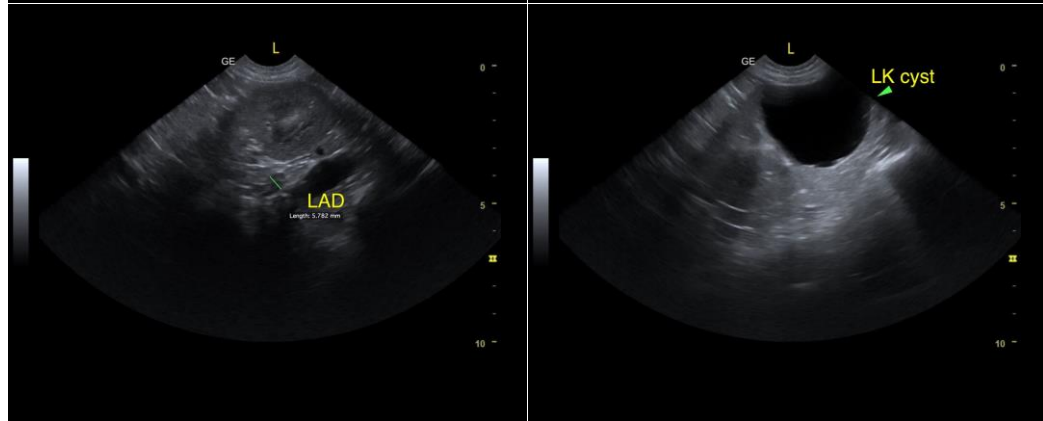
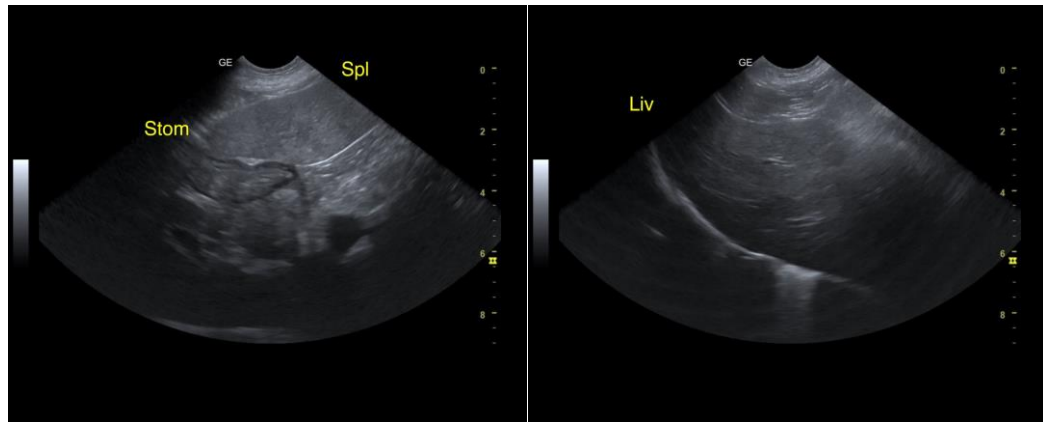
MN

**AGE**

13yr

**WEIGHT**

60



**INTERPRETED BY**

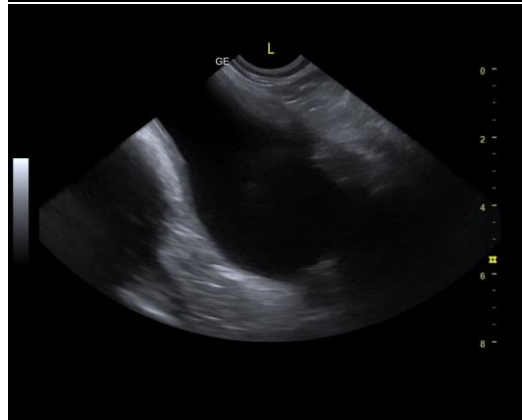
R. McKenzie Daniel,  
DVM, DABVP  
(Canine and Feline)

**IMAGING PERFORMED BY**

Hope Brossman

**HOSPITAL NAME**

Animal Mansion VH



**REFERRING VET**

Dr. Parker

**INVOICE**

12990ag

**DATE**

02/17/2023

The information and recommendations provided are based on the images presented by the referring veterinarian/sonographer. No evaluation can be communicated regarding pathology that was not visible in the image/video clips provided.

Thank you for this referral. If the clinical or image interpretation does not parallel your findings or if I can be of any further assistance, please contact me.

R. McKenzie Daniel, DVM, DABVP (Canine/Feline Practice)  
[mac.daniel@sonopath.com](mailto:mac.daniel@sonopath.com)



**PATIENT**

Rufus Massie

**SPECIES**

Canine

**BREED**

Poodle

**SEX**

MN

**AGE**

13yr

**WEIGHT**

60

**INTERPRETED BY**

R. McKenzie Daniel,  
DVM, DABVP  
(Canine and Feline)

**IMAGING  
PERFORMED BY**

Hope Brossman

**HOSPITAL NAME**

Animal Mansion VH

**REFERRING VET**

Dr. Parker

**INVOICE**

12990ag

**DATE**

02/17/2023